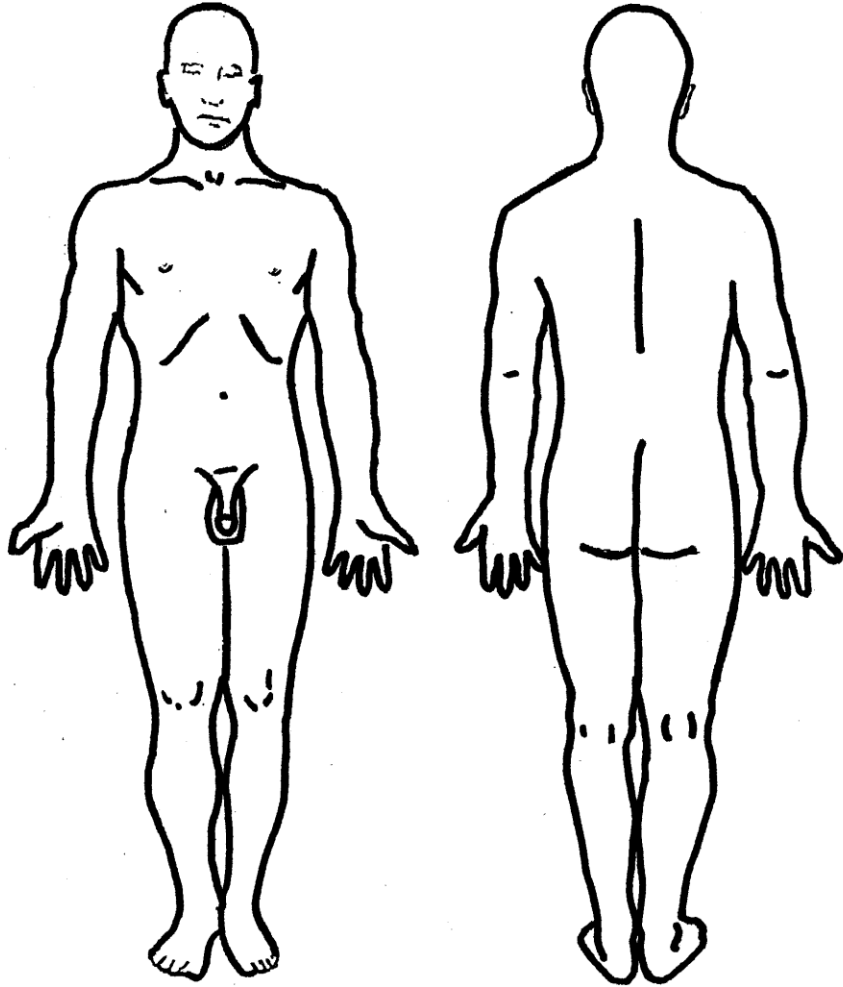


Full Body: Male-Anterior and Posterior Views (Ventral and Dorsal)



Name _____ Case No. _____

Date _____