c0007

CHAPTER 7

The hand

ANATOMY 173
- ***Bony landmarks to be palpated*** 173
- ***Ligaments*** 174
- ***Muscles*** 174
  - *Extensors* 174
  - *Flexors* 175
  - *Abductors, adductors and opposers* 175

MEASUREMENT 176
- ***Range of movement – CMC joint of the thumb*** 176
  - *Abduction* 176
  - *Flexion/extension* 177
- ***Range of movement – MCP joint of the thumb*** 178
  - *Flexion* 178
- ***Range of movement – IP joint of the thumb*** 179
  - *Flexion* 179
- ***Range of movement – MCP joint of the finger*** 180
  - *Flexion* 180
  - *Abduction* 181
- ***Range of movement – PIP joint of the finger*** 182
  - *Flexion/extension* 182
- ***Range of movement – DIP joint of the finger*** 183
  - *Flexion/extension* 183
  - *Observational/reflective checklist* 185

s0010

ANATOMY

p0010 o0010 1. The carpometacarpal (CMC) joint of the thumb is a synovial saddle joint.

o0020 2. It is an articulation between the trapezium and the base of the first metacarpal.

o0030 3. The two surfaces are reciprocally concavoconvex.

o0040 4. A loose but strong fibrous capsule encloses the joint.

o0050 5. Movements of flexion, extension, abduction, adduction and opposition occur at this joint.

s0020

BONY LANDMARKS TO BE PALPATED

p9000

The Carpus – Scaphord, Lunate, Triquetral, Pisiform, Trapezium, Trapezoid, Capitate, Hamate. The Metacarpals and Phalanges.

LIGAMENTS s0030

Table 7.1

t0010

Ligaments of the hand

Ligament	Origin	Insertion	Limitation to movement
Radial carpometacarpal ligament	Lateral surface of the trapezium	Lateral surface of the first metacarpal	
Anterior oblique ligament	Anterior surface of the trapezium	Medial side of the first metacarpal	Taut posterior oblique ligament
Posterior oblique ligament	Posterior surface of the trapezium	Medial side of the first metacarpal	Taut anterior oblique ligament

MUSCLES s0040

Extensors s0050

Table 7.2

t0020

The extensors of the thumb

Muscle	Origin	Insertion	Nerve supply	Action(s)
Extensor pollicis longus	Middle third of posterior surface of ulna and interosseous membrane	Dorsal surface of the distal phalanx of thumb	Posterior interosseous branch of the radial nerve C7, 8	Extension and radial deviation of the wrist. Extension of all the thumb joints
Extensor pollicis brevis	Middle part of the posterior surface of the radius and interosseous membrane	Dorsal surface of the base of the proximal phalanx	Posterior interosseous branch of the radial nerve C7, 8	Extension and radial deviation of the wrist. Extension of the carpometacarpal and metacarpophalangeal (MCP) joints of the thumb

Flexors

s0060

Table 7.3

t0030

The flexors of the thumb				
Muscle	Origin	Insertion	Nerve supply	Action(s)
Flexor pollicis longus	Upper anterior surface of radius and interosseous membrane	Palmar surface of distal phalanx of the thumb	Anterior interosseous branch of median nerve C8, T1	Flexion of the wrist joint. Flexion of the interphalangeal and metacarpophalangeal joints of the thumb. Vital in all gripping activities
Flexor pollicis brevis	Flexor retinaculum, tubercle of the trapezium, capitate and trapezoid	Radial side of the base of the proximal phalanx of the thumb	Median nerve T1	Flexion of the carpometacarpal and metacarpophalangeal joints of the thumb. It also produces medial rotation of the thumb

Abductors, adductors and opposers

s0070

Table 7.4

t0040

The abductors, adductors				
Muscle	Origin	Insertion	Nerve supply	Action(s)
Abductor pollicis longus	Upper, posterior surface of ulna, middle third of the posterior surface of the radius and the interosseous membrane	Radial side of the base of the first metacarpal	Posterior interosseous branch of the radial nerve C7, 8	Working with abductor pollicis brevis it abducts the thumb. Working with the extensors it extends the thumb at the CMC joint. Working by itself it moves the thumb into a mid-extended and abducted position
Abductor pollicis brevis	Flexor retinaculum, and tubercles of scaphoid and trapezium	Radial side of proximal phalanx of the thumb	Median nerve T1	Abduction of the thumb at the CMC and MCP joints

(*table continues*)

Table 7.4 (Continued)

Muscle	Origin	Insertion	Nerve supply	Action(s)
Opponens pollicis	Flexor retinaculum and tubercle of the trapezium	Lateral half of the anterior surface of the first metacarpal	Median nerve T1	Opposition of the thumb – abduction, medial rotation, and flexion and adduction of the CMC joint. This allows precise hand actions to take place
Palmaris brevis	Palmar aponeurosis and flexor retinaculum	The skin of the medial border of the hand	Ulnar nerve T1	This muscle wrinkles the skin on the ulnar side of the hand and assists the thumb in producing a good grip

MEASUREMENT s0080

RANGE OF MOVEMENT – CARPOMETACARPAL (CMC) JOINT OF THE THUMB s0090

s0100 ***Abduction***



f0010 **Fig 7.1** Goniometric measurement of the carpometacarpal joint of the thumb – abduction.

s0110 p0110 *Starting position:* The patient is positioned in sitting, their arm supported on a table. Their elbow is flexed, their forearm is in the

mid-position, their wrist is in the anatomical position and the thumb maintains contact with the metacarpal of the index finger.

s0120 p0120 *Goniometer axis:* The axis of the goniometer is placed at the junction of the bases of the first and second metacarpal. (A small goniometer is required.)

s0130 p0130 *Stationary arm:* This is parallel to the longitudinal axis of the second metacarpal.

s0140 p0140 *Moveable arm:* This is parallel to the longitudinal axis of the first metacarpal. In the start position this will indicate 15–20°. Record as 0°.

s0150 p0150 *End position:* The thumb is abducted to the limit of motion (70°).

s0160

Flexion/extension

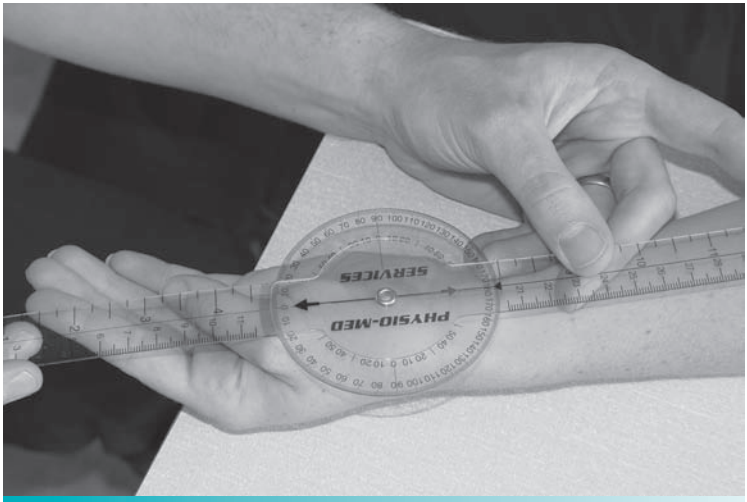

f0020 **Fig 7.2** Goniometric measurement of the carpometacarpal joint of the thumb – flexion and extension.

s0170 p0160 *Starting position:* The patient is positioned in sitting, their arm supported on a table. Their elbow is flexed, their forearm is in supination and their wrist is in neutral.

s0180 p0170 *Goniometer axis:* The axis of the goniometer is placed over the CMC joint of the thumb. (A small goniometer is required.)

s0190 *Stationary arm:* This is parallel to the longitudinal axis of the radius.

p0180 s0200 p0190 *Moveable arm:* This is parallel to the longitudinal axis of the thumb metacarpal.

s0210 p0200 p0210 *End position:* Flexion – the thumb if flexed across palm (15°). Extension – the thumb is extended away from the palm (20°).

s0230 ## RANGE OF MOVEMENT – METACARPOPHALANGEAL (MCP) JOINT OF THE THUMB

s0240 ### Flexion

f0030 **Fig 7.3** Goniometric measurement of finger metacarpophalangeal (MCP) flexion.

s0250 p0220 *Starting position:* The patient is positioned in sitting, their arm supported on a table. Their elbow is flexed, their forearm is in the mid-position and their wrist is slightly extended. The MCP joint being measured is in 0° of extension.

p0230 s0260 *Stabilization:* The clinician stabilizes the metacarpal.

s0270 p0240 *Goniometer axis:* The axis of the goniometer is placed over the dorsal aspect of the joint being measured. (A small goniometer is required.)

s0280 p0250 *Stationary arm:* This is parallel to the longitudinal axis of the shaft of the metacarpal.

s0290 p0260 *Moveable arm:* This is parallel to the longitudinal axis of the proximal phalanx.

s0300 p0270 *End position:* The MCP joint is flexed to the limit of motion.

b0010 p0280 ***Clinical tip***

During the movement the interphalangeal (IP) joint is allowed to flex.

s0320 s0330

RANGE OF MOVEMENT – INTERPHALANGEAL (IP) JOINT OF THE THUMB

Flexion

f0040 **Fig 7.4** Goniometric measurement of thumb interphalangeal (IP) flexion.

s0340 p0290 *Starting position:* The patient is positioned in sitting, their arm supported on a table. Their elbow is flexed, their forearm is in the mid-position and their wrist is slightly extended. The IP joint being measured is in 0° of extension.

s0350 p0300 *Stabilization:* The clinician stabilizes the metacarpal.

s0360 p0310 *Goniometer axis:* The axis of the goniometer is placed over the dorsal aspect of the joint being measured.

s0370 p0320 *Stationary arm:* This is parallel to the longitudinal axis of the shaft of the proximal phalanx.

s0380 p0330 *Moveable arm:* This is parallel to the longitudinal axis of the distal phalanx.

s0390 p0340 *End position:* The thumb is flexed to the limit of motion.

s0410 ## RANGE OF MOVEMENT – METACARPOPHALANGEAL (MCP) JOINT OF THE FINGER

s0420 ### Flexion

f0050 **Fig 7.5** Goniometric measurement of finger metacarpophalangeal (MCP) flexion.

s0430 p0350 *Starting position:* The patient is positioned in sitting, their arm supported on a table. Their elbow is flexed, their forearm is in pronation and their wrist is extended. The MCP joint being measured is in 0° of extension.

s0440 p0360 *Stabilization:* The clinician stabilizes the metacarpal.

s0450 p0370 *Goniometer axis:* The axis of the goniometer is placed over the dorsal aspect of the joint being measured.

s0460 p0380 *Stationary arm:* This is parallel to the longitudinal axis of the shaft of the metacarpal.

s0470 p0390 *Moveable arm:* This is parallel to the longitudinal axis of the proximal phalanx.

s0480 p0400 *End position:* The MCP joint is flexed to the limit of motion.

b0020 p0410 ***Clinical tip***

During the movement the proximal interphalangeal (PIP) joint is allowed to flex and the distal interphalangeal (DIP) joint remains in extension.

s9000

RANGE OF MOVEMENT – METACARPOPHALANGEAL (MCP) JOINT OF THE FINGER

s0490

Abduction

f0060

Fig 7.6 Goniometric measurement of finger metacarpophalangeal (MCP) abduction.

s0500 p0420 *Starting position:* The patient is positioned in sitting, their arm supported on a table. Their elbow is flexed, their forearm is in pronation and their wrist is in neutral.

s0510 p0430 *Stabilization:* The clinician stabilizes the metacarpals.

s0520 p0440 *Goniometer axis:* The axis of the goniometer is placed over the dorsal surface of the MCP joint being measured.

s0530 p0450 *Stationary arm:* This is parallel to the long axis of the shaft of the metacarpal.

s0540 p0460 *Moveable arm:* This is parallel to the long axis of the proximal phalanx.

s0550 p0470 *End position:* The finger is moved away from the mid-line.

s0560 p0480 *Alternate method:* The patient spreads his/her hand out on a page. The clinician draws round the hand. After the patient removes their hand, the clinician records the linear measurement between the mid-point of each finger.

s0580 ## *RANGE OF MOVEMENT – PROXIMAL INTERPHALANGEAL (PIP) JOINT OF THE FINGER*

s0590 ### *Flexion/extension*

f0070 **Fig 7.7** Goniometric measurement of proximal interphalangeal (PIP) flexion and extension.

s0600 p0490 *Starting position:* The patient is positioned in sitting, their arm supported on a table. Their elbow is flexed, their forearm is in pronation and their wrist and fingers are in extension (0° of extension at the MCP and IP joints).

s0610 p0500 *Stabilization:* The clinician stabilizes the phalanx, proximal to the joint being measured.

s0620 p0510 *Goniometer axis:* The axis of the goniometer is placed over the dorsal surface of the PIP joint being measured.

s0630 p0520 *Stationary arm:* This is parallel to the longitudinal axis of the proximal phalanx.

s0640 p0530 *Moveable arm:* This is parallel to the longitudinal axis of the middle phalanx.

s0650 p0540 *End position:* The PIP joint is flexed to the limit of motion.

s0670 ## RANGE OF MOVEMENT – DISTAL INTERPHALANGEAL (DIP) JOINT OF THE FINGER

s0680 ### Flexion/extension

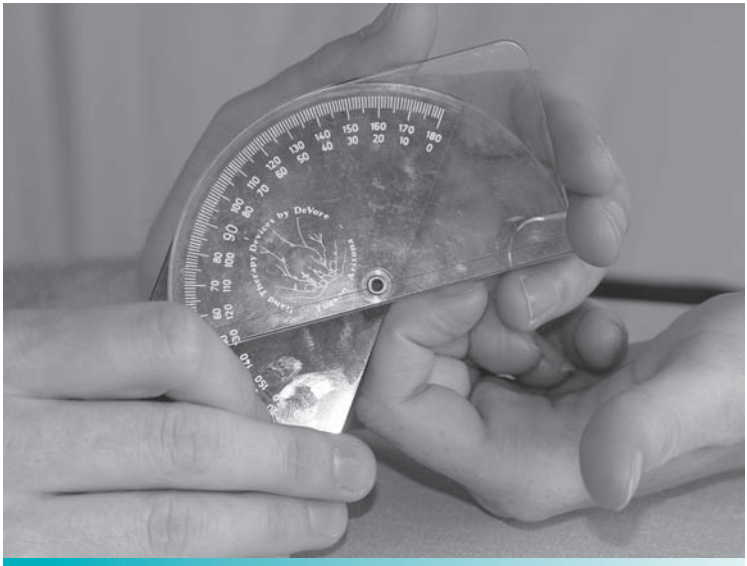

f0080 **Fig 7.8** Goniometric measurement of distal interphalangeal (DIP) flexion and extension.

s0690 p0550 *Starting position:* The patient is positioned in sitting, their arm supported on a table. Their elbow is flexed, their forearm is in supination and their wrist and fingers are in extension (0° of extension at the MCP and IP joints).

s0700 p0560 *Stabilization:* The clinician stabilizes the phalanx, proximal to the joint being measured.

s0710 p0570 *Goniometer axis:* The axis of the goniometer is placed over the dorsal surface of the DIP joint being measured.

s0720 p0580 *Stationary arm:* This is parallel to the longitudinal axis of the middle phalanx.

s0730 p0590 *Moveable arm:* This is parallel to the longitudinal axis of the distal phalanx.

s0740 p0600 *End position:* The DIP joint is flexed to the limit of motion.

p0610

Notes

p0620

Treatment record

s0750

Observational/reflective checklist

Observational/reflective checklist			
Observation		**Y/N**	**Comments**
Introduction and preparation for the skill	Was the treatment area properly prepared for the patient, e.g. pillow, blanket, safe environment, etc.?		
	Did the therapist introduce him/herself?		
	Was the patient comfortable?		
	Was the patient adequately exposed/draped?		
	Was an explanation of the procedure given?		
	Was the explanation clear and succinct?		
	Was consent obtained?		
Performing the skill	Was the plinth set at the correct height?		
	Was the therapist's posture compromised?		
	Did the therapist identify the joint and other relevant bony landmarks?		
	Was the goniometer correctly aligned?		
	Was the reading of the joint range of movement accurate?		
	Did the therapist compare both sides of the body?		
Safe and effective performance of the technique	Was the procedure carried out with due care and attention?		
How would you rate the proficiency in the overall performance of the skill?	Excellent		
	Very good		
	Good		
	Satisfactory		
	Borderline		
	Fail		