Chapter 2

Common presentations and diagnostic techniques

CHAPTER CONTENTS

DOI: 10.1016/B978-0-443-06929-1.00002-8

An understanding of the 'malalignment syndrome' requires a knowledge of the common presentations of malalignment and the techniques used to diagnose and treat these. Key to this is an understanding of the sacroiliac (SI) joint and the role it plays in the normal and abnormal functioning of the unit formed by the lumbosacral spine, pelvic ring and hip joints (henceforth referred to as the 'lumbo-pelvic-hip complex'). Interestingly, in the early 20th century, the SI joint was thought to be the main source of low back pain and was the focus of many scientific investigations. The publication, in 1934, of a paper by Mixter and Barr on rupture of the intervertebral disc quickly changed the direction of these investigations; over the next four decades, the SI joint was more or less ignored in favour of the disc as a primary cause of back pain.

The resurgence of interest in the SI joint since the 1970s can be attributed in large part to the following:

1. a failure of disc resection and subsequent desperation measures, such as disc-to-disc or lumbo-pelvic fusions, to relieve the persisting low back pain
2. the recognition of the short-and long-term complications of chymopapaine 'discectomy'
3. the evolution of the computed tomography (CAT) scan and, subsequently, magnetic resonance imaging (MRI), with gradual recognition of the fact that disc protrusions were common but did not necessarily cause back pain.

A CAT scan study of fetuses in utero by Magora & Schwarz (1976) was the first to report the coincidental finding that disc degeneration was evident in about 25% and disc protrusion in 1-2% of the pregnant women. The findings were confirmed by further CAT scan and eventually MRI studies, such as the one by Boos et al. (1995) who, in a study of asymptomatic subjects, found that as many as 75% had evidence of disc degeneration and some an actual disc protrusion.

From the late 1930s into the 1990s, research focused largely on SI joint anatomy and biomechanics (Bernard & Kirkaldy-Willis 1987; Bowen & Cassidy 1981; DonTigny 1985; Vleeming et al. 1989a, 1989b, 1990a, 1990b, 1992a, 1992b). More recent interest in rehabilitation involving the SI joint may be attributable in large part to the following two factors:

1. Publications of studies in the mid-1990s suggesting initially that approximately 20–30% of low back and referred pain came from the SI joint itself and/or the surrounding ligaments, muscles and other soft tissues involved in the functioning of the joint (Maigne et al. 1996, Schwarzer et al. 1995).
2. Presentation of the first International World Congress on 'Low Back Pain and its Relationship to the Sacroiliac Joint', hosted by San Diego in 1992 and, subsequently, by other major cities on a tri-annual basis. The congress has become a forum for the presentation of clinical experience and ongoing research on the SI joint and the lumbo-pelvic hip complex and has led to the publication of a number of books and articles in this field (e.g. Vleeming et al. 2007; Lee 2011).

Over the past decade, ongoing integration of clinical experience and research (e.g. Willard 2007, DeRosa & Porterfield 2007; Barker & Briggs 1998, 1999, 2004, 2007) has led us to recognize that:

1. The 'inner core' muscles help stabilize the pelvis and lumbar spine and, in tandem with the 'outer core' muscles, ligaments and myofascia form a system of well-defined 'slings' or 'cylinders' that can:
   a. absorb shock
   b. help support the bony structure of the spine, pelvis and hip joints and allows for weight transfer through the acetabular, sacroiliac and lumbosacral regions
   c. provide stability in preparation for carrying out activities with other parts of our body
   d. ensure balance and facilitate motion of the pelvis, spine/trunk and the limbs to carry out a specific action, such as throwing a ball
2. As a result of the functional kinetic interlinkage of the skeleton with these core muscles and myofascial 'slings', pathology affecting any of these structures can stress other proximal and even distal sites, sometimes to the point of interfering with their proper function and causing them to become another 'pain generator' (Vleeming & Stoeckart 2007; see also Ch. 8). Rotation of a vertebra, pelvic malalignment, excessive tension in a particular ligament or muscle are all interlinked and affect the function of the rest of the musculoskeletal system. Treatment needs to address that fact; it cannot be restricted to one site and will often require use of more than one treatment modality in order to be successful.
3. Malalignment of the pelvis and spine initially may not be painful. However, with time the stress on an increasing number of structures is more and more likely to result in:
   a. irritation and eventual hypersensitivity of the nociceptive nerve fibres supplying these structures (Willard 2007)
   b. chronic reactive contraction of specific muscles that are attempting to decrease movement of a painful structure and/or to stabilize a lax joint, with eventual complicating compromise of their own blood supply to the point where the muscles become symptomatic as well
   c. adaptive changes in gait as a result of the biomechanical changes and/or in reaction to pain.
4. All these factors combined are now felt to be the primary cause and/or an aggravating factor in as many as 50-60% of those presenting with low back pain and referred pain symptoms from this site, or 'pain generator' (Vleeming & Stoeckart 2007). Pain may localize to the structure initially involved (i.e. vertebra, lumbosacral junction, SI joint or other) but even at the onset can present as referred pain felt only nearby or at a distant site on the same or opposite side (see 'Introduction 2002'; Fig. 3.63). Eventually, the abnormal stress pelvic malalignment exerts on soft tissues and joints throughout the body may cause them to become painful and a source of referred pain, so that the actual site or sites where the pain is felt may be misleading to the person reporting the pain and to those trying to determine and treat the underlying problem that precipitated this chain of events. An example is the common complaint of pain 'from the hip joint' on one side, when the pain is actually:
   a. originating from the nearby SI joint or trigger points in piriformis (Fig. 3.45), or
   b. referred from the iliolumbar or sacroiliac ligaments to the hip joint, groin or greater trochanter regions (Figs 3.46, 3.62, 3.63).
5. Recognition of malalignment and the typical problems it can cause is, therefore, a key factor in helping determine whether the symptoms and signs on clinical examination are attributable to the malalignment *per se*, or whether the malalignment is covering up an underlying clinical problem.

This chapter will examine some old and new concepts regarding the SI joint and lumbo-pelvic-hip complex, then proceed to look at what will be the focus of this book: the common presentations of malalignment - 'rotational malalignment', 'upslip' and 'downslip', 'outflare/inflare', sacral torsion and 'vertebral rotational displacement' - before discussing some of the tests that have, over the past decade, gained acceptance as being the more reliable ones for examining the pelvis and spine in order to diagnose an alignment problem.

THE SACROILIAC JOINT

The SI joints are planar joints that function to:

1. transfer the loads generated by gravity and the weight of the trunk and upper body to the ilia and onto the ischial tuberosities in sitting and through the hip joints to the lower extremities in standing (Fig. 2.1A)

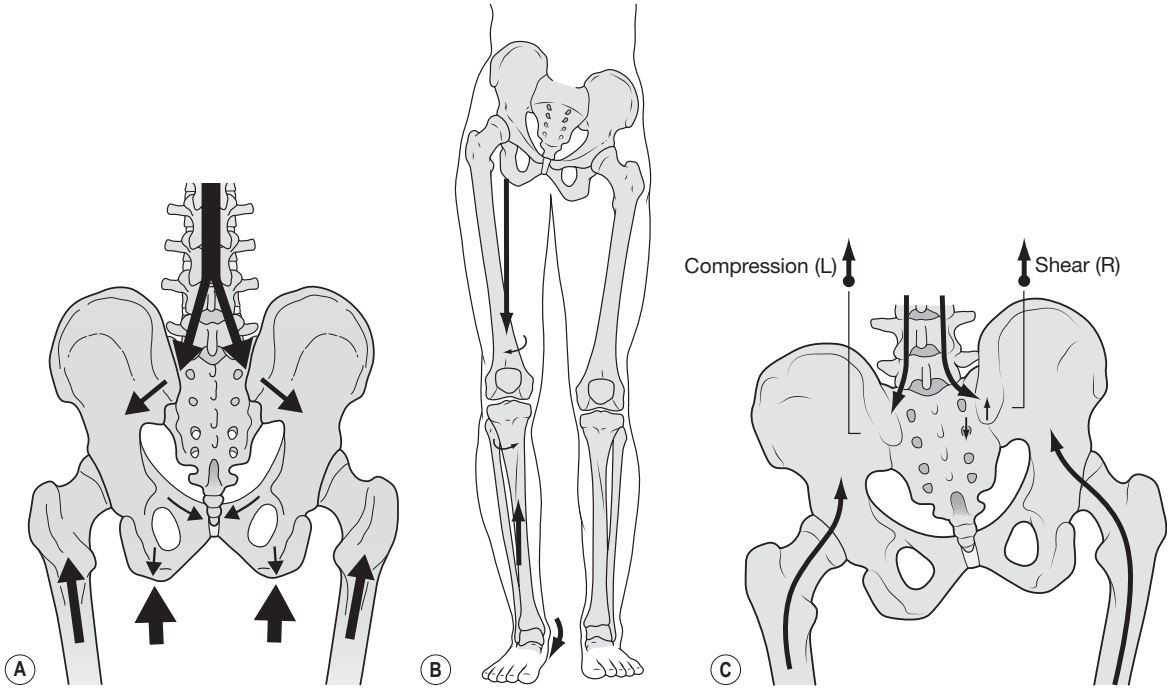

Fig. 2.1 Weight transfer forces through the lumbo-pelvic-hip complex from above and below. (A) In standing and sitting (pelvis in alignment, leg length equal). (B) On right one leg stance. (C) Changes in loads and forces imparted to the sacroiliac joint with a left frontal plane asymmetry. The right joint is more vertical, creating greater shear. *(Courtesy of DeRosa & Porterfield 2007.)*

2. transfer weight in the opposite direction, in sitting, standing, walking or falling onto one or both ischial tuberosities or the knees or feet – through the ilia onto the sacrum and upward by way of the lumbosacral junction (Fig. 2.1,B,C)
3. act as a shock absorber, particularly at heel-strike and
4. diminish any iliac-on-sacral surface translation or actual shear, when properly positioned (Fig. 2.1A).

Some SI joint motion does occur and seems to:

1. decrease the energy cost of:
   a. ambulation (DonTigny 1985, 1990, 2007)
   b. lifting (Masi et al. 2007)
2. aid delivery

   The comparatively flat joint surfaces allow movement in a way that makes it possible for women to deliver what are, in evolutionary respects, rather large babies.
3. help decrease stress on the pelvic ring of bones

   Combined with movement at the symphysis pubis, they are felt to decrease the risk of the pelvic ring 'cracking' that a solid ring would be subjected to (Vleeming & Stoeckart 2007; Adams et al. 2006).
4. absorb stresses and store energy

   Stresses are absorbed in large part by the complex of ligaments and myofascial slings (see below; Figs 2.35-2.39) that act on each SI joint, helping to absorb shock, to stabilize the joint for load transfer and to store or provide energy at select points when walking and lifting

A basic knowledge of SI joint development, configuration and biomechanics is crucial to the understanding and diagnosis of asymmetries of the pelvis and spine. At the same time, it must be emphasized that the SI joints are but two of the joints inherent to the lumbo-pelvic-hip complex and comprise but one aspect of what has here been designated the 'malalignment syndrome'. It is unfortunate that, in the

past, discussion so often centred on the SI joints, and it is really only since the 1990s that there has been more recognition of the other structures that are part and parcel of the lumbo-pelvic-hip complex and how they all interact. The discussion that follows in this and subsequent chapters should help put the role of the SI joints into proper perspective.

For a more detailed discussion of the most recent thinking and scientific studies on pelvic and SI joint embryology, development and ageing, and on the kinetic interaction of the pelvis with the spine and the hip joints, the reader is referred to the excellent presentations on these topics in 'Muscle Energy Techniques' (Chaitow 2006), 'The Pelvic Girdle' (Lee 2004a), 'Diagnosis and Treatment of Movement Impaired Syndromes' (Sahrmann 2002), 'Movement, Stability and Pelvic Pain' (Vleeming, Mooney, Stoeckart et al. 2007) and other publications in text and as individual papers.

ANATOMY, DEVELOPMENT AND AGING

The exquisite work by Bowen and Cassidy (1981), Bernard and Cassidy (1991) and others revealed the following:

First, at birth, one finds the well-defined cartilaginous surfaces, synovial fluid and capsular enclosure typical of a synovial joint (Bernard & Cassidy 1991; Bowen & Cassidy 1981; Cassidy 1992; Dihlmann 1967; Sashin 1930; Solonen 1957; Willard 2007; Williams & Warwick 1980).

A thin fibrocartilagenous cover then develops over the iliac surface, in contrast to the thick layer of hyaline cartilage evident on the sacral surface.

Second, as growth continues:

1. the articular surfaces of the SI joint eventually assume an L-shape, with a shorter, almost vertical, upper arm and a longer, lower arm directed posteriorly and inferiorly (Figs 2.2, 2.3C)
2. these arms can be oriented in a different plane relative to the vertical axis, creating a propeller-like appearance (Fig. 2.3B).
3. with time, the 'propeller' aspect of this 'L-shape' is accentuated by the development of complementary convexities and concavities, variously described as follows:
   a. by Resnick et al. (1975)
      - in the upper (cephalad) arm, a sacral convexity complementing an innominate concavity
      - in the lower (caudad) arm, an innominate convexity that fits into a sacral concavity
   b. by Masi et al. (2007)
      - upper and lower 'ileal convexities that match sacral concavities' (Fig. 2.2)
4. in addition, the sacrum widens anteriorly, creating an anterior-to-posterior wedging effect (Figs 2.2, 2.3, 2.4B, 2.10A, 2.11A, 2.46BD).

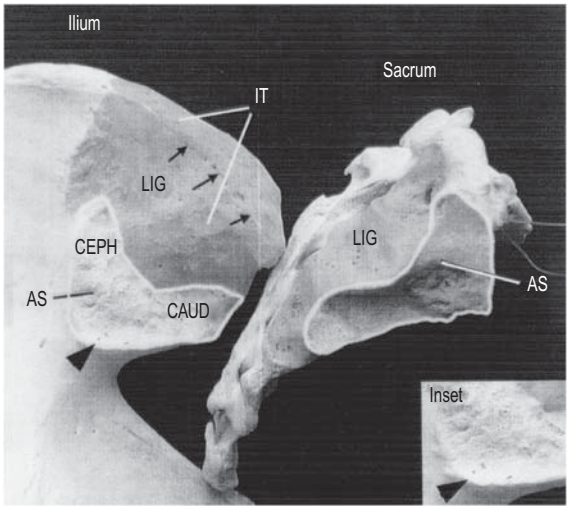

Fig. 2.2 The right sacroiliac joint is opened so that the opposing surfaces can be viewed simultaneously. . .The topography of the articular surfaces (AS) is irregular but congruent, with slight convexity on the ilial side, and complementary concavity on the sacral side. Both articular surfaces have numerous pits and surface roughenings and these are clearly visible in the inset [which] is an enlargement of the iliac auricular surface. Corresponding pits on the two photographs are indicated by arrowheads. The more posterior part of the joint is shaded and is a syndesmosis. It provides extensive areas of ligamentous attachment (LIG), particularly the strong interosseous ligament. . .at the centre of an 'axial joint', the pivotal point around which the sacrum rotates in nutational and counternutational movements. The erector spinae muscle is attached to the most posterior part of the iliac tuberosity (IT). . .Note the wedge shape of the sacrum, with the superior part of the bone, nearer the sacral promontory, being wider anteroposteriorly than the inferior part. *(Courtesy of Masi et al. 2007.)*

Third, the joint capsule thickens anteriorly to form the anterior or ventral sacroiliac ligament; this is a weak ligament that has been shown to be continuous with the anterior fibres of the iliolumbar ligament (Fig. 2.4A). The interosseous ligament forms the posterior border of the joint; it constitutes the

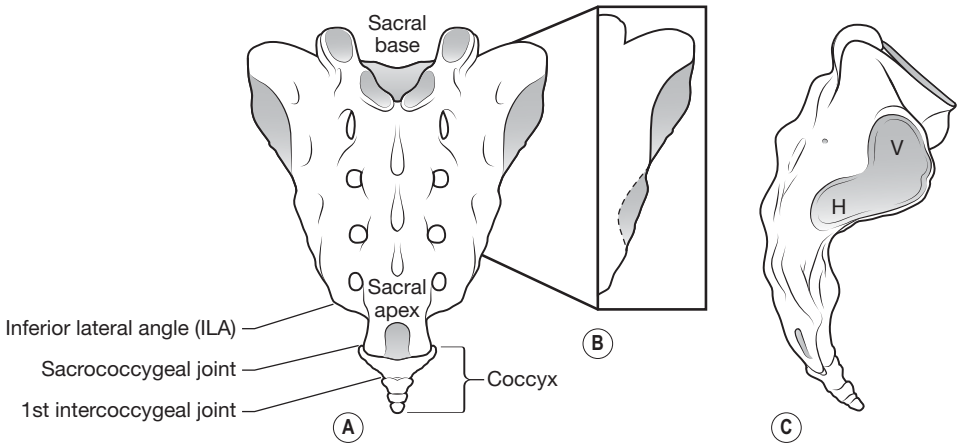

Fig. 2.3 Posterior aspect of the sacrum and coccyx, and configuration of the adult sacroiliac joint. (A) Anteroposterior view: major bony landmarks. (B) Angulated inset showing orientation of the two main arms of the sacral articular surface along different planes relative to the vertical axis, which creates a propeller-like shape. (C) Lateral view: L-shape of the sacroiliac joint (H = horizontal arm; V = vertical arm). *(Redrawn courtesy of Vleeming et al. 1997.)*

strongest ligament supporting the SI joint and makes up for what is usually a rudimentary or even absent posterior joint capsule (Figs 2.4B, 2.13Aiii). Additional support comes from the short posterior (dorsal) sacroiliac ligaments, the long posterior (dorsal) sacroiliac ligament, also the iliolumbar, sacrotuberous and sacrospinous ligaments (Figs 2.5A, 2.45). The sacrum literally ends up suspended between the ilia by these ligaments.

Fourth, Bellamy et al. (1983) observed that the SI joint is surrounded by the largest and most powerful muscle groups in the body but that none of these directly influenced the movement of this joint. However, as Lee pointed out (1992a), very few articulations in the body are actually capable of independent motion, and although the muscles crossing the SI joint are not typically described as prime movers of that joint, motion can occur at the SI joint as a result of their contraction. Lee went on to list 22 muscles that do affect SI joint movement, ranging from latissimus dorsi proximally to sartorius distally. Richard (1986) observed that 36 muscles have their insertion on each ilium but that only 8 of these are also attached to the sacrum; some of the others just cross the joint but provide a key function in establishing and maintaining the axes of movement (e.g. gluteus maximus posteriorly; see Figs 2.5B, 2.37) or stabilizing the joint (e.g. iliacus anteriorly; see Figs 2.46B, 4.2).

The work of Vleeming et al. (1989a) is of particular interest in this respect. From their initial dissections on 12 cadavers, these authors reported that gluteus maximus was attached to the sacrotuberous ligament in all cases. In 50% of dissections, there was also a 'fusion' of the sacrotuberous ligament, unilateral or bilaterally, with the tendon of the long head of biceps femoris at its origin (Figs 2.6, 2.37). In some specimens, 'fusion' to the ligament was complete so that there was actually no connection of this muscle to the ischial tuberosity itself.

Vleeming et al. (1989b) showed how load application to the sacrotuberous ligament, either directly to the ligament or by way of its continuations with the long head of biceps femoris or the attachments of gluteus maximus, significantly diminished the ventral (forward) rotation of the base of the sacrum (Figs 2.6, 2.59). They went on to demonstrate that these forces resulted in a compression of the sacral and iliac surface, increasing the coefficient of friction and thereby decreasing movement at the SI joint by what they termed 'force

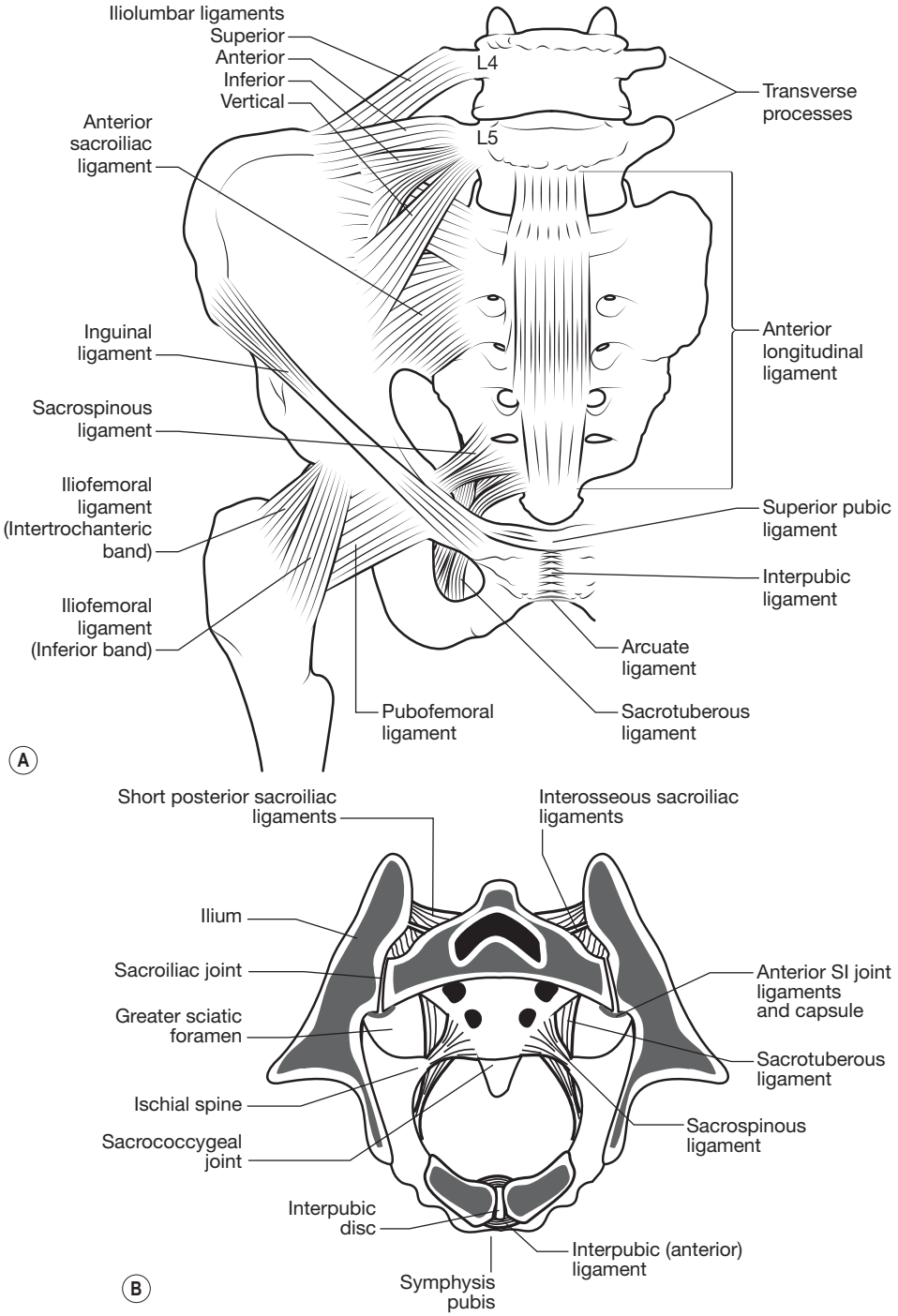

Fig. 2.4 Pelvic ring: articulations and ligaments. (A) Anterior view. (B) Superior view (note the anterior widening of the sacrum).

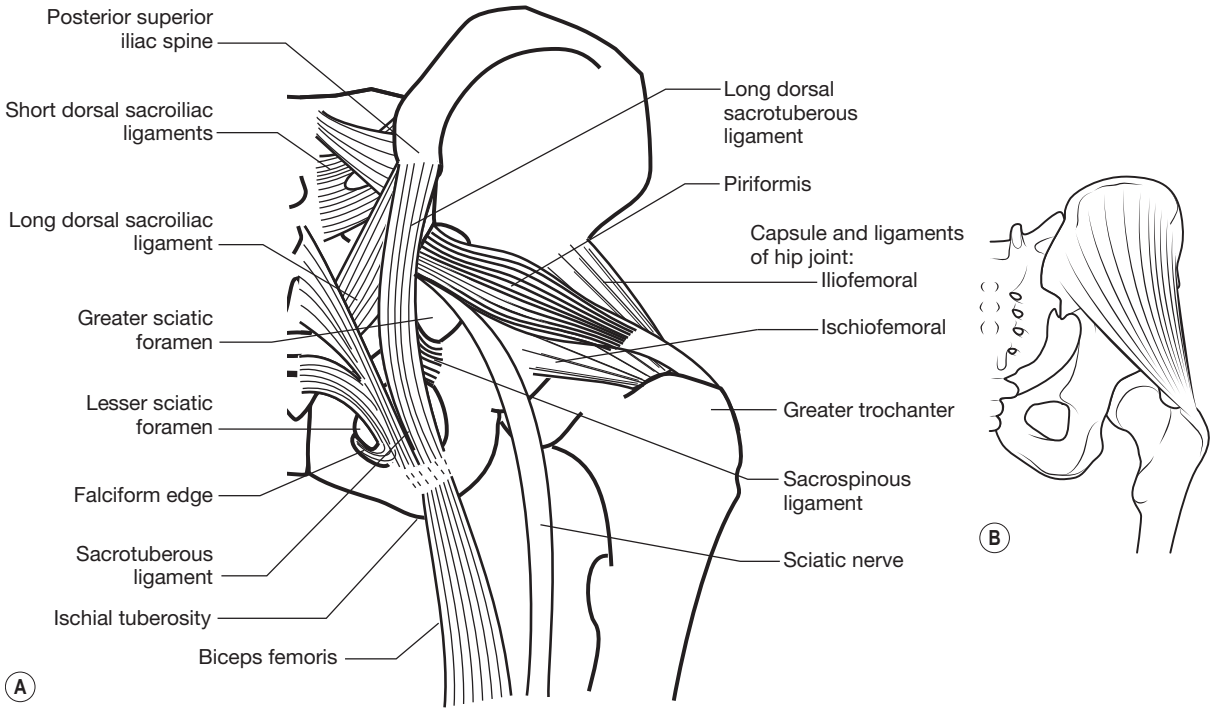

Fig. 2.5 (A) Posterior pelvic ligaments and muscles that act on the sacroiliac joint (see also Figs 2.37, 2.45). (B) Gluteus maximus.

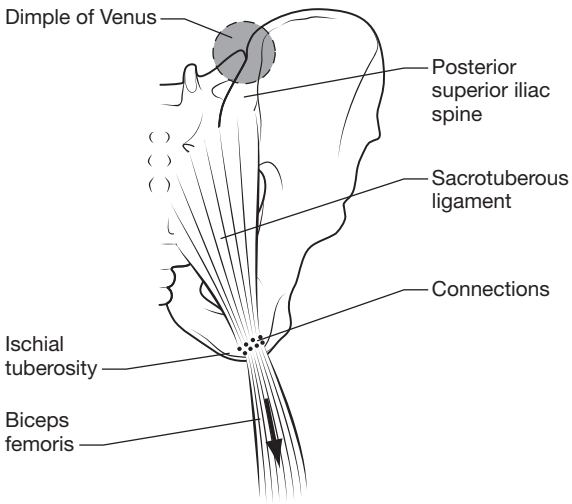

Fig. 2.6 Tension in the sacrotuberous ligament can be augmented by increasing tension in the biceps femoris, and vice versa, when there are fibrous connections between the ligament and the muscle (see also Figs 2.37, 2.59). Note the left 'dimple of Venus', overlying the depression formed at the underlying junction of the sacral base with the left ilium. *(Redrawn courtesy of Vleeming et al. 1997.)*

closure', which will be discussed further under 'self-locking mechanisms' and 'form and force closure' below (Vleeming et al. 1990a, 1990b). The link of the sacrotuberous (ST) ligament to rectus femoris has been repeatedly verified subsequently and also, more recently, evidence that this ligament is usually connected to semimembranosus as well (Barker & Briggs 2004).

These findings are but one illustration of how specific muscles may indirectly affect the sacrum, the innominate bones and hence the function of the joints of the pelvic girdle by causing joint motion, compression or both. Recent work by these and other authors (e.g. Pool-Goodzwaard et al. 2003; DeRosa & Porterfield 2007) has more clearly defined the role of these so-called 'inner' and 'outer' pelvic 'core' muscles as dynamic stabilizers of the SI joints in particular and of the lumbo-pelvic-hip girdle and trunk in general (see 'Kinetic function and stability' below; Figs 2.29-2.40).

Fifth, the pre-pubertal SI joint surface is described as planar – flat opposing sacral and iliac surfaces that allow for small gliding movements in all directions (Fig. 2.7A). After puberty, most

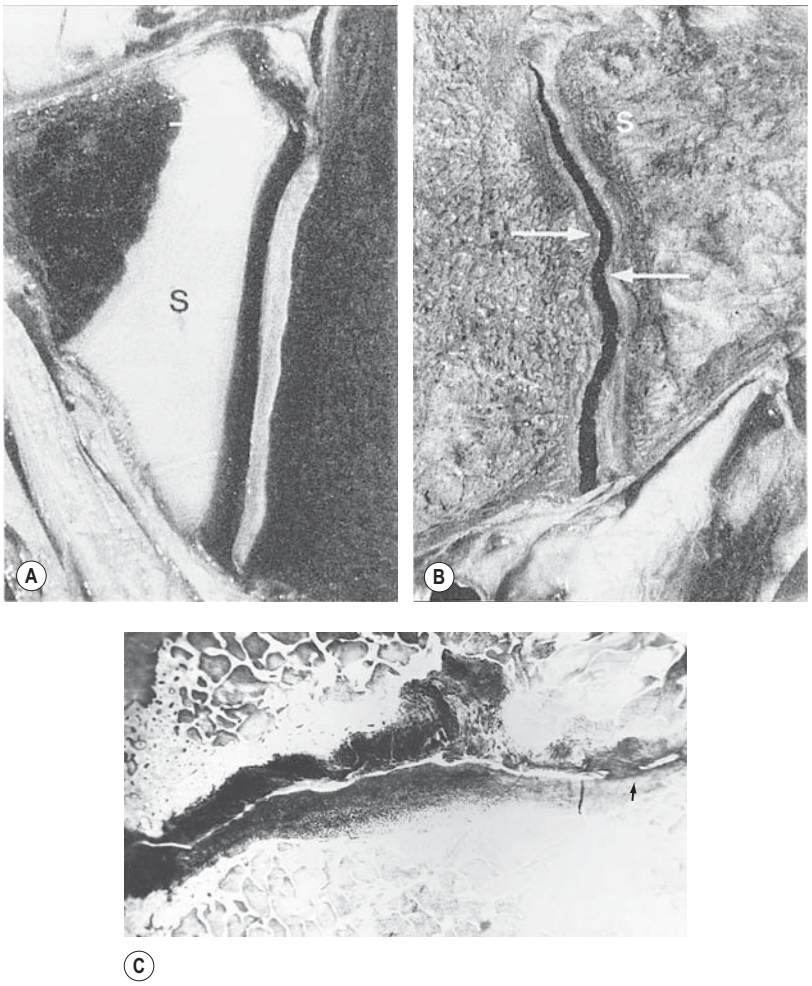

Fig. 2.7 (A,B) Coronal section through two embalmed male specimens: (A) Age 12 - the planar appearance of the sacroiliac joint (S denotes the sacrum). (B) Over age 60 - the presence of ridges and grooves is denoted by arrows. *(Courtesy of Vleeming et al. 1990a.)* (C) Sacroiliac joint of a female, 81 years of age. Note the erosion of the articular cartilage [but the sacroiliac joint is still visible except for] . . . the intra-articular fibrous connection (arrow). *(From Lee 2004a, reproduced courtesy of Walker 1986.)*

individuals develop 'a crescent-shaped ridge running the entire length of the iliac surface with a corresponding depression on the sacral side' (Fig. 2.7B); this complimentary ridge and groove are now felt to lock the surfaces together and increase stability of the SI joint (Vleeming et al. 1990a; Gracovetsky 2007). Also, 'with increasing age the surfaces become more irregular and prominent' (Cassidy 1992, 41). The apparent 'roughening' of these surfaces may be an adaptation to adolescent weight gain; certainly, work by Vleeming et al. (1990a, 1990b) supported the conjecture that these macroscopic changes represent functional, rather than pathological, adaptations. These authors presented evidence that articular surfaces with both a coarse texture and ridges and depressions have high friction coefficients, consistent with their view that the roughening represents a 'non-pathological adaptation to the forces exerted at the SI joints, leading to increased stability' (Vleeming et al. 1990a). The same authors raised two points of particular interest:

1. These physiologically normal intra-articular ridges and depressions could easily be misinterpreted as osteophytes on radiological studies. They pointed out that:

   'it might well be that a textbook statement like 'The sacroiliac synovial joint rather regularly shows pathologic changes in adults, and in many males more than 30 years of age, and in most males after the age of 50, the joint becomes ankylosed . . .' (Hollinshead 1962) is based on an incorrect interpretation of anatomical data'

   and that:

   'with standard radiological techniques, the [cartilage-covered] ridges and depressions easily can be misinterpreted as pathologic, because of the well known overprojection in SI joints'

   (Vleeming et al. 1990a)

   The angle of projection and whether or not the subject is weight-bearing asymmetrically, as he or she would do when out of alignment, are other factors to consider (see Ch. 4 – 'Implications for Radiology and Medical Imaging'; Figs 4.24, 4.30, 4.31, 4.33)
2. SI joints with intact cartilage showed the friction coefficient to be particularly high 'in preparations with complementary ridges and depressions'. This led them to conjecture that:

   'Under abnormal loading conditions . . . it is theoretically possible that an SI joint is forced into a new position where ridge and depression are no longer complementary. Such an abnormal joint position could be regarded as a blocked joint'

   (Vleeming et al. 1990b: 135)

This 'blocked joint' may refer to the frequent finding of a decrease or even absence of movement, also referred to as 'locking', in one or other SI joint on clinical examination of those presenting with 'malalignment' (discussed in detail under 'Functional or dynamic tests' below, and in Ch. 3). Note that this decrease or loss of mobility occurs 'under abnormal loading conditions'. Normal interlocking of the surfaces contributes to joint stability and limitation of range of motion of the SI joint when this is functionally required; for example, to enhance the force-closure mechanism occurring on the weight-bearing side during the gait cycle (Snijders et al. 1993a, Vleeming et al. 1997, Hungerford & Gilleard 2007).

Sixth, the joint may retain its synovial features well into the patient's 40s or 50s. The fibrocartilage covering the iliac side consistently starts to degenerate early in life, usually by the third decade in males and the fourth or fifth decade in females. By this time, narrowing of the joint space, sclerosis, osteophyte formation, cysts and erosions of the articular surfaces may be evident on X-Rays (Figs 2.8A, 4.38) and on CAT scan/computed tomography (Shibata et al. 2002). Given that these changes could be evident so early on yet were usually asymptomatic, Vleeming et al. (1990a) remarked that they most likely represented a functional adaptive change to an increase in weight. Shibata et al. (2002) and others (Schunke 1938; Bowen & Cassidy 1981; Walker 1986, 1992; Faflia et al. 1998) felt these were 'degenerative changes'. Iliac osteoarthrosis is indicated by an initial fibrillation of the cartilage, plaque formation and eventual peripheral erosions and subchondral sclerotic changes.

In contrast, osteoarthritic changes are rarely evident on the sacral side by the fifth decade. With advancing age, the typical changes of worsening osteoarthritis (deep erosions, areas of exposed subchondral bone, enlarging osteophytes and increasing fibrous connections) result in both articular surfaces becoming totally irregular. In some individuals, this change may progress to a complete replacement of the joint space with fibrous tissue, eventual calcification and a complete loss of movement. However, 'in most cases, the joint remains patent throughout life. Fusion can occur by synostosis or by fibrosis' (Cassidy 1992: 41).

Fibrous adhesions, although more common in older specimens, have been seen in younger males, but 'to a lesser degree'. Faflia et al. (1998) reported a higher prevalence of advanced, asymmetric non-uniform SI joint degenerative changes in obese, multiparous females compared to age-matched normal-weight, non-multiparous women and to men (Lee 2004a). Whereas bony ankylosis is rare, para-articular synostosis has been reported to be a common finding in both males and females over the age of 50 (Valojerdy et al. 1989). Most will continue to show some SI joint movement well into their 70s and 80s (Bowen & Cassidy 1981, Cassidy 1992, Colachis et al. 1963). Some studies have actually refuted the existence of absolute intra-articular ankylosis in the elderly, suggesting that at these age levels they show primarily intra-articular fibrous connections and osteophytes, cartilagenous erosions, plaque formation (Resnick et al. 1975; Walker 1986) – all

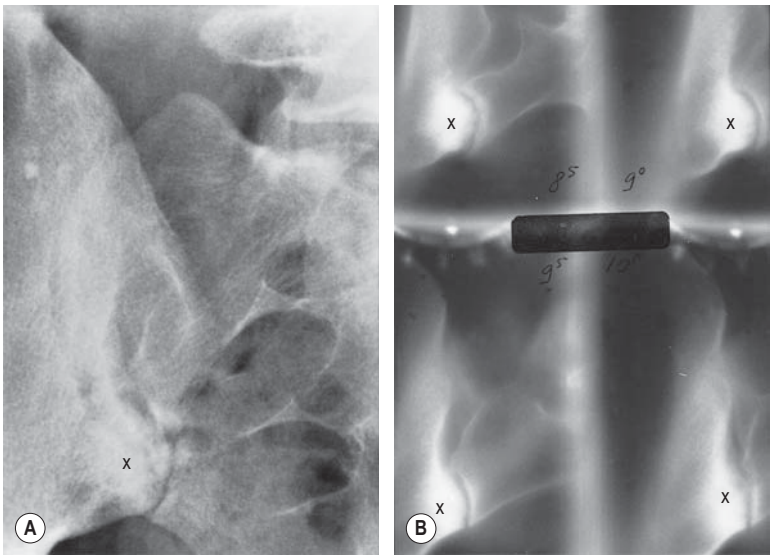

Fig. 2.8 Iliitis condensans. (A) Plain X-ray of the right sacroiliac joint (SIJ) with irregular and sclerosing changes in S3 (X). This type of sclerosis of the ilium can cause confusing plain X-rays. (B) Tomography of the posterior parts of the same SIJ. There is sclerosis of the same ilium (X) with subchondral cysts and slight sclerosis of the sacrum, but normal joint width. The numbers 8.5 to 10 denote the distance from the table top. *(Courtesy of Dijkstra 2007.)*

these resulting in narrowing of the SI joint space (Fig. 2.8B). Schunke back in 1938 reported that actual SI joint fusion attributable to ankylosing spondylitis was more likely to be found in younger subjects; if such a fusion was found in an older person, it was more likely attributable to them having suffered ankylosing spondylitis somewhere in their younger years.

Finally, the clinical significance of the premature osteoarthrosis on the iliac side is not known. However, similarly to other sites in the body, osteoarthrosis does not necessarily cause symptoms. As Magora & Schwartz already reported in 1976, and others have since confirmed, osteoarthrosis of the spine correlates more with increasing age than with back pain. The same is probably true for the SI joint.

SI JOINT MOBILITY

There has been much debate over whether movement can occur at the SI joint, despite a wealth of studies dating back as far as the turn of the 19th century indicating that small measures of movement around specific axes were indeed possible (Albee 1909; Ashmore 1915; Beal 1982; Bowen & Cassidy 1981; Colachis et al. 1963; Dihlman 1967; Egund et al. 1978; Frigerio et al. 1974; Meyer 1878; Miller et al. 1987; Pitkin & Pheasant 1936; Sashin 1930; Solonen 1957; Strachan 1939; Weisl 1955).

Methods of assessment have included:

1. analysis of the SI joint in various positions of the trunk and lower extremities by:
   a. X-rays (Albee 1909; Brooke 1924)
   b. inclinometer measurements of surface markers on the innominate, sacrum and femur (Hungerford et al. 2001; Hungerford 2002)
2. computerized analysis using a metronome skeletal analysis system (Smidt 1995)
3. Doppler imaging of vibrations across the SI joint (Buyruk et al. 1995a, 1995b, 1997, 1999; Damen et al. 2002a)

The question was settled more definitively by *in vivo* sudies using:

1. roentgen stereophotogrammetric analysis - a computerized dual-radiographic technique for assessing the relative movement of implanted titanium balls serving as reference points on the ilium and sacrum (Sturesson et al. 1989, 2000a, 2000b).

2. Kirschner rods implanted in both ilia and the sacrum in healthy volunteers (Jacob & Kissling 1995; Kissling & Jacob 1997).

Fig. 2.9 shows how the pelvis as a unit can:

1. rotate around the 3 basic axes
   a. the coronal axis, to tilt anterior and posterior in the sagittal plane
   b. the vertical axis, to rotate right (clockwise) and left (counter-clockwise) in the transverse (horizontal) plane
   c. the sagittal axis, to side-flex right and left in the coronal (frontal) plane
2. move, or 'translate', along the 3 planes indicated
   a. to right or left (medial, lateral) along the coronal axis
   b. up or down (cephalad or caudad, respectively) along the vertebral axis
   c. forward or backward (anterior or posterior, respectively) along the sagittal axis

Movement of the SI joint is also triplanar and amounts to approximately 2–4 degrees of rotation and translation at best (Egund et al. 1978, Sturesson et al. 1989, 2000a, 2000b). Stevens and Vyncke reported 3.3 degrees mean axial rotation of the sacrum in the 'transverse plane' on side-bending in 1986. Previous reports suggested that asymmetry, both of the configuration and the amount of mobility possible on one side compared with the other, appears to be the rule (Bowen & Cassidy 1981; Vleeming et al. 1992a, 1992b). However, the studies using Doppler imaging of vibrations across the SI joint, mentioned above, have consistently shown that:

1. stiffness is variable between individuals, which is probably a key factor why range of motion is also likely to be variable
2. subjects with symmetrical side-to-side stiffness are more likely to be asymptomatic (no pelvic pain); whereas those with asymmetric stiffness are more likely to be symptomatic.

Most studies to date have, however, used a static approach to investigating a dynamic phenomenon. Even though studies have become increasingly refined, there is still some truth even now to the observation by Cassidy (1992) that 'a valid and reliable method for measuring this motion in patients has not yet been developed'. Also, none of the authors cited have indicated whether or not there was malalignment of the pelvis at the time of the study, nor mentioned any particular presentation. Malalignment results in asymmetrical opposition of the SI joint surfaces and can cause unilateral SI joint hypermobility, hypomobility or even 'locking', all factors that would result in an asymmetry of configuration and/or mobility (see Chs 3, 4).

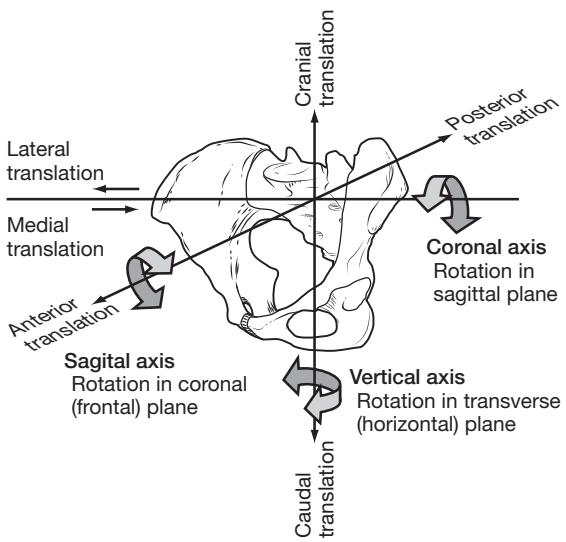

Fig. 2.9 Axes and planes around which sacroiliac joint movement occurs.

AXES OF MOTION

Motion at the SI joint is complex, probably not occurring around just one fixed axis but being a movement combining rotation and translation (Beal 1982; Bernard & Cassidy 1991; Egund et al. 1978; Frigerio et al. 1974; Kissling & Jacob 1997; Walker 1992). A good description of the directions and degrees of freedom of movement at the SI joints was already found in Gray's Anatomy in 1980 (Williams & Warwick). At risk of oversimplification, the primary motions that can occur are outlined in Box 2.1 and Figure 2.9.

Rotation and/or translation of the sacrum or an innominate results in a relative displacement of the SI joint surfaces (Figs 2.10, 2.11). Excessive rotation and/or translation in any direction can have a shearing effect. These surfaces may also become pathologically 'stuck' in any one position, Panjabi's so-called 'compressed' joint (see 'Kinetic function and stability' below; Figs 2.23, 2.24). SI joint nutation makes for stability, and counternutation for instability; the amount of nutation, or counternutation, can be of a normal or pathological degree.

BOX 2.1 Axes of motion of the sacroiliac joint

Rotational movement, 'anterior' or 'posterior' around the coronal axis in the sagittal plane

1. of one or both ilia relative to the sacrum; if both rotate, this may be:
   a. in the same direction simultaneously; e.g. as occurs usually on flexion or extension of the trunk (Fig. 2.116), or tilting of the pelvis when sitting (Fig. 2.80)
   b. in opposite directions (e.g. as occurs in the course of the normal gait cycle; Figs 2.10A, 2.21, 2.22, 2.41)
2. of the sacrum relative to both ilia; forward movement of the base has been designated as *nutation* and backward movement as *counternutation* (Figs 2.11, 2.17, 2.18, 2.19)

Upward or downward translation along the vertical or Y-axis

- also described as 'cranial and caudal translation', respectively; this may involve one or both ilia relative to the sacrum, or the sacrum relative to the ilia (Fig. 2.9)

Axial rotation of sacrum and ilia in the transverse plane

1. sacrum and ilia rotating as one unit around the vertical axis
   – normally occurs with clockwise or counterclockwise rotation of the pelvis when standing or walking (Figs 2.12, 2.13A)
2. an ilium relative to the sacrum
   a. the anterior part of the ilium moving either outward from or inward to the midline in the transverse plane (i.e. an outflaring and inflaring, respectively (Figs 2.13A, 2.17)
   b. some outflaring occurs in association with anterior, and inflaring with posterior, innominate rotation during normal gait (Fig. 2.13A) and flexion/extension manoeuvres (Fig. 2.17)
3. the sacrum relative to the innominates around the vertical axis, in the transverse plane (Fig. 2.89):
   – this normally occurs with trunk rotation in sitting (when the innominates are fixed by bearing weight on the ischial tuberosities) and during gait (Fig. 2.41)

Torsion of the sacrum around an oblique axis

1. torsion around the right or left oblique or 'diagonal' axis is one form, and usually happens in conjunction with some rotation around the vertical axis (Figs 2.14, 2.21 and Point 3 above)
2. the mean transverse axes (MTA) run from the sacral base down and over to the opposite innominate, crossing where the two parts of the L-shaped SI joint meet, at about the level of S2 (Richards 1986; Figs 2.3A, 2.10B, 2.14, 2.21, 2.42, 2.50)
3. these axes are named according to the side of origin from the sacral base (e.g. the right oblique axis starts from the right corner of the sacral base and runs downward and across to the left apex; Fig. 2.14)

Muscles that can effect nutation, and increase stability, include those that can:

1. rotate the innominates posteriorly relative to the base of the sacrum (Figs 2.10, 2.21); e.g. rectus abdominis (Fig. 2.31B) and biceps femoris (Fig. 2.59)
2. rotate the sacral base anteriorly (Fig. 2.11A); e.g. semispinalis or erector spinae muscles (Figs 2.37, 2.38) and multifidi (Fig. 2.29)

Muscles that effect counternutation, and decrease stability, include those that can:

1. rotate the innominates anteriorly (Figs 2.10, 2.21); e.g. iliacus, rectus femoris and the tensor fascia lata/iliotibial band complex (Figs 2.46B,C, 2.59)
2. rotate the sacral base posteriorly (Fig. 2.11B); e.g. pubococcygeus, ischiococcygeus and iliococcygeus, all levator ani muscles originating from the pubic rami and pulling forward on the apex of the sacrum by way of their insertions into the coccyx (Fig. 2.53B)

BIOMECHANICS

Movement around the various axes of the SI joints occurs as part of normal movement patterns involving the spine, pelvis and lower extremities throughout our day-to-day activities (DonTigny 1985, Greenman 1992, 1997; Figs 2.12-2.16). The sacrum influences the relative movement of the innominates, and vice versa, as tension is increased in the connecting soft tissues - primarily ligaments and

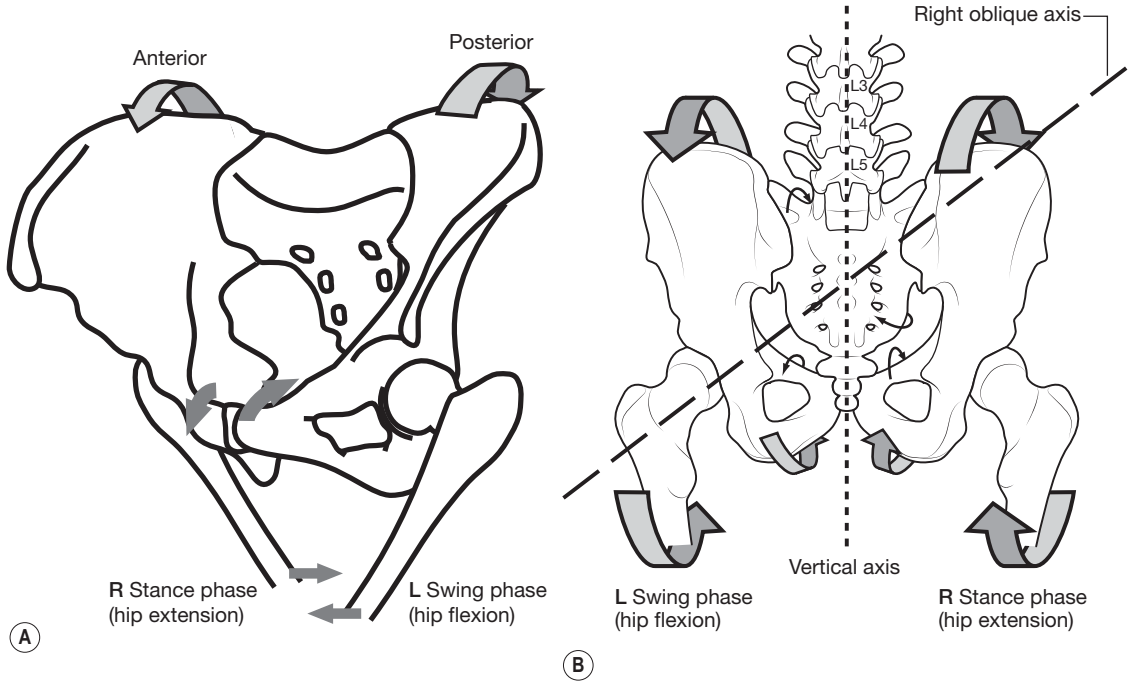

Fig. 2.10 Movement of the pelvic ring with normal gait. (A) Contrary rotation of the innominates relative to the sacrum. (B) Sacral torsion around the right oblique axis associated with 'right anterior, left posterior' innominate rotation (posterior view.)

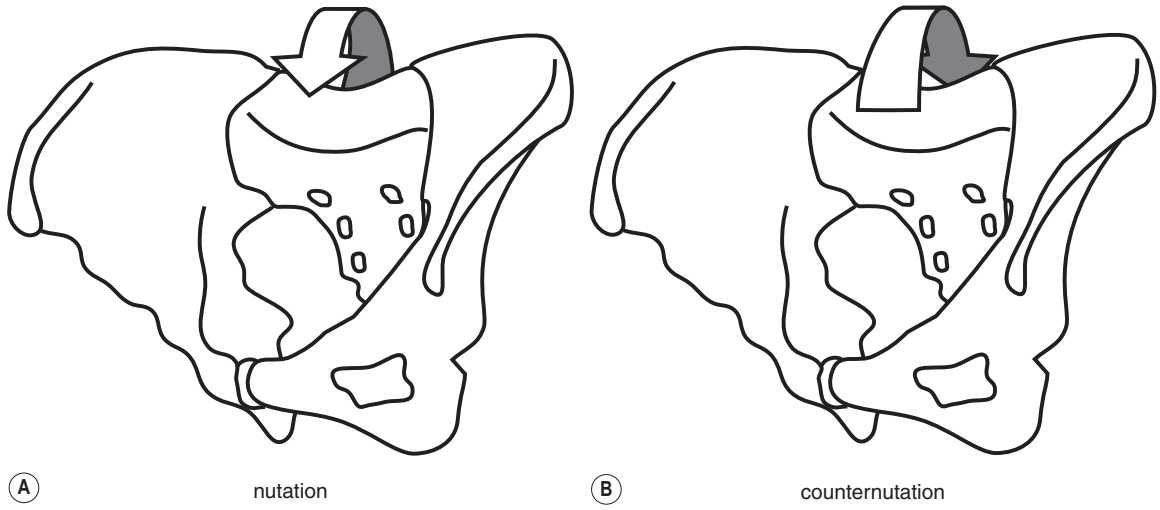

Fig. 2.11 Movement of the sacral base relative to the ilia. (A) Nutation (B) Counternutation

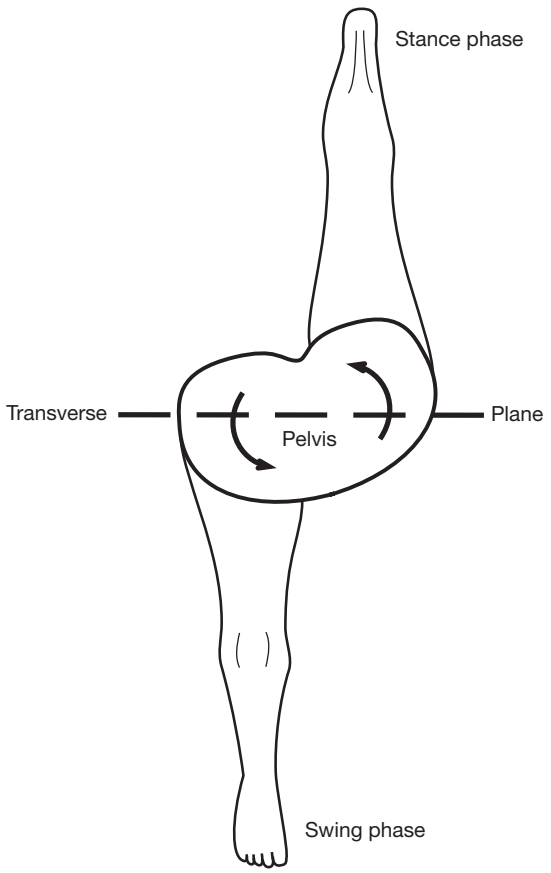

Fig. 2.12 Pelvic rotation in the transverse (horizontal) plane with normal gait: counterclockwise during the right swing, left stance phase (shown); clockwise with left swing, right stance.

muscles - that act on the SI joint(s). This is a normal phenomenon, as described, but will be affected by the presence of tight structures; for example, a tight biceps femoris acting on an SI joint by way of its connections to the sacrotuberous ligament (Fig. 2.6). In addition, the movement is likely to be asymmetrical when such tightness is worse on one side compared to the other. When sitting, this tightness is less of a problem as the innominates are relatively 'fixed' and less mobile than when standing.

Trunk flexion

In standing

Flexion initially results in a simultaneous forward rotation of the sacrum and innominates around the coronal axis in the sagittal plane which may continue through full flexion (Kapandji 1974; Figs 2.17, 2.116A, 2.117). The right and left innominate should move an equal amount. Flexion somewhere past 50–60 degrees sees the innominates and sacrum continuing to rotate forward symmetrically in most people. In some, however, the sacrum now starts to counternutate, the base moving posteriorly and the apex (coccyx) anteriorly, decreasing the lumbosacral angle and, therefore, the lumbar lordosis (Fig. 2.18A). Counternutation from this point on may occur on account of:

1. a posteriorly directed force applied to the sacral base by the flexing lumbar spine
2. a maximal tightening of the ligaments (interosseous, sacrotuberous and sacrospinous) effected by the initial nutation (Fig. 2.19A)
3. the presence of any other factor capable of opposing the progressive nutation of the sacrum; for example, tightness of:
   a. pubo-, ilio- and/or ischio-coccygeus (Fig. 2.53)
   b. the sacrotuberous ligament if continuous, in part or completely, with a tight rectus femoris (Fig. 2.6)

In sitting

The initial movement on trunk flexion is one of sacral counternutation as the innominates rotate anteriorly relative to the sacrum. Counternutation increases the tension in the long dorsal sacroiliac ligament in particular, eventually resulting in posterior rotation of the innominates and sacral nutation on further trunk flexion (Figs 2.19B, 2.80B).

Trunk extension

In standing

On extension, the innominates should rotate posteriorly to an equal extent and the sacrum nutates, increasing the lumbosacral angle and hence the lumbar lordosis (Figs 2.16, 2.18C).

In sitting

Initially, the innominates do not move as the spine extends and the sacrum nutates. Once nutation has taken up all the slack in the interosseous, sacrospinous

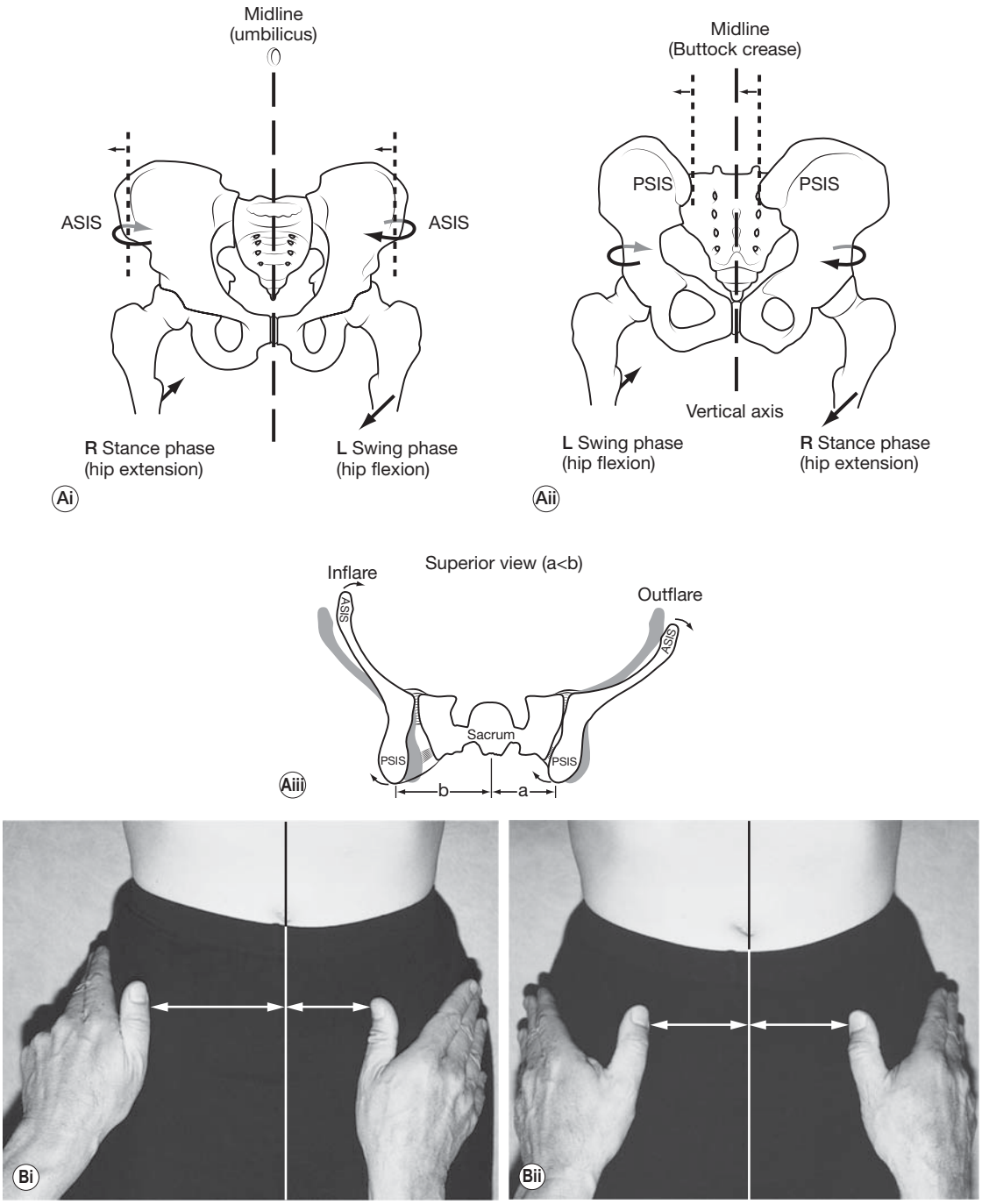

Fig. 2.13 'Inflare' and 'outflare' of the innominates in the transverse plane. (A) During normal gait cycle (right stance, left swing phase = the left inflares, the right outflares): (i) anterior view; (ii) posterior view; (iii) superior view. ASIS = anterior superior iliac spine; PSIS = posterior superior iliac spine. (B) With an actual 'outflare/inflare' presentation: relative to umbilicus (assuming that it is central in location), the thumbs resting against inside of the ASIS show: (i) initial asymmetry with a 'right outflare' (thumb away from the midline) and 'left inflare' (closer to the midline); (ii) symmetry following correction (equidistant from the midline).

(Continued)

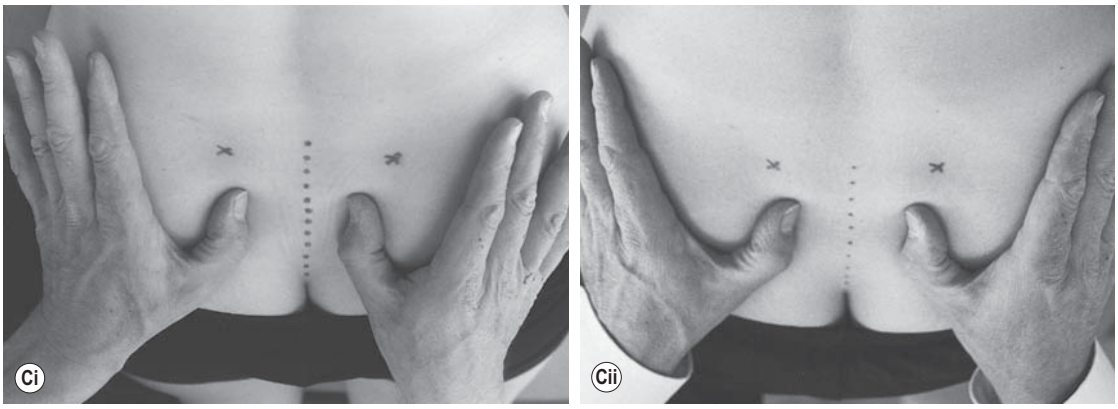

Fig. 2.13—cont'd (C) Relative to the buttock (gluteal) crease, thumbs against the inner aspect of the PSIS show: (i) initial asymmetry with 'right outflare' (thumb closer to the midline) and 'left inflare' (thumb away from the midline); (ii) right and left equidistant after correction of the 'outflare/inflare'.

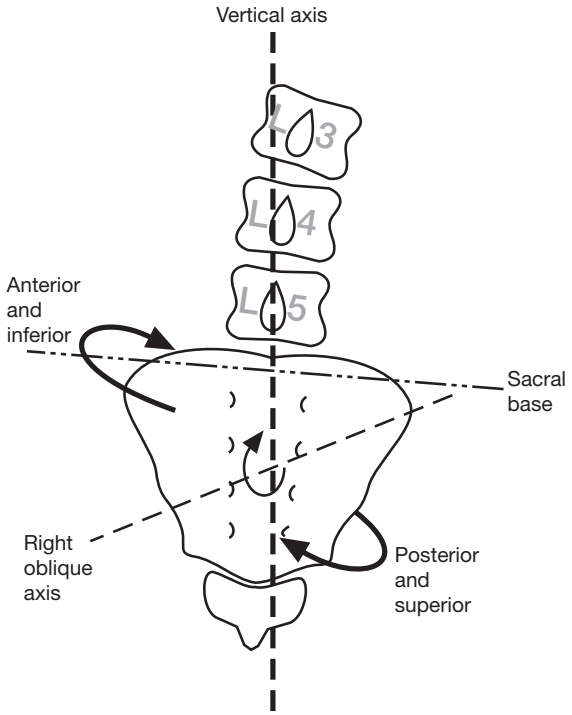

Fig. 2.14 Sacral torsion around the right oblique axis; also known as 'right-on-right' or R/R torsion pattern (see also Fig. 2.50)

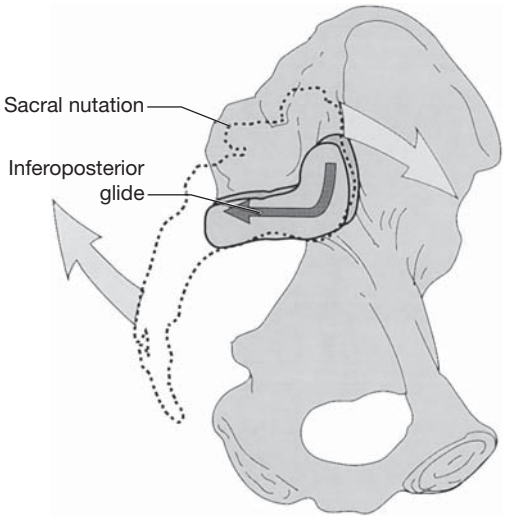

Fig. 2.15 When the sacrum nutates, its articular surface glides inferoposteriorly relative to the innominate (anterosuperiorly on counternutation). *(Courtesy of Lee 1999.)*

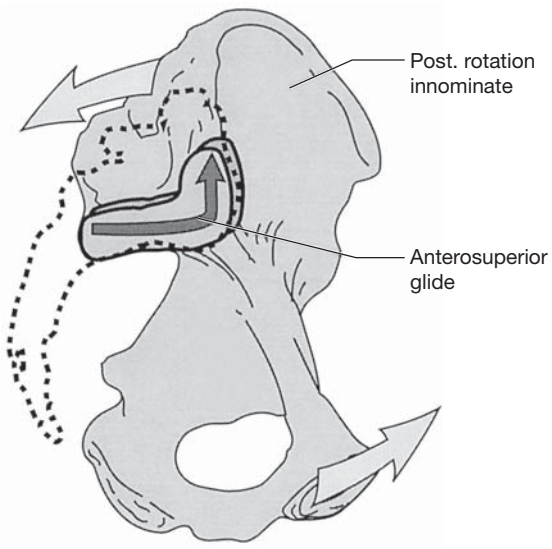

Fig. 2.16 When the innominate rotates posteriorly, its articular surface glides anterosuperiorly relative to the sacrum (inferoposteriorly on anterior rotation). *(Courtesy of Lee 1999.)*

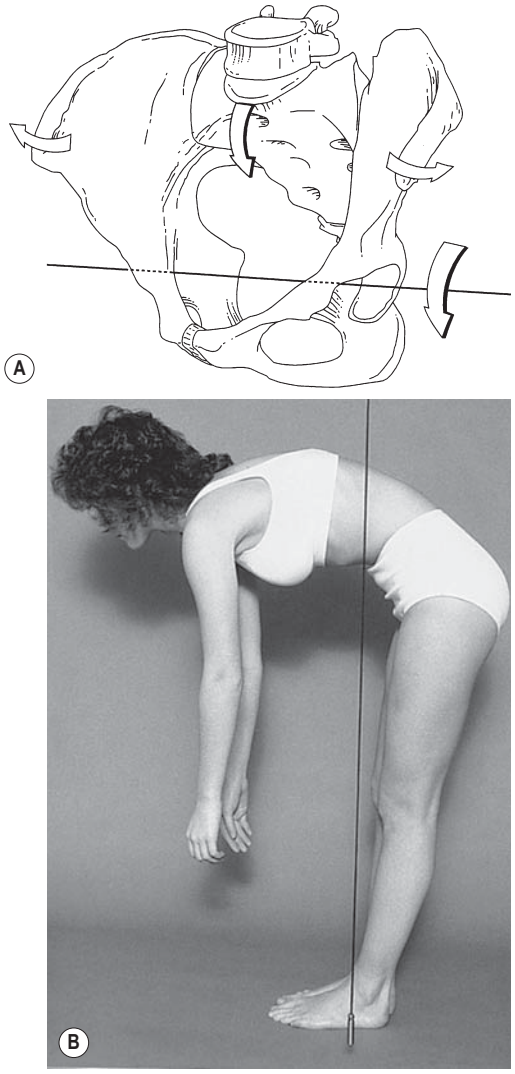

Fig. 2.17 Forward flexion of the trunk from the erect standing position normally results in initial sacral nutation, anterior rotation of the innominates and a concomitant outflare of both innominates. *(Courtesy of Lee 1999.)*

and sacrotuberous ligaments (Fig. 2.19A) and in the pelvic floor muscles and ligaments that attach to the coccyx, further extension will result in anterior rotation of the innominates (e.g. by increasing the traction force of the tight sacrotuberous ligament on the ischial tuberosity, pulling the innominate anteriorly).

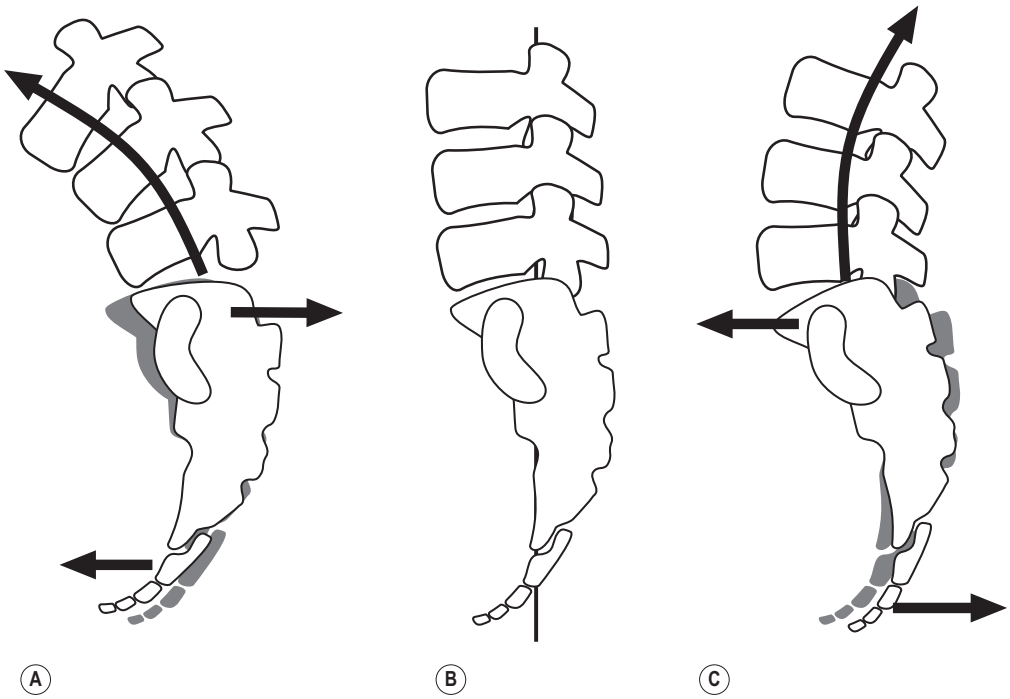

Fig. 2.18 Normal movement of the sacrum relative to the ilia. (A) Flexion past 45 degrees: sacral counternutation. (B) Neutral (standing). (C) Extension: sacral nutation.

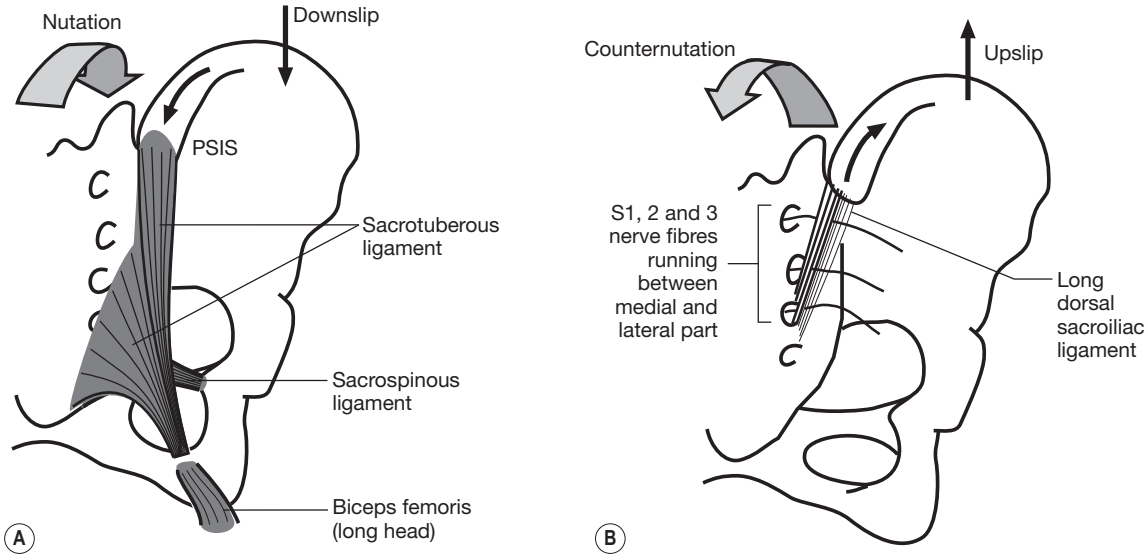

Fig. 2.19 Ligaments put under tension by the movement of an innominate or the sacrum relative to each other. (A) 'Posterior' rotation (= sacral nutation) and 'downslip' of an innominate: sacrotuberous, sacrospinous; also interosseous ligaments (not shown; see Figs 2.4B, 2.13Aiii). (B) 'Anterior' rotation (= sacral counternutation) and 'upslip' of an innominate: long dorsal sacroiliac ligament.

Landing on one leg

When jumping or missing a step and landing with the straight leg vertical and the foot directly underneath, the forces transmitted upward result in an ipsilateral SI joint movement consisting primarily of an upward translation of the innominate in the vertical plane relative to the sacrum (Fig. 2.20A). If there is a degree of angulation of the leg relative to the vertical axis at the moment of impact, there may be an element of anterior or posterior rotation in the sagittal plane. For example, missing the step(s) and landing with the straight leg angulated forward creates a force that can rotate the innominate anteriorly on that side, resulting in sacral counternutation and SI joint instability (Fig. 2.20B). Landing with the leg angulated backward can rotate the innominate posteriorly, resulting in sacral nutation and increasing SI joint stability. These changes are of particular importance when we come to consider the abnormal forces that can result in an 'upslip' and 'rotational malalignment' (Ch. 3). The biomechanics of standing on one leg are discussed in detail below (see 'Functional or dynamic tests'; Figs 2.121-125)

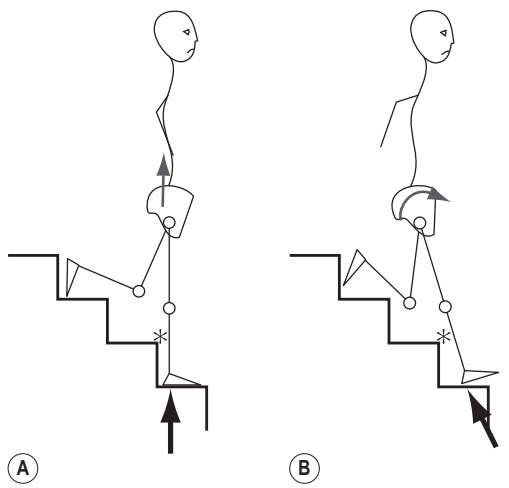

Fig. 2.20 Missing a step and landing with increased force on one extremity can cause malalignment of the pelvis.
A) With the leg vertical on impact, the force transmitted through the hip joint can result in upward displacement of the innominate relative to the sacrum (a so-called 'upslip').
B) Landing with the leg at a hip-flexion angle on impact results in an 'anterior rotational' force on the innominate, as illustrated.

Vertical forces on the sacrum

In standing, the sacrum is literally suspended between the innominate by the ligaments and may be in a slightly nutated or counternutated position (Fig. 2.4A,B). As proposed by Strachan in 1939, a force transmitted vertically downward from the lumbar region causes the sacrum to glide downward and flex (Fig. 2.15); traction applied from above causes the sacrum to move upward and extend (Fig. 2.16).

Ambulation

During ambulation, there is:

1. rotation of each innominate around the coronal axis in the sagittal plane - anteriorly on the side of hip extension, posteriorly on the side of hip flexion (Figs 2.10, 2.21, 2.41-1,3,5,7)
2. rotation of the pelvic unit as a whole around the vertical axis in the transverse plane - the ASIS moves forward with the leg during swing phase, backward on the side of the extending leg during stance phase (Fig. 2.12)
3. rotation of the pelvic unit as a whole around the sagittal axis in the coronal plane - the iliac crest is initially higher on the side of heel-strike and drops progressively on going past mid-stance to toe-off while the reverse is happening on the opposite side from toe-off to heel-strike (Fig. 2.41-4,8)
4. torquing of the sacrum, alternately to the right and left around the vertical and oblique axes with each gait cycle, concomitant with displacement of the pelvis as described (Figs 2.10B, 2.21).

For example, as the right leg swings forward, there is posterior rotation of the right innominate which results in a left rotation of the sacrum (around the left oblique axis), increase in sacral nutation and with this an increase in tension in the right sacrotuberous (ST), sacrospinous and interosseous ligaments. Contraction of biceps femoris to further increase ST ligament tension (Fig. 2.22), combined with contraction of specific muscles that cross the right SI joint (e.g. piriformis, gluteus maximus and iliacus), has the overall effect of stabilizing the right SI joint in preparation for heel-strike and weight-bearing on that side (Figs 2.32, 2.46, 2.62).

KINETIC FUNCTION AND STABILITY

The ability of the SI joints to transfer weight and to absorb shock is closely linked to the proper functioning of the hip joints and the spine, in particular

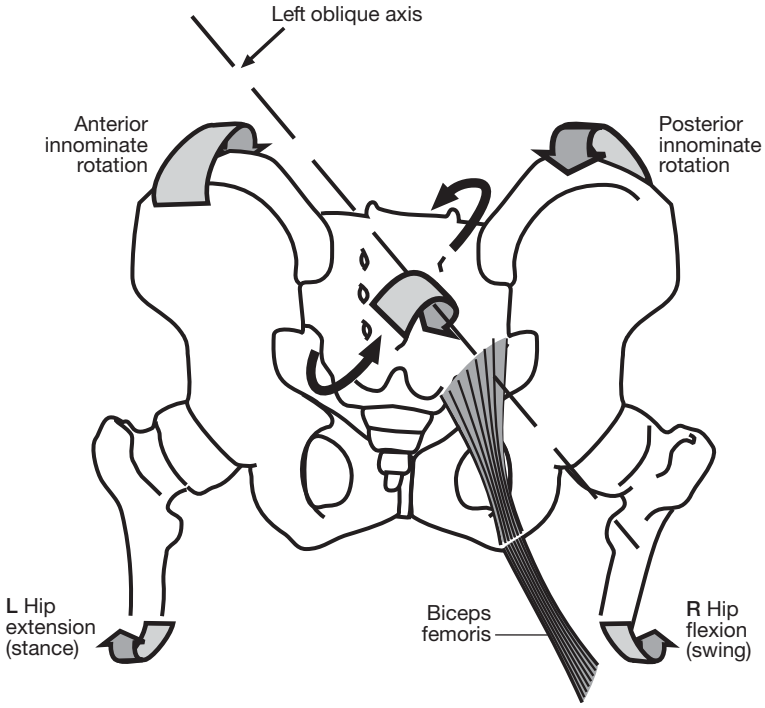

Fig. 2.21 Gait: right swing, left stance phase with 'right posterior, left anterior' innominate rotation, and sacral torsion around the left oblique axis. This results in increasing right SI joint stabilization, partly owing to increasing sacral nutation and a tightening of the right sacrotuberous, sacrospinous and interosseous ligaments, in preparation for heel-strike.

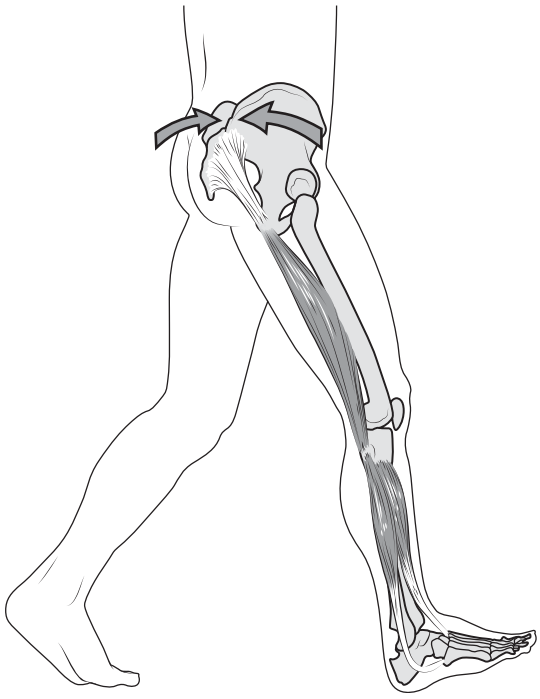

Fig. 2.22 At heel-strike, posterior rotation of the right innominate increases the tension in the right sacrotuberous ligament. Contraction of the biceps femoris further increases tension in this ligament, preparing the sacroiliac joint for impact. *(From Lee 2004a, redrawn courtesy of Vleeming et al. 1997.)*

the lumbar segment. Normal kinetic function involves all three regions simultaneously and depends on the availability of normal ranges of motion, appropriate muscle function and the ability to stabilize the various components adequately and in a coordinated manner. The following concepts are helpful in understanding the interaction between the pelvis, spine and lower extremities, in particular with regard to stability.

Panjabi: active, passive and neural control systems

Panjabi's conceptual model (1992a,b), originally intended to explain the stabilizing system of the spine, finds application 'to the entire musculoskeletal system' (Lee 1999), including the pelvic floor (Fig. 2.53) and is particularly helpful when trying to understand the factors that have a bearing on SI joint stability. Panjabi proposed the following interacting systems (Fig. 2.23):

1. the '*passive system*': the 'osteoarticular ligamentous' structures; that is, the support derived from the actual shape of the joint and from its capsule and ligaments
2. the '*active system*': the 'myofascial' or contractile tissues acting on the joint

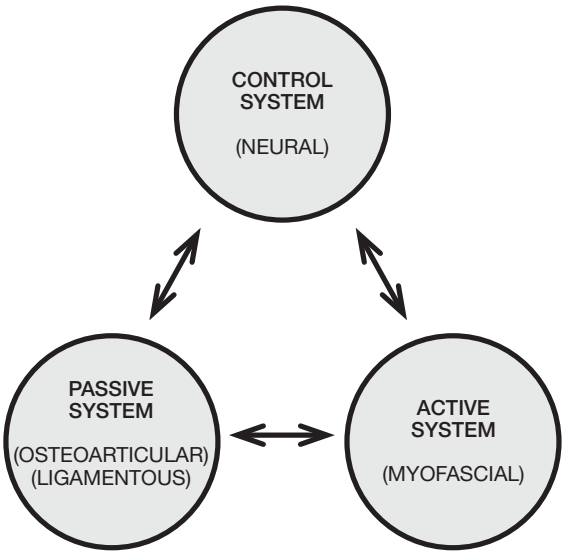

Fig. 2.23 Conceptual model by Panjabi illustrating the systems that interact to provide stability (see also Fig. 2.27). *(Redrawn courtesy of Panjabi 1992.)*

3. the '*control system*': the central and peripheral nervous systems that coordinate the interaction between the passive and active systems.

Normal interplay of these systems results in a small amount of displacement of the joint surfaces with minimal resistance, the so-called '*neutral zone*', and makes for stability (Fig. 2.24A). The neutral zone needs to be evaluated both quantitatively (the actual range of motion available - smaller or larger) and qualitatively (e.g. amount of resistance encountered on increasing or decreasing compression of the joint; Lee & Vleeming 1998, 2003); also, one must always do a side-to-side comparison of both factors. Injury to or degeneration of articulations and/or supporting ligaments (passive system), muscle weakness (active system) and incoordination or failure of muscle function (control system) can all result in instability, with abnormal displacement of the joint surfaces around an enlarged neutral zone (Fig. 2.24B).

Restriction of the 'neutral zone' may occur with:

1. contracture of the capsule and ligaments, with restriction of movement and stiffness of the joint (Fig. 2.24C)
2. active forces bringing the joint surfaces too close together, resulting in a so-called 'compressed' joint; for example, excessive tension in muscles acting on the joint (Fig. 2.24D)
3. excessive movement of the joint surfaces relative to each other to the point that they literally end up

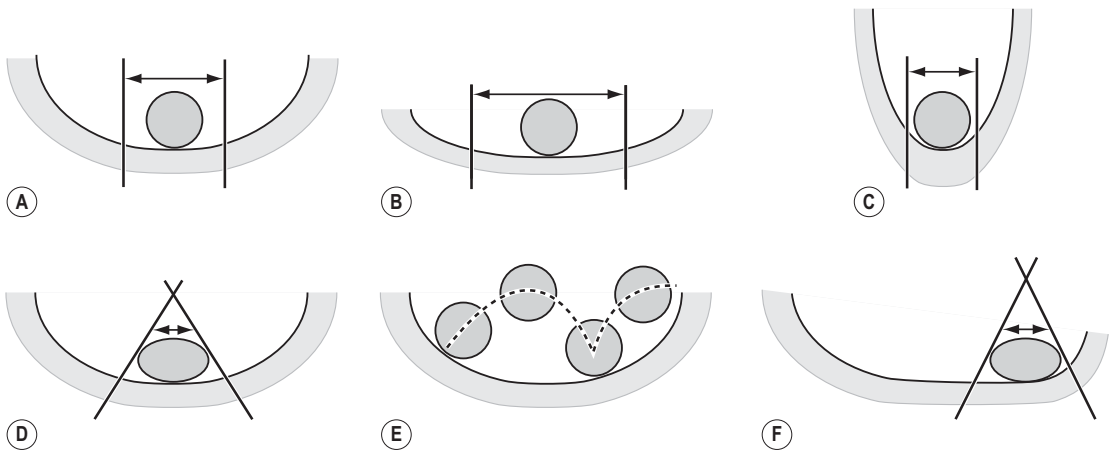

Fig. 2.24 The neutral zone can be affected by altering compression forces across the joint. (A) A graphic illustration of the neutral zone of motion in a hypothetically normal joint. (B) A joint which is insufficiently compressed due to the loss of either form or force closure will have a relative increase in the neutral zone of motion. (C) A joint which is excessively compressed due to fibrosis will have a relative decrease in the neutral zone of motion. (D) A joint which is excessively compressed due to overactivation of the global system will also have a relative decrease in the neutral zone of motion. (E) When there is an intermittent motor control deficit, *passive* motion within the neutral zone can be normal since the dysfunction is *dynamic*. The bouncing ball reflects the intermittent loss of compression during functional activities (dynamic instability). (F) A joint which is fixed (subluxed) is excessively compressed and no neutral zone of motion can be palpated (complete joint block). *(Courtesy of Lee 2004a.)*

getting 'stuck' in an abnormal position with the joint again 'compressed'; for example, subluxation of a joint, or excessive 'anterior' rotation of an innominate relative to the sacrum in the sagittal plane may actually result in 'joint compression' to the point of creating a so-called 'blocked' or 'locked' SI joint (Fig. 2.24F).

However, when a seemingly 'locked' joint is 'decompressed' by relaxing the muscles and/or manually moving the surfaces back into proper alignment, the neutral zone may now turn out to be enlarged because the capsule and ligaments were stretched initially when the excessive forward rotation occurred (e.g. a shear-force injury; Fig. 2.51B) or, subsequently, from being under increased tension as a result of the joint having been in this abnormal position for some time.

Failure of the control system can result in an aberrant movement of the surfaces relative to each other. A problem with control will become obvious with activity, when the muscles need to be activated or relaxed in proper sequence to carry out specific patterns of movement. On examination, passive movement within the neutral zone may be normal. However, active stabilization of the joint varies so that joint mobility is at times excessive, at other times normal, and sometimes inadequate as the appropriate distance between the joint surfaces is repeatedly lost and regained (Fig. 2.24E). In addition to the dynamic instability, chronic failure of the control system can eventually also result in passive instability as the joint surfaces deteriorate and the supporting capsule and ligaments are repeatedly stretched. The instability that results, for whatever reason, may present as a sudden 'giving way' of what is often mistakenly localized to the 'hip joint' but may actually be a manifestation of the 'slipping clutch' phenomenon which is discussed below and in Ch. 3 (Dorman 1994, 2001; Dorman et al. 1998; Vleeming et al. 1995a; Fig. 3.94).

'Self-locking' mechanism and 'form' and 'force' closure

The strong ligamentous support system that allows for proper SI joint function is, nevertheless, felt to be inadequate to prevent dislocation of the joints under postural load unless supplemented by other forces. This has led to the concept of a 'self-bracing' or 'self-locking' mechanism based on the fact that:

> *'In combination with load transfer through fascia, muscle forces that cross the SI-joints can produce joint compression. This [compression] counteracts mobility by friction and interlocking ridges and grooves'*
>
> (Snijders et al. 1993)

The terms 'form' and 'force' closure delineate the passive and active components of this self-locking mechanism, respectively (Snijders et al. 1993a,b, 1995a,b); Vleeming et al. 1990a, 1990b, 1997):

> *Shear in the SI-joints is prevented by the combination of specific anatomical features (form closure) and the compression generated by muscles and ligaments that can be accommodated to the specific loading situation (force closure) . . . If the sacrum would fit the pelvis with perfect form closure, no lateral forces would be needed. However, such a construction would make mobility practically impossible.*
>
> (Vleeming et al. 1995a)

In other words, 'form closure' refers to the stability provided by the joint structure itself and the capsular and ligamentous support; whereas 'force closure' refers to the any additional forces provided by muscles and myofascial structures on demand to ensure the stability of that joint for particular activities carried out under variable conditions (Figs 2.25, 2.26).

Because 'joint mechanics can be influenced by multiple factors. . .and that management requires attention to all', Lee & Vleeming (2003) proposed the 'dynamic' 'integrated model of function' that one should always consider on assessment and treatment in any attempt to achieve and maintain joint stability that is adequate for load transfer (Fig. 2.27). The model has the following four components:

1. form closure (structure, joint congruency)
   - depends on 'optimal function of the bones, joints and ligaments' (Vleeming et al. 1990a,b; Vleeming & Stoeckart 2007)
2. force closure
   - forces produced by myofascial action and, therefore, dependent on optimal function of the muscles and fascia (Vleeming et al. 1995b, Vleeming & Stoeckart 2007; Richardson et al. 1999, 2002; O'Sullivan et al. 2002; Hungerford 2002; van Wingerden et al. 2004)
3. motor control
   - specific timing of muscle action and inaction during loading (Hodges 1997, 2003; Hodges & Richardson 1997; Hodges & Gandevia 2000a; Hungerford et al. 2003)

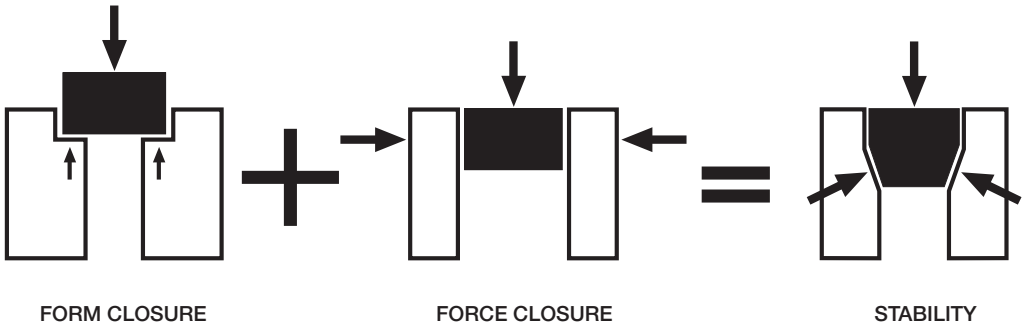

Fig. 2.25 Model of the self-locking mechanism: the combination of form and force closure establishes stability in the sacroiliac joint. *(Redrawn courtesy of Vleeming et al. 1997.)*

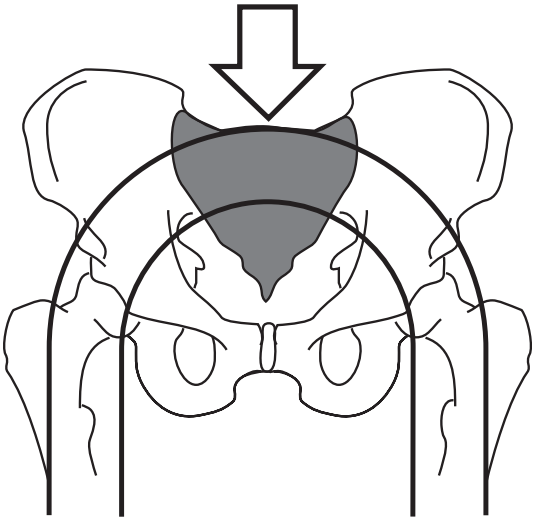

Fig. 2.26 'Form' closure: minimizing sacroiliac joint shear through the 'keystone in a Roman arch' effect, with the sacrum being 'trapped' vertically. *(Redrawn courtesy of Dorman & Ravin 1991.)*

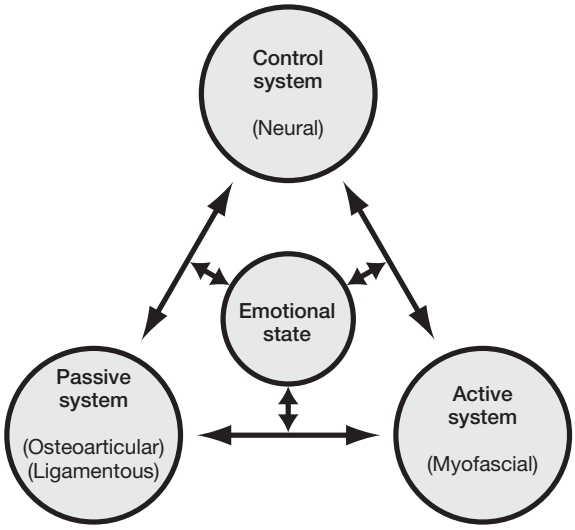

Fig. 2.27 Redrawing of Panjabi's model (see Fig. 2.23), to emphasize current acknowledgement of the interaction of psychological factors with the passive, active and control systems.

4. emotion

Psychological factors can affect form, force and neuromotor control unfavourably (Vlaeyen et al. 2000, 2007). The problem is discussed further in Ch. 4 under 'Psychiatry and psychology', to improve awareness of how emotional factors:

a. can play a role in causing musculoskeletal problems like the 'malalignment syndrome', or
b. may actually be a complication of such musculoskeletal problems.

Typical features in regards to emotional factors, cited by Lee and Vleeming (2007), include:

1. 'chronic pelvic or back pain', a history of 'traumatized life experiences', adopting motor patterns 'indicative of defensive posturing which suggests a negative past experience, [sustained] fight and flight reactions influencing basic muscle tone and patterning'
2. persistent increase in muscle tension resulting in increased levels of adrenaline (epinephrine) and cortisole which help perpetuate this vicious cycle (Holstege et al. 1996)
3. hypertonicity of pelvic muscles which can cause compression of the SI joints (Richardson et al. 2002; van Wingerden et al. 2001, 2004)

Treatment should include:

1. explaining the problem, time factors; restoring hope through education and awareness of the

underlying mechanical problem (Butler & Moseley 2003; Hodges & Moseley 2003)
2. 'professional cognitive-behavioural therapy…to retrain more positive thought patterns'
3. teaching individuals to become 'mindful' or aware of what is happening in their body whenever it is subjected to the effect(s) of physical and/or emotional loading, so as to reduce 'sustained, unnecessary muscle tone and therefore joint compression' (Murphy 1992)

Sacroiliac joint 'form' and 'force' closure

As concerns the lumbo-pelvic-hip region, 'a primary function is to transfer the loads generated by body weight and gravity during standing, walking and sitting' (Snijders et al. 1993a). In turn, how well this load is managed dictates how efficient function will be. Just the right amount of stability required for any effective load transfer is achieved when the passive, active and control systems work together (Panjabi 1992a,b). These systems produce approximation of the joint surfaces - the amount required is variable and depends on the individual's structure (form closure) and the forces needed for control (force closure). The term 'adequate' has been used, 'just enough to suit the existing situation' (Lee & Vleeming 1998, 2007). Too much force would result in 'stiffness' of the joint, impaired movement, or even inability to move at all; too little, in instability of the joint which, in turn, may result in a 'loose', unstable, or even totally uncontrolled motion.

'Local' and 'global' motor systems

Force closure and motor control depend on the adequate functioning of the muscles and the neural control. Increasingly sophisticated research has shown that any physical action can be divided into two phases: a preparatory phase which helps stabilize a particular part of the body and, in turn, allows the proposed action itself to be carried out safely and efficiently. Bergmark in 1989 suggested classifying muscles into two categories: a 'local' and a 'global' system. These are now commonly referred to as the 'inner' and 'outer' core muscles. When throwing a ball, for example, there are actually three phases to the muscle action:

1st Phase: the 'local system' or 'inner core' muscle contraction, to achieve segmental stabilization (Figs 2.28, 2.29)

1. involves the thoracic diaphragm, transversus abdominis, the pelvic floor muscles and deep fibres of [the lumbosacral] multifidi

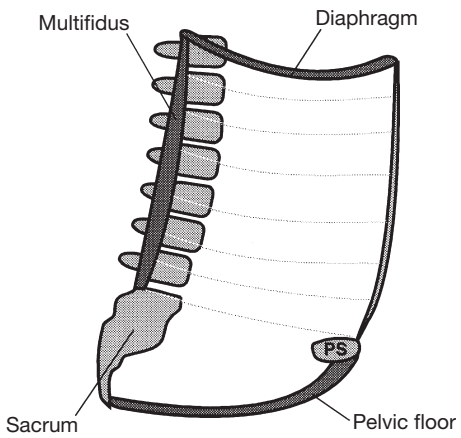

Fig. 2.28 The muscles of the 'inner core' unit include the multifidus, transversus abdominis (light lines), thoracic diaphragm and pelvic floor muscles. PS, pubic symphysis. *(Courtesy of Lee 1999.)*

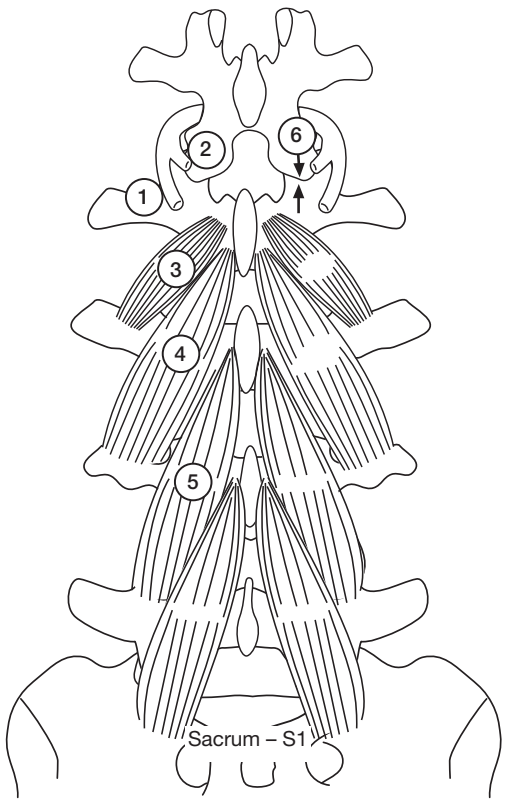

1. Posterior primary n. 2. Articular branch
3. Rotatores brevis 4. Rotatores longus
5. Multifidus 6. Facet joint

Fig. 2.29 Posterior elements of the lumbosacral spine.

2. ongoing research continues to identify other muscles that probably belong to this 'inner core' group (Lee 2004a): deep (medial) psoas (Gibbons et al. 2002), medial quadratus lumborum (Bergmark 1989; McGill 2002), lumbar part of iliocostalis and longissimus (Bergmark 1989), posterior part of internal oblique
3. achieves primarily 'intrapelvic', also segmental, stabilization (particularly with the multifidi acting on the lumbar spine) in preparation for carrying out this action
4. apparently is not direction dependent (Hodges 1997, 2003; Hodges & Richardson 1997; Hodges et al. 1999; Moseley et al. 2002, 2003)

2nd Phase: the 'global system' or 'outer core' muscle contraction to achieve regional stabilization (Figs 2.30–2.40)

1. involves contraction of muscles running from thorax to pelvis and pelvis to a lower extremity
2. achieves stabilization of thorax, pelvis and hip girdle and may be involved in initiating the actual motion (Lee 2004a; Lee et al. 2009, 2010)
3. contraction starts after that of the 'inner core' has been initiated; it is direction-dependent (Radebold et al. 2000, 2001; Hodges 2003)

3rd Phase: contraction of the peripheral muscles to carry out the action of throwing the ball

1. involves muscles in the upper and lower extremities, trunk and pelvis
2. given adequate stabilization has been achieved by the 1st and 2nd phase, this is the final phase of an action that involves considerable side-flexion to alternate sides, trunk rotation, torquing while transferring weight from one leg to the other (e.g. right-to-left with a right hand throw) as well as co-ordinated contraction of peripheral muscle and timing of release.

The end-result of this three-phase sequence is an action that:

1. can be carried out safely and efficiently on a stable base, given that stability of the pelvis and trunk has been established by contraction of 'inner' and then 'outer' core muscles in anticipation of the action
2. results in throwing the ball the distance required by correctly matching speed and the angle of release.

Throwing events will be discussed further in Chapters 3 and 5 (Figs 3.51, 5.30, 5.31).

Sacroiliac joint 'form' closure

In the case of the SI joint, form closure is derived from the following:

1. The triangular shape of the sacrum makes it fit between the innominates 'like a keystone in a Roman arch' (Dorman and Ravin 1991). The two ends of the arch are firmly connected by the sacrotuberous and sacrospinalis ligaments, so that the relatively flat SI joint surfaces are loaded only with compression and shear is minimized (Fig. 2.26).
2. The interlocking of the complementary articular surfaces of the sacrum and innominates helps to counter vertical and anteroposterior translation (Figs 2.2, 2.3).
3. The anterior widening of the sacrum restricts movement between the innominates by causing wedging in an anterior-to-posterior direction, thereby restricting counternutation (Figs 2.4B, 2.10A, 2.11A, 2.46B,D).
4. The increasing joint friction coefficient detected with advancing age as a result of:
   a. the formation of the interlocking ridges and grooves (Fig. 2.7B)
   b. roughening of the joint surfaces, which usually starts with the deterioration of the fibrocartilagenous cover of the iliac surface.
5. The ligaments that influence the SI joint and literally 'suspend' the sacrum between the innominates when a person is standing: the SI joint ligaments (anterior and posterior, interosseus and long dorsal) and the pelvic floor ligaments (Figs 2.4, 2.5, 2.13Aiii, 2.19, 2.52A, 2.53, 2.59, 3.64-3.66, 3.68).

Sacroiliac joint 'force' closure

SI joint force closure is achieved by two means.

First, there may be an active force that results in nutation of the sacrum (Figs 2.11A, 2.18C, 2.19A, 2.22, 2.31, 2.59). Nutation comes about either by anterior rotation of the sacral base (e.g. contraction of multifidi, extensor spinae or sacrospinalis) or posterior rotation of the innominates (e.g. contraction of rectus abdominis, biceps femoris or gluteal muscles). Nutation results in a tightening of the interosseous, sacrotuberous and sacrospinous ligaments (Fig. 2.19A). This tightening appears to facilitate the force closure mechanism, thereby increasing the compression of the SI joint articular surfaces which, in turn, increases the stability of the joint in preparation for load transfer (Vleeming et al.

1997). Conversely, counternutation, by decreasing tension in these same ligaments, decreases SI joint stability (Fig. 2.19B).

Second, force closure arises from the contraction of the 'inner' and 'outer' myofascial units, or 'core' muscles (see above). These units help to stabilize not only the pelvis but also the lumbar spine and hip joints, or 'lumbo-pelvic-hip complex'.

The 'inner core' or unit

The 'inner core' (Fig. 2.28) consists primarily of the deep fibres of multifidi, thoracic diaphragm, transversus abdominis and pelvic floor muscles.

1. Work by Sanford et al. (1997), using fine-wire electromyography, suggested that the contraction of specific abdominal muscles was coupled with the contraction of specific pelvic floor muscles (e.g. the co-contraction of transversus abdominis with pubococcygeus, the oblique abdominals with ilio/ischiococcygeus, and rectus abdominis with puborectalis).
2. This 'inner core' may be able to set up a force couple capable of affecting the stability of the SI joint and lumbosacral junction. For example, the multifidi originating from the lower lumbar vertebrae insert into the upper sacrum (Fig. 2.29), and ilio- and ischiococcygeus insert into the coccyx (Fig. 2.53). Contraction of the multifidi causes sacral nutation; contraction of ilio- and ischiococcygeus, counternutation. A change in these two forces that favours one group compared to the other could move the sacrum into a stable or unstable position, repectively.
3. Transversus abdominis contraction appears to occur in preparation for carrying out an action (Richardson et al. 1999) by:
   a. the co-activation of pubococcygeus; that is, part of the pelvic floor
   b. the force closure of the anterior aspect of the SI joints (Fig. 2.30); simultaneous compression of that part of the joint caused by inward movement of the innominates is resisted by the strong ligaments running across the back of the SI joint on that side (Snijders et al. 1995b)
   c. lateral traction forces by way of insertions into the thoracolumbar fascia posteriorly and abdominal fascia anteriorly (Porterfield & DeRosa 1998; Fig. 2.31A,B) and forces that act on the ilia anteriorly (Richardson et al. 2002), including the external and internal oblique (Figs 2.32 and 2.33, respectively); these forces, in turn:
      i. increase the intra-abdominal pressure, believed to contribute to lumbar spine stability (Aspden 1987; Barker & Briggs 1999)
      ii. increase tension within the thoracolumbar fascia, stabilizing the fascia and thereby making it more effective in its role as part of the 'outer unit'; in particular, as part of the posterior oblique and deep longitudinal systems, discussed below.
4. Contraction of superficial lumbar multifidi extends the lumbar spine as they create a lever arm by way of their attachments to the spinous processes. In contrast, contraction of the deep fibres of the lumbar multifidi, which lie next to the body of the lumbar vertebrae, actually compress these vertebrae. Also, contraction makes the deep muscle broaden and swell between the sacrum and overlying thoracodorsal fascia (Fig. 2.34); this has been likened to 'pumping up' the fascia, increasing tension in the fascia particularly in the thoracolumbar region 'by virtue of. . . broadening effect of the muscle as it contracts' (Gracovetsky 1990; Vleeming et al. 1995a; Lee 2004a; DeRosa & Porterfield 2007). Using Doppler imaging, Richardson et al. (2002) were able to show that simultaneous contraction of deep multifidi and transversus abdominis now anchored to a tighter thoracodorsal fascia, increased 'stiffness' of the SI joints. Clinically, the effect would appear to be a stabilization of the pelvic ring of bones, similar to that achieved with a sacroiliac belt. Also, contraction of the deep

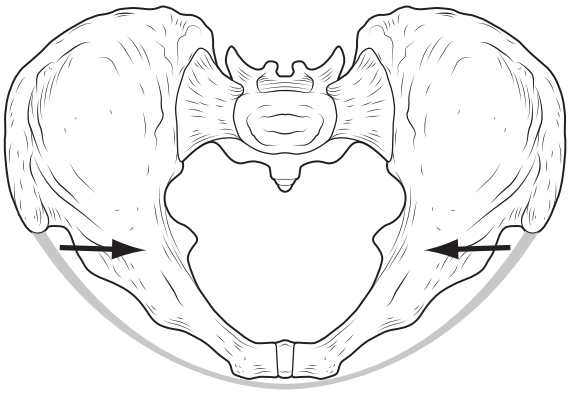

Fig. 2.30 Contraction of the transversus abdominis is proposed to produce a force which acts on the ilia perpendicular to the sagittal plane (i.e. approximates the ilia anteriorly: arrows). *(Courtesy of © Diane G. Lee Physiotherapy Corp.)*

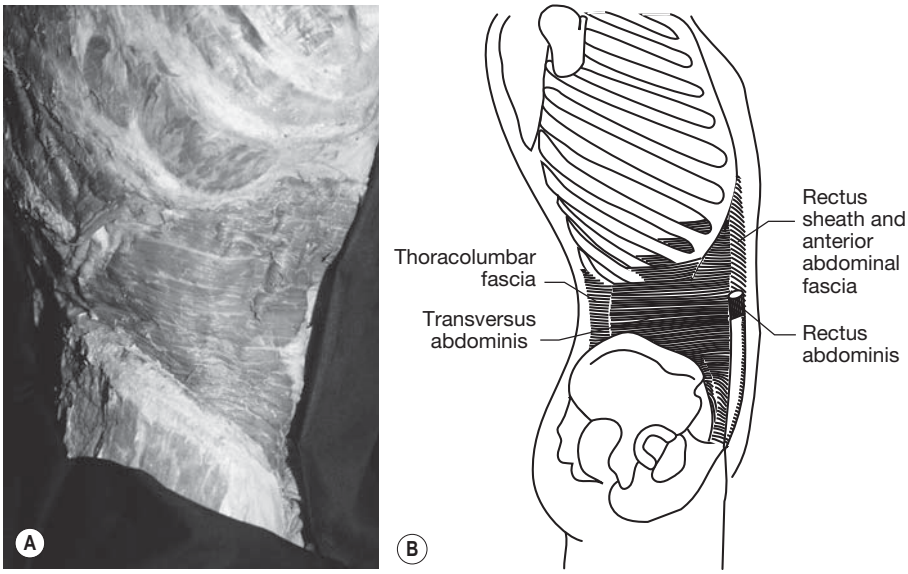

Fig. 2.31 (A) The transversus abdominis is attached posteriorly to the thoracolumbar fascia and anteriorly to the abdominal fascia. Note that it has an optimal muscle fibre orientation to pull posteriorly on the abdominal fascia, complementing the more angled forces on the fascia exerted by the external and internal abdominal oblique muscles. *(Courtesy of Porterfield & DeRosa 1998: 92.)* (B) Muscles that are part of the 'inner' (transversus abdominis) and 'outer' core (rectus abdominis).

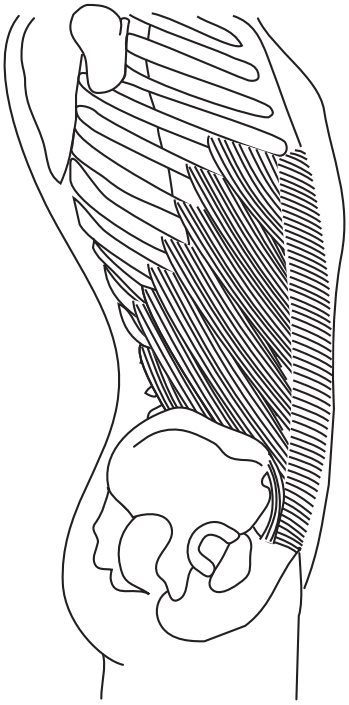

Fig. 2.32 Muscles that are part of the 'outer core' unit: External oblique.

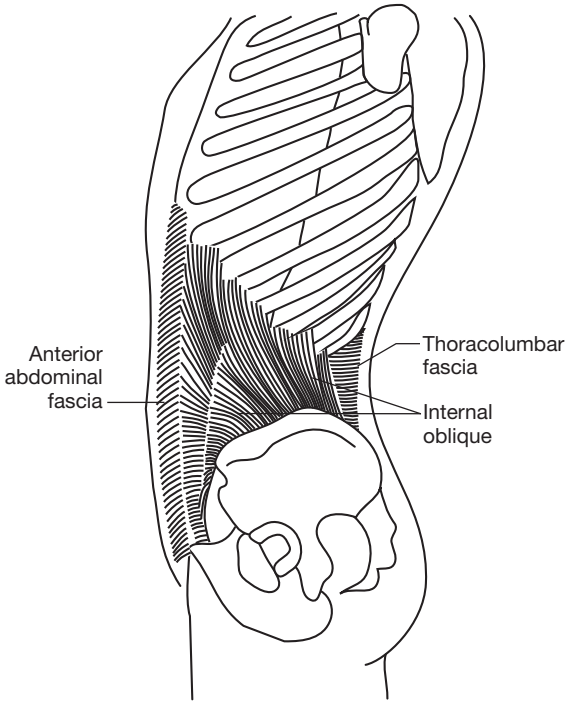

Figure 2.33 Muscles that are part of the 'outer core' unit. Internal oblique.

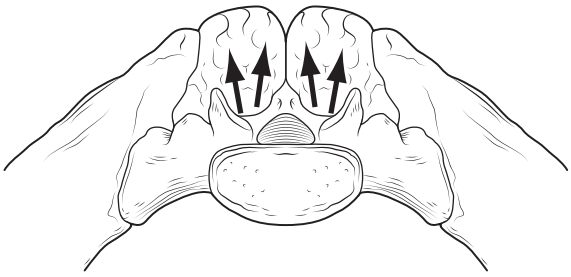

Fig. 2.34 When the deep fibres of the multifidi contract, the muscle can be felt to broaden or swell (represented by the arrows in the deep layers of the muscle). This hydraulic amplifying mechanism (proposed by Gracovetsky 1990) 'pumps up' the thoracolumbar fascia much like a balloon (Vleeming et al. 1995a) *(Courtesy of the © Diane G Lee Physiotherapy Corp.)*

multifidi has been observed to occur just prior to use of the upper extremities 'when the load is predictable' (e.g. throwing a ball) in order to stabilize the lumbar spine in anticipation of carrying out that action (Moseley et al. 2002; Hodges & Cholewicki 2007).

Uni- or bilateral segmental atrophy of multifidi visualized using Real-Time ultrasound (RTUS) and other dynamic techniques has been described in association with chronic back pain, failure to activate multifidi in proper sequence or not at all. RTUS is helpful in that it allows for instant feedback with selective muscle strengthening and activation (see Chs 4, 7).

The 'outer core' or unit

The 'outer core' is made up of the *oblique, longitudinal and lateral systems* of 'slings' of interconnecting muscles, tendons, ligaments and fascia. While contraction of an individual muscle may exert a force on a specific joint, if that muscle is part of one or more of these slings it can also:

1. exert a force on a distant site
2. increase stiffness of the SI joint by compressing the surfaces, even though the muscle does not itself cross the joint (van Wingerden et al. 2001; Lee 2004a; DeRosa & Porterfield 2007).

The four basic sling systems of the 'outer' unit

1. *the posterior (dorsal) oblique sling*

   The continuum of latissimus dorsi connected, by way of the thoracolumbar fascia, to the contralateral gluteus maximus constitutes the upper part of this system (Fig. 2.35) which will, on contraction:

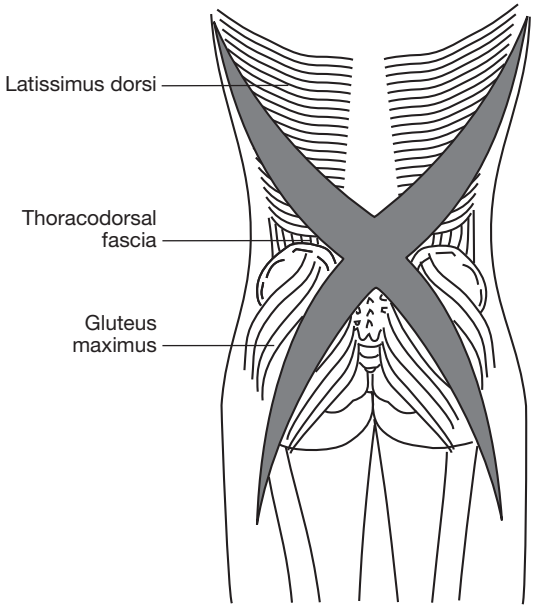

Fig. 2.35 The oblique systems of the 'outer unit'. Posterior oblique system. *(From Lee 1999, as redrawn courtesy of Snijders et al. 1995.)*

   a. compress the SI joint on the side of gluteus maximus, improving SI joint ability to attenuate shear loads (Porterfield and DeRosa 1998; Vleeming et al. 1990a,b)
   b. stiffen the lumbar spine 'over multiple spinal segments. . .minimizing translatory motion between the lumbar vertebrae' (DeRosa and Porterfield 2007)
   c. contribute to load transfer through the pelvic region with rotational activities (Mooney et al. 1997) and during gait (Gracovetsky 1997; Greenman 1997; Fig. 2.41)

   The lower part of this system is comprised of the continuations of gluteus maximus that act to tense the ITB. Concomitant contraction of TFL and vastus lateralis further increase tension in ITB which helps stabilize the knee during the 'single support' or stance phase (Fig. 2.36A)

2. *the deep longitudinal sling*

   This sling was initially described as the continuum of the ipsilateral erector spinae muscle and contralateral iliocostalis connected, by way of the deep lamina of the thoracodorsal fascia, to the contralateral sacrotuberous ligament and biceps femoris (Gracovetsky 1997; Vleeming et al. 1997; Lee 2004a; Figs 2.37, 2.38A).

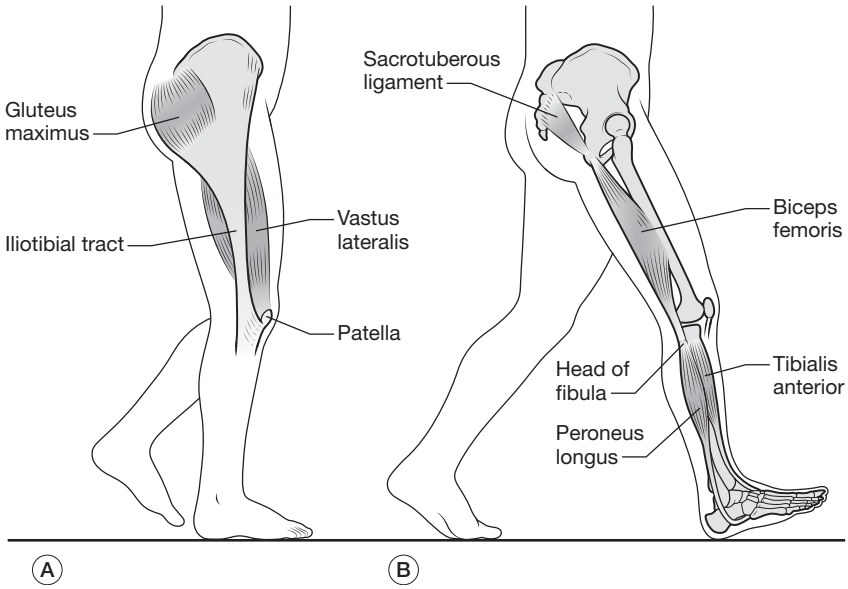

Fig. 2.36 (A) Lower part of the oblique dorsal muscle-fascia-tendon sling. Relationship between gluteus maximus muscle, iliotibial tract, vastus lateralis muscle and knee in the single support phase. The iliotibial tract can be tensed by action of the dorsally located gluteus maximus and ventrolaterally located tensor fascia lata muscle. The tract can also be tensed by contraction of the vastus lateralis muscle. (B) The longitudinal-tendon-fascia sling. Relations at the end of the swing phase. *(Courtesy of Vleeming & Stoeckart 2007.)*

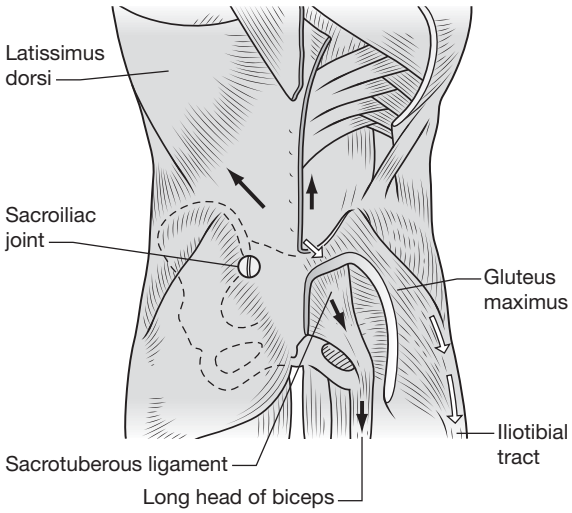

Fig. 2.37 Schematic dorsal view of the low back. The right side shows a part of the longitudinal muscle-tendon-fascia sling. Below this is the continuation between biceps femoris tendon and sacrotuberous ligament, above this is the continuation of the erector spinae. To show the right erector spinae, a part of the thoracolumbar fascia has been removed. The left side shows the sacroiliac joint and the cranial part of the oblique dorsal muscle-fascia-tendon sling, latissimus dorsi muscle and thoracolumbar fascia. In this drawing the left side of the thoracolumbar fascia is tensed by the left latissimus dorsi and the right gluteus maximus muscle. *(Courtesy of Vleeming & Stoeckart 2007.)*

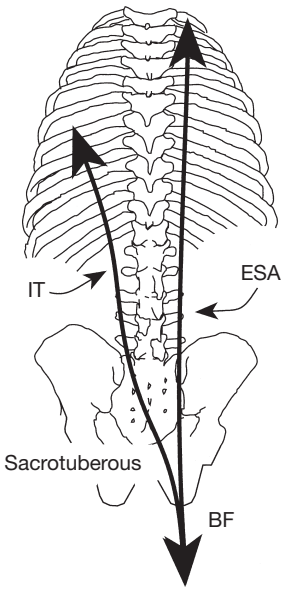

Figure 2.38 Deep longitudinal system of the 'outer' unit: the biceps femoris (BF) is directly connected to the upper trunk via the sacrotuberous ligament, the erectores spinae aponeurosis (ESA) and iliocostalis thoracis (IT). *(Courtesy of Gracovetsky 1997.)*

It is now felt to include peroneus longus and probably also tibialis anterior, both of which have been shown to contract in preparation for heel-strike (Fig. 2.36B). The effect of activating this 'deep longitudinal system' is to:

a. compress the SI joint because of biceps femoris connections and the increase in tension on the sacrotuberous ligament (van Wingerden et al. 1993)
b. increase tension in the thoracodorsal fascia and, thereby, enhance the ability of the fascia to contribute to any SI joint force closure mechanisms acting across it
c. decrease downward movement of the fibula by way of contraction of biceps femoris which inserts into the head of the fibula
d. probably help support the longitudinal arch of the foot by tightening the sling formed by peroneus longus and tibialis anterior (both of which insert into the medial cuneiform and the base of the 1st metatarsal.

3. *the anterior oblique sling*

The external obliques on one side are connected, by way of the anterior abdominal fascia, to the contralateral internal abdominal obliques and adductors of the thigh (Fig. 2.39A). The lower horizontal fibres of the internal abdominal oblique may augment transversus abdominis in its role of supporting the SI joint (Richardson et al. 1999). Posteriorly, the internal oblique attaches to the upper and the external oblique to the lower part of the thoracolumber fascia, allowing them to exert a stabilizing effect on the upper and lower part of the lumbar spine, respectively; whereas the more extensive transversus abdominis attachments can affect the length of the lumbar segment (Barker & Briggs 2004). Interaction of the anterior shoulder girdle muscle groups has been well delineated by DeRosa and Porterfield (Fig. 2.39B).

4. *the lateral sling*

This sling is comprised of the lateral stabilizers of the thoracopelvic region (e.g. quadratus lumborum) and the primary stabilizers of the hip, namely gluteus medius and minimus (G. med/min), tensor fascia lata and the contralateral adductors of the thigh (Fig. 2.40). The gluteus medius and minimus are more involved with stabilizing the pelvic girdle at the hip joint rather than with SI joint force closure,

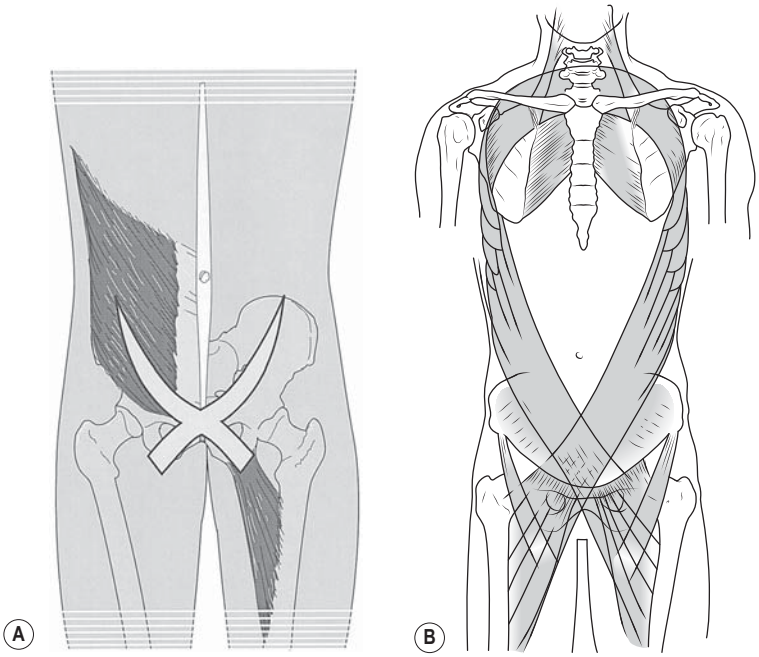

Fig. 2.39 (A) Anterior oblique system. *(Courtesy of Lee 1999.)* (B) Muscle sling of the shoulder girdle and the abdominal mechanism. The muscle fibre line of the rhomboids is continuous with the line of pull of the serratus anterior. The serratus anterior interdigitates and is often fused with the external abdominal oblique, which has a muscle fibre line of force in parallel with the internal abdominal oblique on the opposite side of the body. *(Courtesy of Porterfield & DeRosa 2004.)*

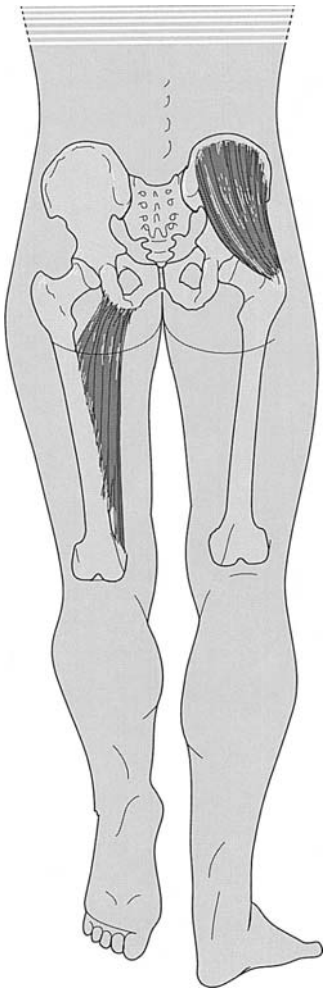

Fig. 2.40 The lateral system of the outer unit includes: lateral stabilizers of the hip (gluteus medius and minimus) and the tensor fascia lata (not shown), the contralateral adductors of the thigh, and the lateral stabilizers of the thoracopelvic region (e.g. quadratus lumborum). *(Courtesy of Lee 1999.)*

acting in particular to stabilize the femoral head in the acetabulum just prior to heel strike and throughout single-leg stance (Gottschalk et al. 1989). SI joint instability, however, is thought to possibly result in a reflex inhibition of these muscles which could be one mechanism to account for the feeling of the hip 'giving away', or 'slipping clutch syndrome' (Dorman 1994, 1995, 2001; Dorman et al. 1998; Vleeming et al. 1995a; Fig. 3.94)

The four basic 'sling systems' described are also interlinked and part of larger systems that allow for controlled load transfer and mobility, ensure balance and stability and also help to absorb shock. Contraction of the obliques may actually initiate movement, provided that the trunk has been stabilized by prior contraction of transversus abdominis (Richardson & Jull 1995; Hodges & Richardson 1996).

Force closure of the SI joints will suffer as a result of problems within the active system and/or the control system:

1. actual muscle weakness; atrophy
2. the inadequate recruitment of muscles in one or several interacting slings, which can also result in weakness affecting a whole system
3. uncoordinated contraction and relaxation of these local and global systems, resulting in failure to provide adequate stability and consistent control of motion (Hodges & Gandevia 2000b; Hodges 2003; Hodges & Cholewicki 2007)

The movement patterns that a patient starts to use in order to compensate for these insufficiencies - weakness, impaired muscle tension and control - results in abnormal stresses on the musculoskeletal system and may lead to an 'eventual decompensation of the low back, pelvis, hip and knee joints' (Lee 1997), including earlier, more rapidly progressing and more marked degenerative changes, ligament laxity and joint instability (see Fig. 3.82).

Given that the problem involves not isolated muscles but these well-defined interacting slings, Lee (2004a) has provided an excellent summary of the overall role of the core muscles and the slings:

> *'In conclusion, when the local system is functioning optimally, it provides anticipatory intersegmental stiffness of the joints of the lumbar spine (Hodges et al. 2003) and pelvis (Richardson et al. 2002). This external force (force closure) augments the form closure (shape of the joint) and helps prevent excessive shearing at the time of loading. This stiffness/compression occurs prior to the onset of any movement and prepares the low back and pelvis for additional loading from the global system. Simultaneously, the diaphragm maintains respiration while the pelvic floor assists in maintaining the position of the pelvic organs (continence) as load is transferred through the pelvis'.*

Treatment now emphasizes working on the 'local' and 'global' system as a whole in trying to re-establish strength, coordinated activation of contraction, and neural control (Richardson et al. 1999, Lee 2004a, 2007, Lee & Vleeming 2003).

Functional evaluation of 'form' and 'force' closure

There are a number of functional tests for the evaluation of form and force closure that are coming into common usage in clinical practice, both to help one arrive at a proper diagnosis and to determine the appropriate treatment. These are discussed under 'Functional or dynamic tests' below.

Sacroiliac joint function during the gait cycle

Right swing phase

The right SI joint becomes progressively more stable in preparation for weight-bearing, as a result of:

1. rotation of the sacrum around the left oblique axis, so that the right sacral base drops forward and down into nutation, while the apex rotates backward and to the left (Fig. 2.21); the rotation is initiated by the contraction of left piriformis and gluteus maximus, key stabilizers of the oblique axes, during the left stance phase
2. rotation of the right innominate posteriorly relative to the sacrum (Fig. 2.22)

Both of these actions result in increasing nutation of the right SI joint, with a passive increase in tension in the sacrotuberous, sacrospinous and interosseous ligaments (form closure). At the same time, tension in the 'posterior oblique' sling is increased both:

1. actively, with contraction of the right gluteus maximus, and
2. passively, with the simultaneously swinging forward of the left arm and clockwise rotation of the trunk, stretching left latissimus dorsi and, through the thoracodorsal fascia connections, involving gluteus maximus and distal muscles of this sling (Figs 2.35, 2.36).

The right iliopsoas is already contracting to help swing the leg forward, at the same time acting across the right SI and hip joint (force closure). The onset of right hamstring contraction just before heel-strike further increases the tension in the sacrotuberous ligament, augmenting form closure. The combined effect is a compression of the right SI joint, increasing its stability and, hence, ability to deal with load transfer at heel-strike.

Right stance phase

During the late stance phase, gradual destabilization of the now weight-bearing right SI joint (in preparation for the next swing phase) is accomplished by:

1. the onset of counternutation of the right sacral base, as the sacrum begins to rotate around the right oblique axis with the left leg swinging forward (Figs 2.10B, 2.41)
2. anterior rotation of the right innominate bone relative to the sacrum, passively with hip extension and actively with contraction of the ipsilateral iliacus and rectus femoris (Fig. 2.59)
3. contraction of piriformis (one of the prime hip extensors).

Tension in the right sacrotuberous ligament decreases even further as the hamstrings gradually start to relax. Form closure of the right SI joint is, therefore, gradually lost during late stance phase, so that stability during this phase is provided primarily by force closure. Active contraction of the left latissimus dorsi and right gluteus increases tension in the thoracolumbar fascia that connects them (Fig. 2.35) and compresses the right SI joint; this contraction also starts to reverse the forward swing of the left arm and clockwise rotation of the trunk that had occurred during the right swing phase. Iliacus and rectus femoris act across the joint while helping the anterior rotation of the innominate. Once hip extension has been completed at the end of right stance, gluteus maximus and piriformis begin to relax, at which point sacral torsion around the right oblique axis can proceed unhindered to its maximum range in preparation for left heel-strike.

As the right leg begins to swing forward following toe-off, the sacrum again begins to rotate around the left oblique axis, and the cycle repeats itself. During a complete cycle, therefore:

1. the SI joints move reciprocally in a figure-of-8 pattern
2. there is need to control vertebral and pelvic unit motion in all six degrees of freedom, as well as translation/rotation of any segments of the pelvis relative to each other (Fig. 2.9)

The interaction between the spine, pelvic unit and hips during the gait cycle is further deliniated in Figure 2.41.

Ongoing research and clinical presentations continue to clarify SI joint anatomy, the forces normally acting on the joint especially during weight transfer and its role in the normal and abnormal function of the lumbo-pelvic-hip complex as a whole. The part that the joint plays in the pathological presentations of malalignment will be discussed throughout the following sections. However, granted that the SI joint is in a key position to influence the function of the spine, pelvis and legs, it cannot be stressed enough that it is but one part of a system of muscles and bones that are interconnected and can affect each other detrimentally especially when malalignment is present.

COMMON PRESENTATIONS OF PELVIC MALALIGNMENT

Studies have repeatedly shown malalignment of the pelvis to be present in 80 to 90% of high school graduates (see 'aetiology' below; Klein 1973). About one-third are asymptomatic, two-thirds symptomatic

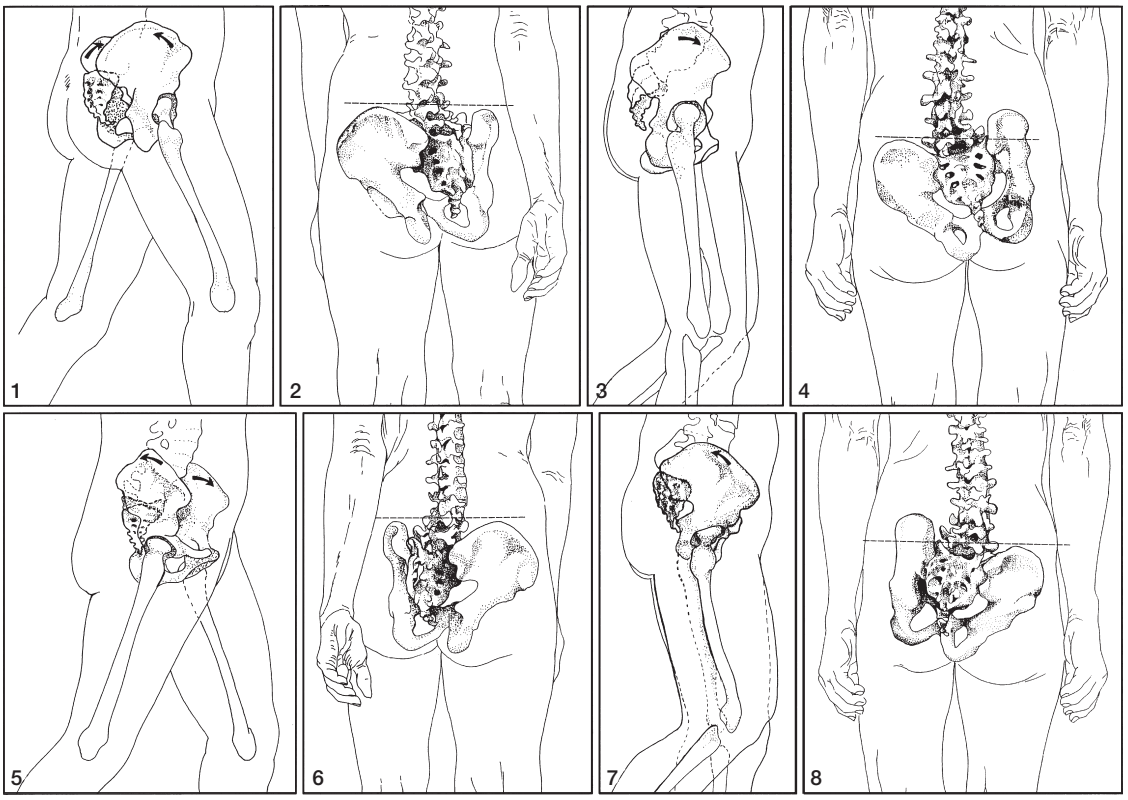

Fig. 2.41 Combined activities of right and left innominates, sacrum and spine during walking. ***At right heel strike***: 1. the right innominate has rotated in a posterior and the left innominate in an anterior direction; 2. the anterior surface of sacrum is rotated to left and superior surface is level, while the spine is straight but rotated to the left. ***At right midstance***: 3. the right leg is straight and the innominate is rotating anteriorly; 4. the sacrum has rotated to the right and side-bent left; whereas the lumbar spine has side-bent right and rotated left. ***At left heel strike***: 5. the left innominate begins rotation anteriorly; after toe-off, the right innominate begins rotation posteriorly; 6. Initially the sacrum is level but with the anterior surface rotated to right. The spine, although straight, is also rotated to right, as is the lower trunk. ***At left leg stance***: 7. the left innominate is high and the left leg straight; 8. the sacrum has rotated to the left and side-bent right, while the lumbar spine has side-bent left and rotated right. *(Courtesy of Greenman 1997.)*

(e.g. low back, leg or groin pain) with or without evidence of coincident facet or disc degeneration, root irritation or radiculopathy on investigation. Three common presentations account for some 90-95% of those found to be out of alignment. These presentations (with frequency noted in studies quoted in the text) are:

1. 'rotational malalignment' (80-85%)
2. pelvic 'flare' - innominate 'outflare'/'inflare' (40-50%), and the
3. 'upslip' (15-20%)

A presentation may appear in isolation or in combination with one or both of the others. For example, an 'upslip' appears on its own in about 10%, in combination with either 'rotational malalignment' or 'flare' or both in another 10%, for a total of 20% overall.

The following remarks should clarify some of the upcoming discussion:

1. ***'malalignment'***

   This refers to the abnormal biomechanical changes seen in conjunction with each of these three presentations; whereas
2. ***the 'malalignment syndrome'***

   The 'syndrome' refers to the clinical symptoms and signs that are typically associated with two of these presentations, namely: 'rotational malalignment' and an 'upslip'. It will be discussed in Ch. 3 and thereon.
3. ***'flare' presentations ('outflare'/'inflare')***

   These have their own distinct clinical features when seen in isolation but not those of a 'malalignment syndrome'. However, when seen in association with an 'upslip' and/or 'rotational malalignment', all the features of the 'malalignment syndrome' will also be present.

Discussion of the gait cycle above indicated how the innominates and sacrum normally move through a figure-of-8 pattern, from swing to stance phase and back again. The three presentations of malalignment suggest that the pelvic ring has seemingly become 'stuck' in one or a combination of the three patterns that the innominates normally move through relative to each other and to the sacrum with each gait cycle.

Looking at someone walking, with the right leg moving forward through 'swing', left leg through 'stance' phase (Fig. 2.41), these patterns are:

1. counterclockwise rotation of the pelvic unit around the vertical axis in the transverse plane (Fig. 2.12), so that the innominate (ASIS/PSIS)
   - moves relatively forward on the side of the right leg and backward on the side of the weight-bearing left leg
   - may arrest, or get 'stuck', in this particular 'flare' combination, which would present as a 'right inflare, left outflare'.
2. 'posterior' rotation of the right, 'anterior' rotation of the left innominate around the coronal axis in the sagittal plane
   - arrest of movement would result in a 'rotational malalignment' presentation; in this case, in the 'right posterior, left anterior' pattern
3. clockwise rotation around the sagittal axis in the coronal (frontal) plane, so that the innominate (iliac crest) rises on the left (weight-bearing) side, falls on the right (non-weight-bearing) side
4. sacral rotation around an oblique axis, in this case the 'left-on-left' axis (Figs 2.21, 2.50)
   - 'fixation' in this pattern would see the sacrum 'frozen' in a position where the right sacral base has moved forward and down, the left inferior angle backward and up.

'ROTATIONAL MALALIGNMENT'

'Rotational malalignment' refers to fixation of an innominate bone relative to the sacrum in excessive anterior or posterior rotation in the sagittal plane. Such rotation can affect an innominate on one side only but is more likely to be seen in association with:

1. compensatory rotation of the contralateral innominate, with arrest in the opposite direction and failure to move on through the figure-of-8 pattern as it should during a normal walking cycle (Figs 2.10, 2.21, 2.41)
2. displacement of the pubic bones relative to each other (Figs 2.42, 2.76C,D, 3.86)

The overall effect is a completely asymmetrical distortion of the pelvic ring (Fig. 2.76). There may also be:

1. movement dysfunction, involving one or both SI joints
2. torsion of the sacrum, most often around one of the oblique axes

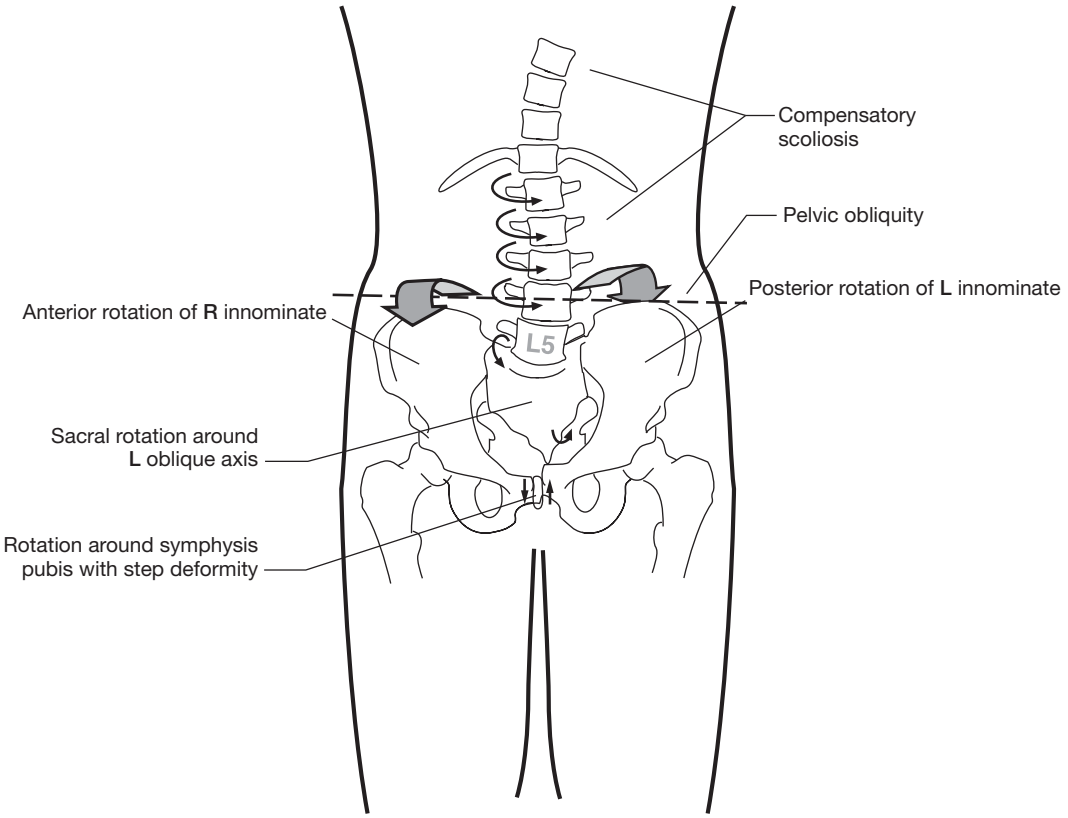

Fig. 2.42 Typical pelvic ring distortion associated with 'rotational malalignment': 'right anterior', compensatory 'left posterior' innominate rotation, as shown. Pubic bones are rotated and displaced at the symphysis; sacrum in torsion around the left oblique axis. Pelvic obliquity (here inclined to right) and compensatory scoliosis (lumbar segment here convex to left; L1–L4 rotated into convexity).

On passive examination, SI joint movement dysfunction may occur in the form of:

1. hypermobility, hypomobility, or actual 'locking', of one of the SI joints
2. compensatory hypermobility of the the SI joint contralateral to the one known to be hypomobile or 'locked' (Fig. 2.125)
3. instability of one or both SI joints attributable to muscle weakness or fatigue, ligament laxity, joint degeneration, impaired neural control or a combination of these

The most common pattern of 'rotational malalignment' is that of 'right anterior, left posterior' innominate rotation with 'locking' of the right SI joint

Examination findings typical of the 'most common' rotational patterns are detailed in Appendix 1.

Aetiology of 'rotational malalignment'

Individuals are sometimes able to recall a specific incident that seemed to have triggered their problem. They may blame a fall, a collision or a lifting, twisting or reaching incident. Females may date onset around the time of a pregnancy (see Ch. 4, 'Implications for . . . obstetrics') when they are especially vulnerable because of the increase in weight, ligament laxity attributed to increased relaxin hormone levels pre-partum and while breastfeeding, the mechanical and emotional stress of delivery and asymmetrical stresses incurred in caring for the infant (e.g. an unexpected torsional force lifting the baby from the crib or change-table at an angle).

There is, however, often no obvious history of trauma, raising the question whether 'rotational

malalignment' is really the result of some forgotten traumatic incident or is more likely a developmental phenomenon. The following are some of these other mechanisms that may have resulted in 'rotational malalignment'.

Developmental

Several studies have found a high percentage of children already presenting with asymmetries before reaching their teens. Pearson (1951, 1954), undertaking progressive standing radiological studies on 830 children from 8 to 13 years of age, found some degree of pelvic obliquity in 93%. Longitudinal studies by Klein and Buckley (1968) and Klein (1973) showed an increasing prevalence of asymmetry on going from elementary (75%) to junior (86%) to senior high school (92%). One might think that the an innominate fixed in 'anterior' or 'posterior' rotation may be the result of an accumulation of minor traumas and insults. However, as Fowler had already suggested in 1986 (810), the rotation is thought to be 'primarily the result of muscular imbalances which secondarily restrict sacroiliac joint motion', a clearly identified traumatic or mechanical stress being a less frequent cause. Perhaps the 'muscular imbalance' relates to a craniosacral problem (see Ch. 8), a C1–C2 instability or a prevalent one-sidedness in motor dominance. For example:

1. 70% of us are left, 15% right motor dominant. In other words, the combined total of some 85% showing 'asymmetric motor dominance' might correspond to that of the approximately 85% found to be out of alignment with one or more of the three most common presentations: 'rotational malalignment', 'flare' and/or an 'upslip'
2. 80-85% of these individuals whose pelvis is found to be out of alignment present with a 'rotational malalignment': approximately 75-80% of them with a 'right anterior, left posterior' innominate rotation and the remaining 5-10% with a 'left anterior, right posterior' rotation
3. the 70% who are left and 15% right motor dominant also matches the approximately 70% who are right, 15% who are left hand dominant.

One might speculate that:

1. the approximately 70% with left and 15% right motor dominance and/or the 70% with right and 15% left-sidedness correspond to the split of those with 'rotational malalignment' into 80-85% with 'right anterior/left posterior' and 5-10% with 'left anterior, right posterior' pattern, respectively
2. any one, or combination of two or all three presentations, can result in an asymmetry in muscle tension that predisposes to the occurrence and subsequent recurrence(s) of malalignment
3. this would leave approximately 10-15% with symmetrical motor dominance and symmetrical muscle tension, who are ambidextrous and present in alignment on examination.

However, studies on alignment, handedness and patterns of muscle tension to date have failed to bear out these speculations.

Combinations of bending, lifting, twisting and reaching

A particular traumatic incident or mechanical stress later in life may have made a pre-existing 'rotational malalignment' symptomatic rather than actually having caused that malalignment. A common mechanism involves bending forward and twisting the trunk to reach to either the right or left side. The intent may be simply to pick up a piece of paper from the floor (Fig. 2.43), or reaching above horizontal to a high shelf (Fig. 2.44). These movements often constitute an action of either extension or forward flexion combined with side-flexion and axial rotation of both the sacrum and the vertebrae. The onset of pain is usually acute, often felt on trying to get back to the upright position. Sometimes the pain comes on more gradually, over the next few hours or even days, which is more suggestive of injury to ligaments or tendons and the prolonged time required for inflammation to develop because of the relatively poor blood supply to these structures.

Stevens (1992) postulated how a strong activation of gluteus maximus and biceps femoris on the side opposite to the lateral bending, in conjunction with the asymmetrical loading of the spine and pelvis inherent to side-flexion while standing, may result in a side-to-side difference in the amount of anterior rotation that is possible in the SI joints on attempting this manoeuvre (Fig. 2.43). For example, on simultaneous reaching forward and bending to the right, anterior rotation in the SI joints is:

1. restricted on the contralateral (left) side with the increase in tension in the left sacrotuberous ligament, in part due to contraction of muscles that can be interlinked with this ligament; e.g. gluteus maximus, piriformis, biceps femoris and deep multifidi (Figs 2.6, 2.45)

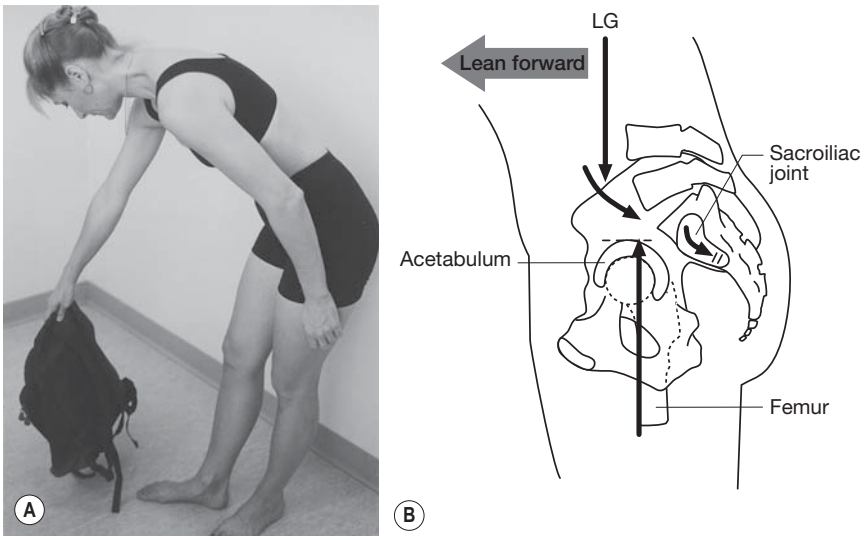

Fig. 2.43 A common way of causing a pre-existing asymptomatic 'rotational malalignment' to become symptomatic. (A) Simultaneously bending forward and twisting to the right or left (or returning back to neutral from that position), especially when attempting to lift or just hang on to a weight. (B) When the trunk leans forward, the line of gravity (LG) moves anteriorly, causing an anterior rotation of the pelvis around the acetabula; caudal gliding of the sacroiliac joint is impaired, relaxing the posterior pelvic ligaments and making the joint vulnerable. *(Redrawn courtesy of DonTigny 1990.)*

Fig. 2.44 Stocking shelves often requires simultaneous reaching and twisting which predisposes to recurrence of malalignment of the pelvis and spine and precipitation or aggravation of symptoms.

2. normal or possibly even increased on the ipsilateral side (Willard 1997)

DonTigny (1990, 2005) described how, on bending forward in standing, the weight of the trunk shifts the line of gravity anterior to the acetabula and 'the innominates tend to rotate anterior and downward around the acetabula and appear to limit caudal gliding [of the sacrum]' (1990: 483). In this position, the SI joints become vulnerable: the sacrum is counternutated, the posterior SI joint ligaments – with the exception of the long dorsal sacroiliac ligament - are now in a relaxed position, and the anterior ligaments never do offer much support at the best of times (Figs 2.4A, 2.5, 2.19):

> *Because the sacrum is placed within the innominates and is wider anteriorly, when the innominates move anteriorly and downward on the sacrum the innominates tend to spread on the sacrum. On reaching their limit of motion, they may wedge and become fixed in the anterior position. There is no problem when the spine and the innominates flex anteriorly at the same rate, or if the spine flexes prior to the innominates. Dysfunction occurs*

> *when the innominate bones rotate anteriorly prior to flexion of the spine, or if the innominates lag and the spine extends prior to posterior rotation of the innominates.*
> (DonTigny 1990: 485)

In both situations, the innominates rotate anteriorly and the sacrum into relative counternutation, making the SI joint unstable and vulnerable to displacement.

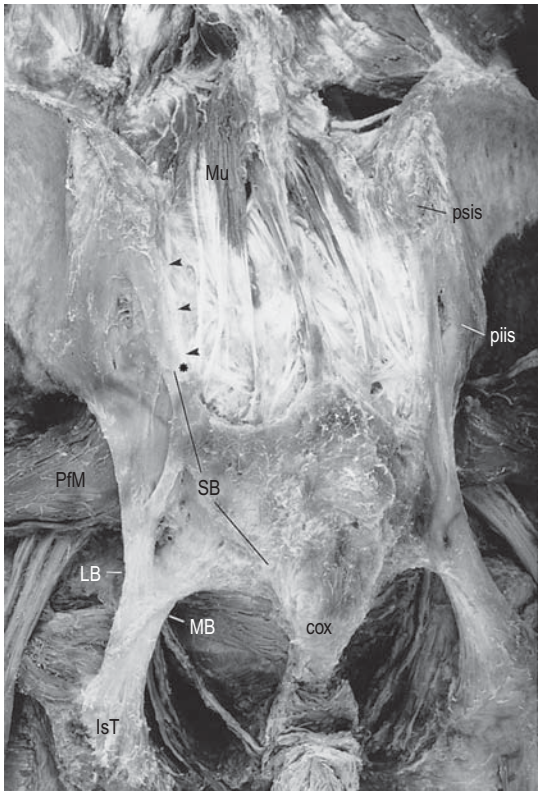

Fig. 2.45 Dorsal view of the male sacroiliac joint (SIJ) and sacrotuberous ligament. All but the deepest laminae of the multifidus muscle (Mu) have been removed. The sacrotuberous ligaments [are] seen stretching from the ischial tuberosity (IsT) to the coccyx (cox) medially and the posterior iliac spines superolaterally. . . . The arrowheads mark the course of the long posterior interosseous ligament under the lateral band of the sacrotuberous ligament. Three major bands of the ligament are seen: lateral (LB), medial (MB) and superior (SB). The lateral band spans the piriformis (PfM) to reach the ilium inferior to the (piis). As the lateral band climbs toward the (psis), it blends with the raphe. The medial band attaches to the coccyx and the superior band. . .[connects] the coccyx with the posterior ilial spines. Tendons of the multifidus pass between the superior band and the long dorsal SI ligament to insert into the body of the sacrotuberous ligament. *(Courtesy of Willard 2007.)*

Spasm occurring in specific muscles can also result in wedging of the bones of the pelvis in an abnormal position. For example, iliacus normally contracts to stabilize the SI joint in preparation for heel-strike and early weight-bearing phase; if it goes into spasm, it can cause the innominate on that side to become stuck in an 'anterior' rotated position relative to the sacrum (Figs 2.46B,C, 3.42). Iliacus would have the effect of rotating the innominate anteriorly and wedging it against the widening sacrum. Piriformis contraction actually rotates the sacrum posteriorly on that side, in effect pulling it against the innominate as the latter is attempting to rotate forward (Fig. 2.46A,C). However, as Grieve pointed out in 1988, and as indicated in the discussion in Chapter 3:

> *Sacroiliac sprain and pelvic torsion are so often associated with spasm or tightness of the piriformis that it is difficult to decide whether sacroiliac dysfunction is primary or secondary to piriformis overactivity.*
> (Grieve 1988:177)

Certainly, increased tone or outright 'spasm' is commonly detected in iliacus, piriformis and also gluteus maximus in someone presenting with malalignment; the tension sometimes decreases or resolves immediately on realignment. This phenomenon suggests that the increase in tone was in reaction to the malalignment rather than the cause of it, very likely indicative of facilitation and/or reflex contraction of these muscles as they attempt to counter the SI joint instability and decrease any discomfort caused by the malalignment (see Chs 3, 4: 'orthopedics' and 'piriformis syndrome').

Rotational forces acting on an innominate

Forces can act directly on the innominates to cause excessive anterior or posterior rotation relative to the sacrum which may result in a partial-to-complete impairment of movement between the sacrum and ilium. Unilateral rotational forces can result in three ways:

Leverage effect of a lower extremity

Excessive leverage forces can be exerted on one or other innominate with passive movements of the femur, either deliberately or such as may occur unintentionally in sports and during surgical, obstetric and gynaecological procedures (Grieve 1976; Figs 2.47, 7.16). There comes a point on passive right hip extension, for example, at which

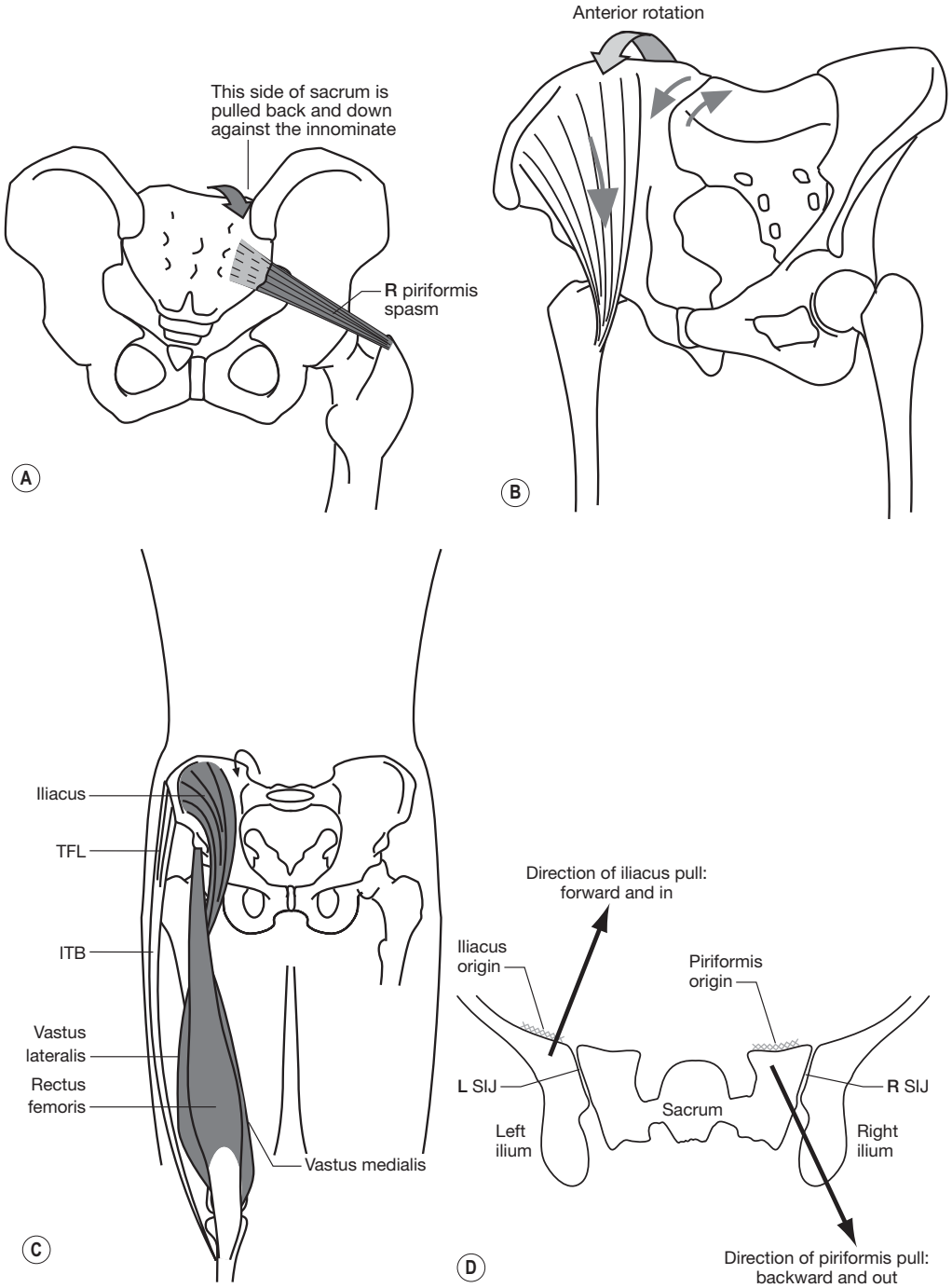

Fig. 2.46 Stabilization of the sacroiliac joint (SIJ) through wedging of the anteriorly widening sacrum (see also Figs 2.2B, 2.3, 2.4B, 2.10A, 2.11A). (A) Piriformis pulling the sacrum backward against the innominate. (B) Iliacus pulling the innominate forward against the sacrum. (C) Anterior innominate rotation through the action of iliacus, rectus femoris and the tensor fascia lata/ iliotibial band complex. (D) Wedging effect viewed from the top of the joint.

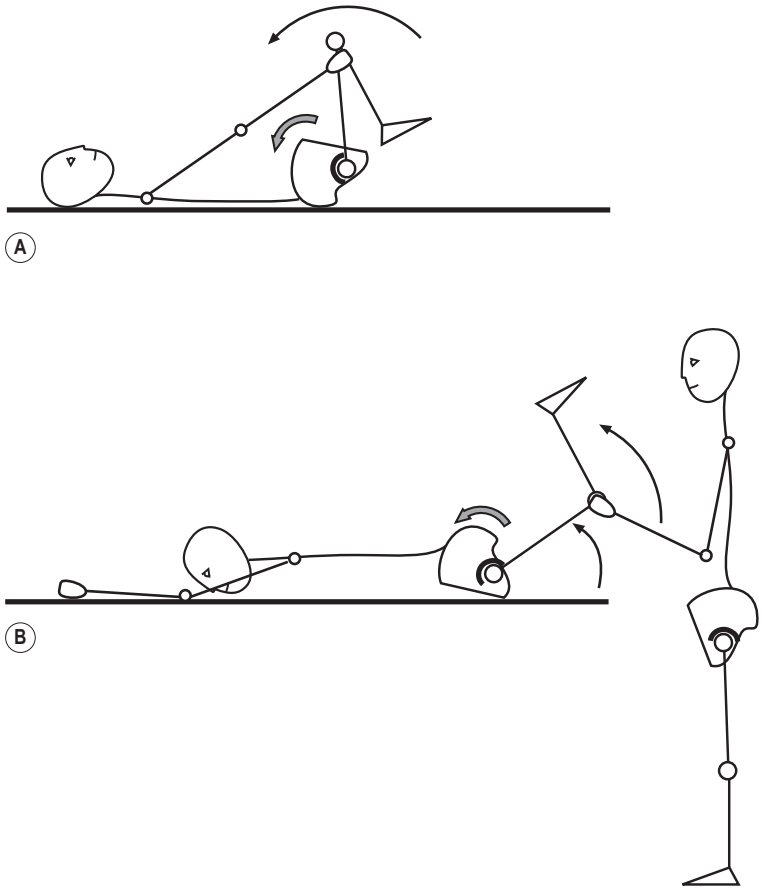

Fig. 2.47 Leverage effect of the femur on the innominate, by impingement against the acetabular rim (see also Figs 7.16–7.18). (A) Against anterior rim: results in posterior rotation. (B) Against posterior rim: results in anterior rotation.

movement of the femur independent of the ipsilateral innominate reaches its:

1. *physiological limit*
   This refers to the end point attained because of limitation by increasing tightness in the anterior muscles (e.g. iliacus, rectus femoris; Fig. 2.46C), ligaments (ilio- and pubofemoral; Figs 2.4A, 4.3) and anterior capsule (Fig. 2.48), without causing any damage.
2. *the anatomical limit*
   Once the femoral head engages the posterior acetabular rim (Fig. 2.48), the right femur and innominate move together on further active or passive hip extension, the femur now acting as a lever, the anterior muscles and ligaments as a traction force. Similarly, when flexing the hip by pulling or pushing the thigh onto the chest, the femur eventually turns into a lever as it engages

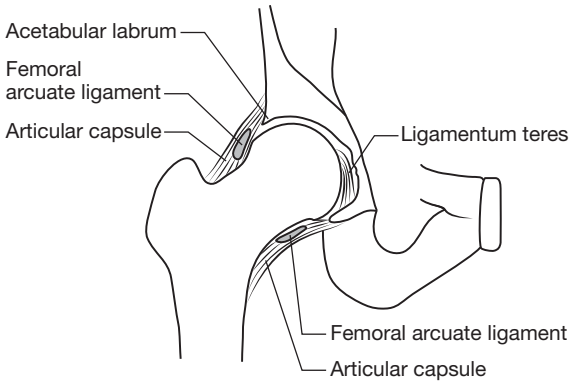

Fig. 2.48 Acetabular rim/labrum, joint capsule, and ligaments that can limit hip extension or flexion and can be injured when using the femur as a lever.

the anterior acetabular rim and any tight posterior muscles and ligaments (e.g. gluteus maximus, hamstrings, sacrotuberous ligament) to act as a posterior rotational torsion force (Fig. 2.47A).

It is for this reason that stretches involving unilateral hip flexion are best avoided on the side of a previously corrected 'posterior' innominate rotation during the initial period of treatment of a 'rotational malalignment' disorder, for fear of precipitating a recurrence of that 'posterior' rotation (Figs 3.74B, C, 7.22A,C). Conversely, the same manoeuvre may be useful to effect the correction of an 'anterior' rotation (Figs 7.16A,C, 7.17, 7.18).

Direct rotational force applied to an innominate

The application of specific forces, either actively (e.g. with walking or running or as part of a treatment regimen) or passively as the result of a fall or collision, can result in innominate rotation. There is some ongoing debate regarding the axes of rotation. DonTigny (2007) felt that there is a force-dependent transverse axis established 'through the sacrum, but not necessarily through the joints. . . . at the most posterion aspect of the S3 segment. . .this axis should probably be considered as being the axis for sacral rotation rather than an axis for the sacroiliac joint *per se*' (Fig. 2.49). Richards (1986) described the axis of rotation of the sacrum around the mean transverse axis (MTA), passing through the point at which the two parts of the L-shaped sacral articulating surfaces meet, at about the level of S2; whereas the axis of rotation of the wings of the ilia was observed to be around the inferior transverse axis, passing though the inferior pole of the sacral articulating surfaces at the S3 level (Fig. 2.50). There is also the previously mentioned element of the sacral and innominate joint surfaces 'gliding' relative to each other on sacral nutation/counternutation (Fig. 2.15) and innominate anterior/posterior rotation (Fig. 2.16).

'Anterior' rotational forces on the innominate result when:

1. an anterior force is applied to its posterior aspect above the level of the inferior transverse axis or ITA (e.g. against the posterior iliac crest)
2. a posterior force is applied to its anterior aspect below the level of the inferior transverse axis (e.g. the anterior or superior aspect of the pubic bone).

'Posterior' rotational forces on the innominate result when:

1. a posterior force is applied to its anterior aspect above the level of the inferior transverse axis (e.g. against the anterior iliac crest)

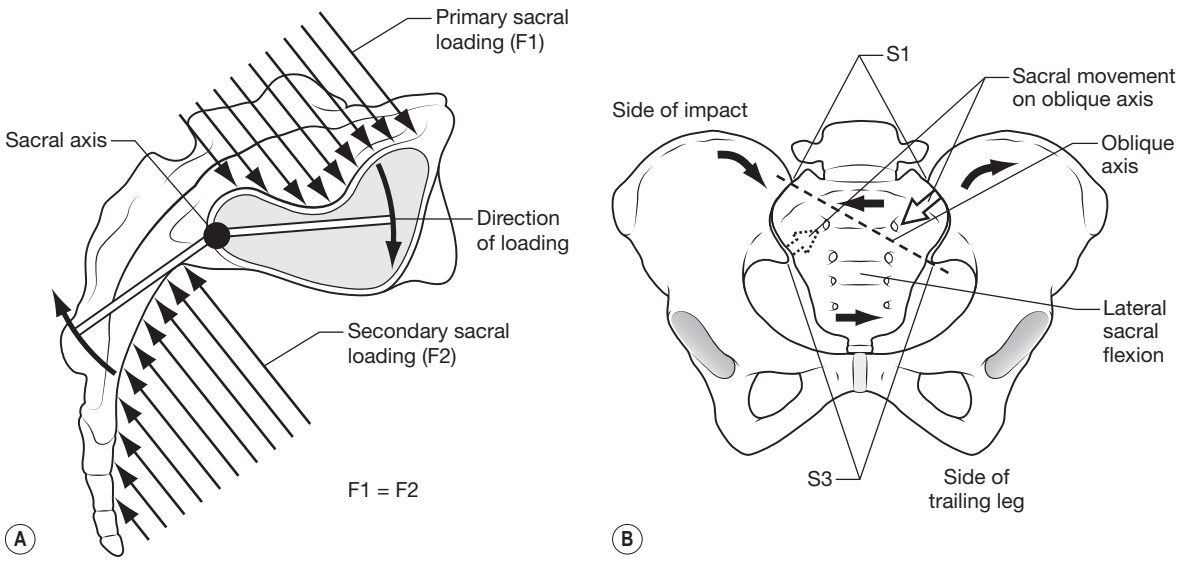

Fig. 2.49 (A) Two equal and parallel forces acting in opposite directions define the sacral axis. If the forces are spread, the force-dependent axis is more narrowly defined. (B) Posterior rotation (right) and anterior rotation (left) demonstrating joint closure at S1(right) and S3 (left) to create an oblique axis (OA). A functional destabilization occurs at S1 (left) and S3 (right), allowing the joint to open and move on that oblique axis. *(Reproduced from DonTigny 2004, courtesy of DonTigny 2007.)*

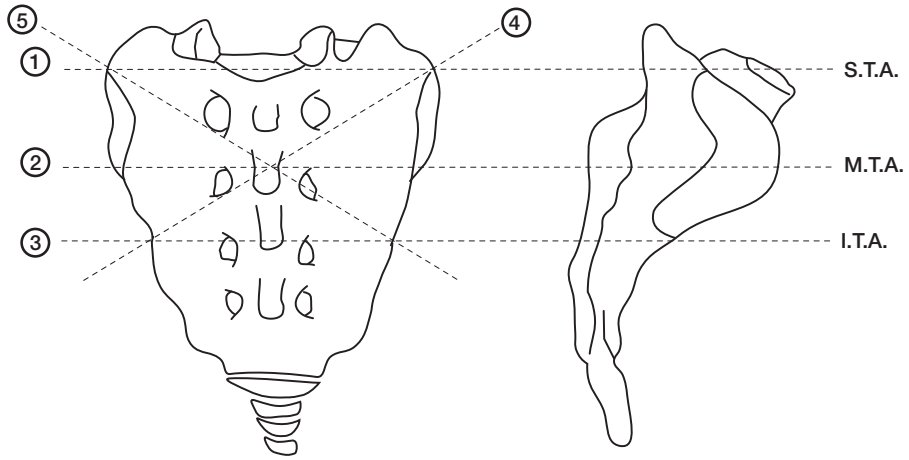

1 **S.T.A.** = Superior Transverse Axis – primary respiratory axis of Sutherland

2 **M.T.A.** = Mean Transverse Axis – axis of rotation of the sacrum in respect to the ilia

3 **I.T.A.** = Inferior Transverse Axis – axis of rotation of the ilia in respect to the sacrum, at the inferior aspect of the SI joint

4 Right Oblique Axis

5 Left Oblique Axis

Fig. 2.50 Axes of rotation around the sacroiliac joint.

2. an anterior force is exerted on its posterior aspect below the level of the inferior transverse axis (e.g. ischial tuberosity or inferior pubic bone).

Forces acting on a lower extremity

An impact to a lower extremity can affect the innominate if the force is transmitted upward through the hip joint when:

1. there is already some 'anterior' or 'posterior' rotation of the innominates, which results in the centre of the acetabulum being placed increasingly forward or backward of the vertical force-line, respectively
2. the femur is at an angle relative to the innominate at the time of impact.

Typical examples include:

1. at heel-strike (Figs 2.36A,B; 2.41-1,5)
2. falling forward and landing on one knee
3. coming down hard on one extremity while the trunk is lurched either forward or backward, (e.g. an uneven dismount in gymnastics, an asymmetrical landing following a jump, misjudging a change in floor level or simply missing a step when going down a staircase (Fig. 2.20)
4. the impact transmitted through an extended lower extremity on hitting against the wall in a luge event, or while jammed against the floorboards of a crashing bobsled or toboggan
5. the impact of a collision, absorbed by the knee hitting the dashboard or transmitted upward through the extended knee from the foot pushing on the clutch or brake, when the hip joint is partially flexed (Fig. 2.51).

Asymmetrical impact forces like these can sometimes work in the person's favour. The author is reminded of a woman who initially presented with 'right anterior, left posterior' innominate rotation, and the right ASIS prominent because of counterclockwise rotation of the innominates around the vertical axis ('right inflare, left outflare'). Two weeks later she was found to be in perfect alignment without having had any form of treatment in the interval. She recalled having tripped recently, landing initially on both knees, her trunk then being flung forward. In the process, she had seemingly effected a correction, either by exerting a 'left anterior' or a 'right posterior' rotational force through a femur on hitting the ground, or perhaps by way of reflex muscle contraction(s). Trauma can obviously work both ways!

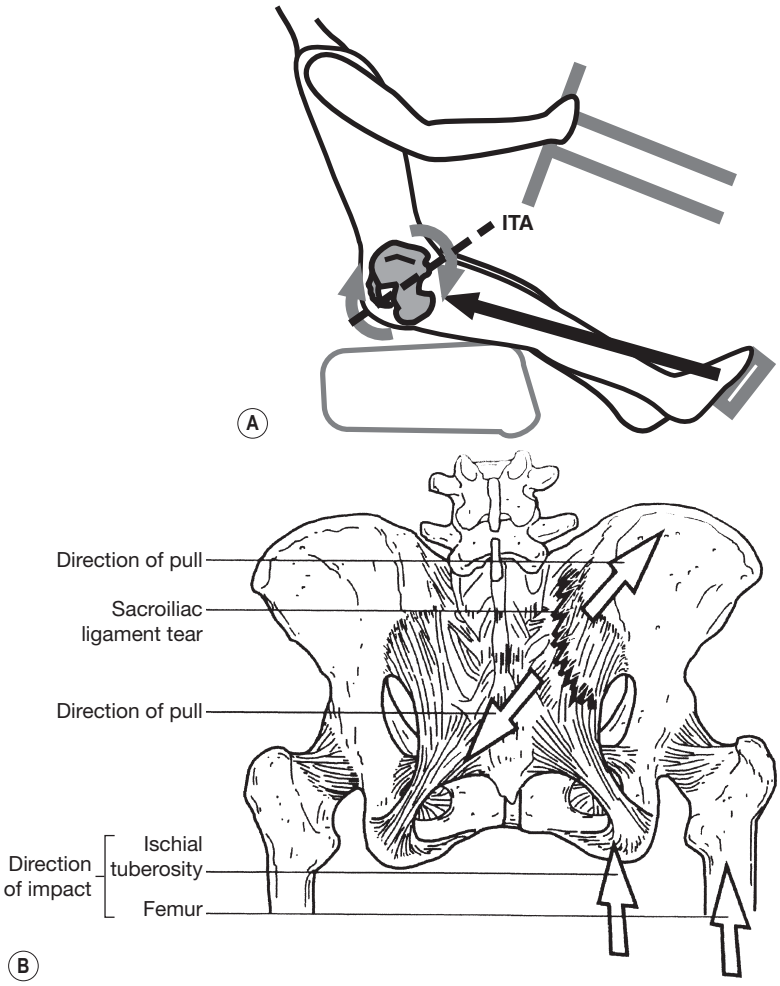

Fig. 2.51 Common mechanisms of injury. (A) In an automobile accident: the force, impacting on the acetabulum at an angle below the inferior transverse axis (ITA; see Figs 2.20, 2.50) results in anterior rotation of the right innominate. (B) In a fall: forcing the leg upward or landing on the ischial tuberosity can shear the ligaments between the sacrum and ilium.

Asymmetrical forces exerted by the spine, pelvis or legs
Torsion of the sacrum and rotation of the innominates can result from abnormal forces being transmitted to these bones from the spine, pelvic floor or lower extremities.

Spine
Excessive rotation of vertebrae from C1 down to L5 can result in forces capable of causing malalignment of the pelvis. These forces include a reactive asymmetrical increase in muscle tension and/or direct torsion and traction forces. A rotation of L4 or L5, for example, exerts a rotational or torquing force on each other and the sacrum by their interlinkage through the facet joints (Beal 1982; Kirkaldy-Willis & Cassidy 1985; Richard 1986; Gracovetsky & Farfan 1986; Lee 2004a). Rotational or torquing forces at the lumbosacral junction are recognized as one cause for recurrent malalignment of the pelvis (Fig. 2.52).

A right (clockwise) rotation of the body of L4 or L5 results in a posterior movement of the right transverse processes, and with it the origins of the attaching iliolumbar ligaments (Fig. 2.4A). The increase tension in these ligaments creates a posterior rotational force on the right ilium by way of the superior insertions into the posterior iliac crest and deep ones to the anterior ilium (Fig. 2.52A). The simultaneous anterior movement of the left transverse processes increases tension in the left iliolumbar ligaments

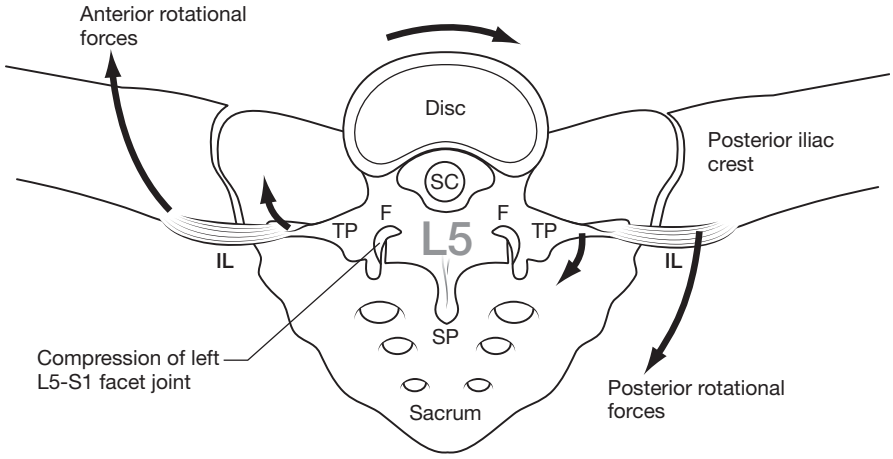

A

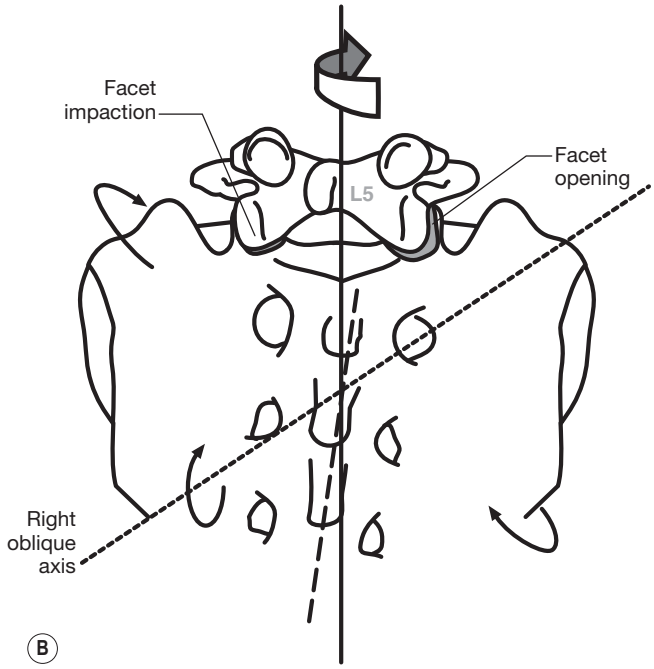

B

Fig. 2.52 Rotational effect on the innominates caused by right axial (clockwise) rotation of the L5 vertebral complex. (A) 'Right posterior' and 'left anterior' innominate rotation as a result of increased tension in the iliolumbar ligaments as these are being pulled backward on the right and forward on the left. (B) Rotation of the sacrum around the right oblique axis as a result of compression (impaction) of the left L5–S1 facet joint. IL=iliolumbar ligament; TP=transverse process; F=facet joint surface; SC=spinal cord.

and creates an anterior rotational force on the left innominate. The shorter the transverse process, the longer the iliolumbar ligament and the greater the torsional force (Farfan 1973). Vertebral rotation is coupled with side-flexion and some movement either into extension or forward flexion:

1. the L1-L3 vertebral right rotation around the vertical axis is accompanied by left side-flexion and some extension or forward-flexion
2. the pattern for L4 has been found to be variable; whereas L5 rotates and side-flexes to the same side (Pearcy & Tibrewal 1984;

Bogduk 1997) - Fig. 2.52B illustrates this 'motion coupling' effect (Lee 2004a)

Torsional forces with right rotation are, therefore, compounded if there is simultaneous:

1. upward movement of the left transverse process as L5 right side-flexes
2. L5 forward flexion

With L5 right-rotation, the right L5 inferior process separates from the superior process of S1, opening the space and increasing tension on the facet joint ligaments, capsule and nerves. The L5 right-rotation simultaneously exerts a left anterior torsional force through the left inferior L5-S1 facet joint as the inferior articular process of L5 impacts increasingly against the superior process of S1. Once these surfaces have been maximally compressed, the left L5 facet joint starts to act as a fulcrum so that any further rotation of L5 will now cause torsion of the sacrum around the right oblique axis (Fig. 2.52B). Excessive L4 right-rotation can have a similar effect, with initial compression of the left L4-5 facet surfaces eventually working as a fulcrum to rotate L5 vertebral body, then left L5-S1 facet and the sacrum in succession. The innominates, being attached to the sacrum, simply follow. In other words, excessive rotation of L4 or L5, by acting on the sacrum, can cause rotation of the whole pelvic ring as a unit, regardless of whether pelvic malalignment – 'rotational', 'flare' or an 'upslip' – is already present or not. However, assuming that malalignment is also present:

1. treatment that corrects the excessively rotated lumbar vertebra(e) and helps decrease reactive muscle spasm may simultaneously achieve realignment by allowing the bones of the pelvic ring to rotate back into place
2. initial treatment aimed at achieving pelvic realignment may actually allow L4 and/or L5 to rotate back into place by helping decrease pain and settle down any reactive muscle spasm that may have been pulling asymmetrically on one or both vertebrae

With both approaches, resolution of pain and muscle spasm are key factors that allow for pelvic realignment and/or rotation of any displaced vertebra(e) back into place (e.g. pelvic realignment allowing resolution of spasm in deep multifidi, extensor spinae so that L4 and/or L5 can rotate back into normal position or vice versa).

Pelvic floor

The components of the levator ani muscle constitute a major part of the pelvic floor. The location of these muscles and other structures can be defined on external (Fig. 2.53A) and on rectal (or vaginal) examination (Fig. 2.53B):

1. *puborectalis and pubococcygeus*, originating from the pubic bone and anterior obturator fascia
   a. puborectalis, running posteriorly to form a muscular sling by way of connections at the anorectal flexure with its partner on the opposite side
   b. pubococcygeus, attaching posteriorly to the midline raphe (fascial junction) or anococcygeal body, running from the rectum to the coccyx
2. *ilio- and ischiococcygeus*, arising from the ischial spine, posterior obturator fascia and sacrospinous ligament, and inserting posteriorly into the lowest part of the sacrum.

These various attachments of the levator ani muscles directly to parts of the pelvis, or indirectly by way of their ligamentous or fascial connections, puts them in a strategic position to influence alignment. For example, any asymmetry of tension in these structures caused by irritation of the pelvic floor muscles on one side by a unilateral ovarian cyst, uterine fibroid or other mass can result in recurrent malalignment of the sacrococcygeal joint, the innominates and/or the sacrum and, secondarily, the spine (Fig. 2.53C).

Diagnostic techniques such as Real-time ultrasound (RTUS), colour and duplex Doppler analysis (O'Neill & Jurriaan 2007) have been instrumental in assessing particularly the function of the 'inner core' muscles - the deep multifidi, transversus abdominis, diaphragm and pelvic floor muscles - and also of the bladder and organs as they inter-relate with these muscles (see also Chs 4, 7; Fig. 4.43). Examples include assessment of:

1. appearance and function of specific muscles, such as the multifidi (Figs 2.54, 2.55A,B):
   a. appearance is normal or there is evidence of hypertrophy or atrophy; e.g. confirming uni- or bilateral wasting of deep multifidi which, on paravertebral palpation, may have been felt as a dip on one or both sides at the level(s) involved
   b. function of superficial and deep fibre is normal or there is evidence of malfunction, such as failure to contract at all or hyperactivity of individual muscle layers
2. sequence of muscle activation; e.g. hamstring contraction inadvertently precede that of gluteus maximus when initiating hip extension

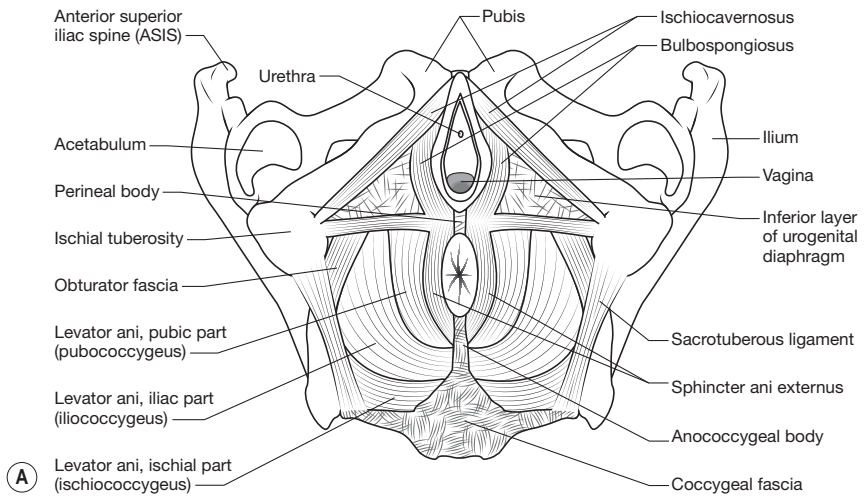

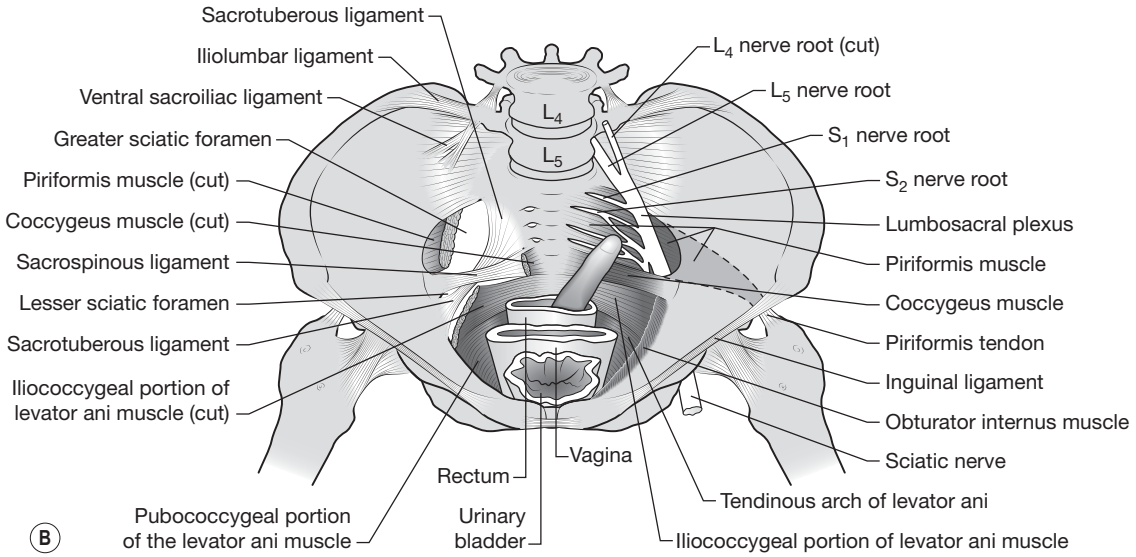

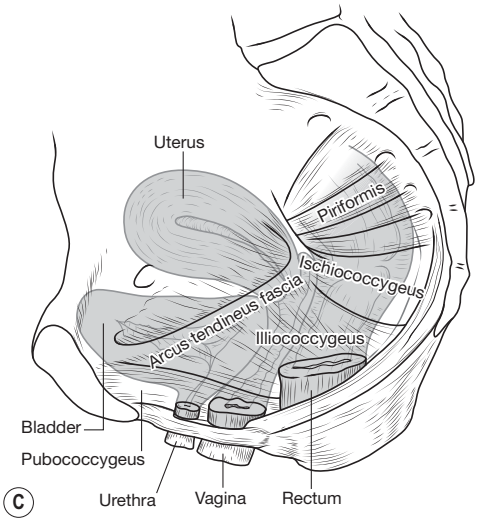

Fig. 2.53 (A) The female pelvic floor muscles and ligaments. *(Redrawn courtesy of Travell & Simons 1992.)* B. Internal palpation of the left piriformis muscle via the rectum. Viewed from in front and above. The sacrospinous ligament (covered by the coccygeus muscle) is the last major transverse landmark identified by the palpating finger before it reaches the piriformis muscle. The saccrospinous ligament attaches cephalad, mainly to the coccyx, which is usually easily palpated and mobile. The posterior wall of the rectum and the S3 and S4 nerve roots lie between the palpating finger and the piriformis muscle *(Redrawn courtesy of Travell & Simons 1992.)* (C) The relationship between the muscles, fascia, and organs (transparent) of the pelvic floor. *(Courtesy of Lee 2004a.)*

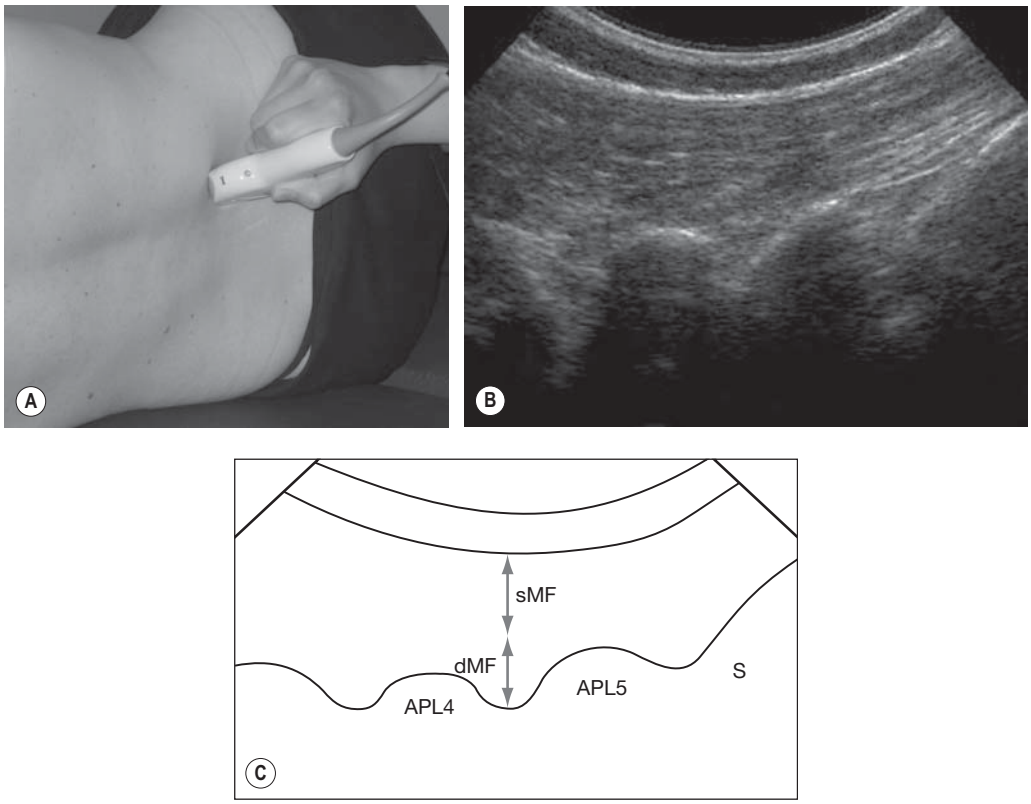

Fig. 2.54 (A) Ultrasound transducer placement for longitudinal imaging of the lumbar multifidus. (B) Longitudinal resting image of lumbar multifidus just lateral to the spinous processes and over the L3–S1 articular column. (C) Outline of the same image. APL4, articular process L4; APL5, articular process L5; S, sacrum; dMF, deep multifidus; sMF, superficial multifidus. *(Courtesy of Lee 2004a.)*

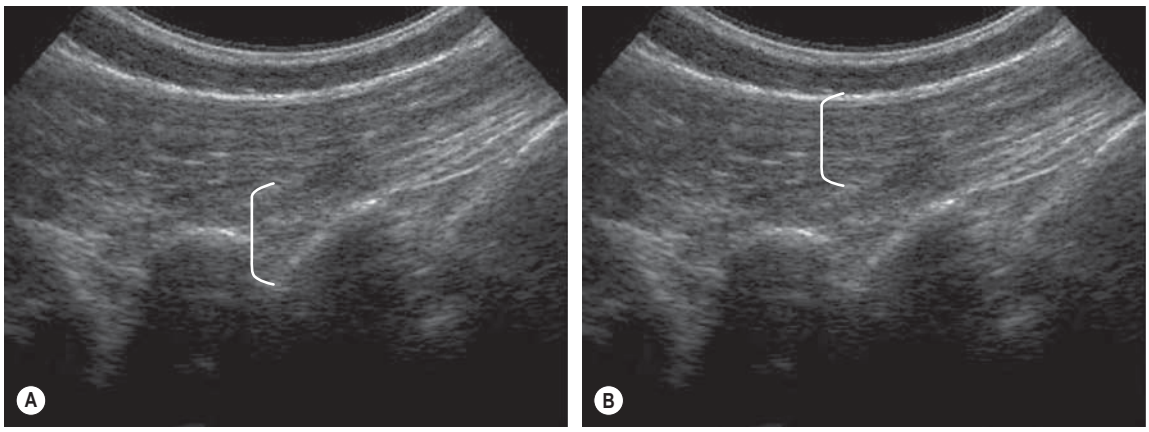

Fig. 2.55 (A) Ultrasound image indicating the location for an isolated response of the deep fibres of lumbar multifidus. (B) Ultrasound image indication the location for a hyperactive response from the superficial fibres of lumbar multifidus. *(Courtesy of Lee 2004a.)*

3. interaction of 'inner' and 'outer' core muscles
4. pelvic floor
   a. delineation of the bladder (Fig. 2.56A,B)
   b. functioning of the levator ani mucles and their effect (Bo et al. 2001, Whittaker 2004, 2007, 2010), including encroachment on the bladder with voluntary normal and abnormal pelvic floor contraction and the Valsalva manoeuvre (Fig. 2.57A,B)
   c. muscle tone; specifically, evidence of unilateral hypertonicity or hypotonicity (looking for evidence of encroachment or seeming 'widening' of the bladder, respectively, on the side affected)
   d. pathology such as organomegaly, ovarian cysts, fibroids, masses which can encroach on the 'inner core' muscles or the bladder itself and result in either a reactive increase in tension or an inhibition of core muscle contraction, very likely asymmetrically and, therefore, predispose to malalignment (Fig. 2.53C).

Assessment with the patient's awareness enhances treatment protocols as it allows for feedback that helps the person understand the problem at hand, learn how to activate or relax some muscles and in proper sequence, also to initiate progressive stretching and strengthening routines for specific muscles.

Lower extremities

Any condition that results in a lower extremity exerting an asymmetrical torquing force on a hip

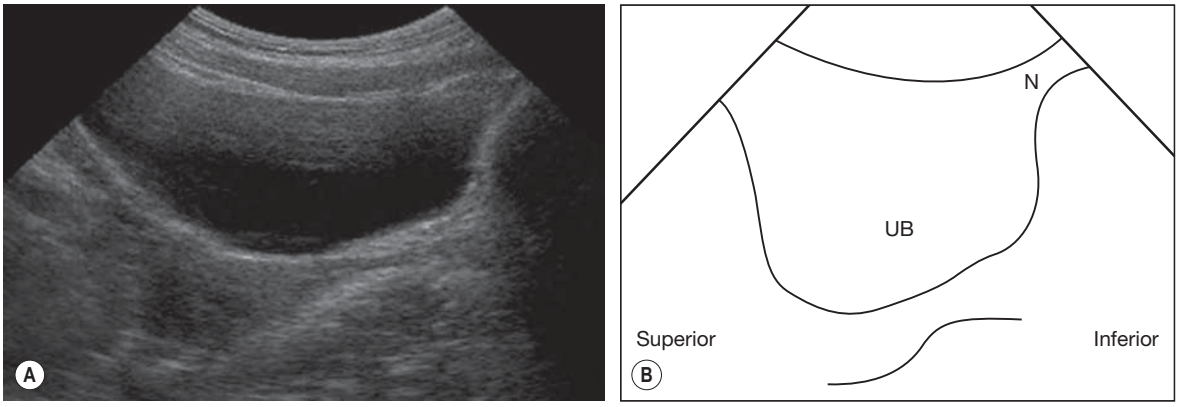

Fig. 2.56 Parasagittal abdominal ultrasound imaging. (A) Resting parasagittal abdominal image of the urinary bladder. (B) Labelled outline of the same image. UB, urinary bladder; N, neck of the bladder. *(Courtesy of Lee 2004a.)*

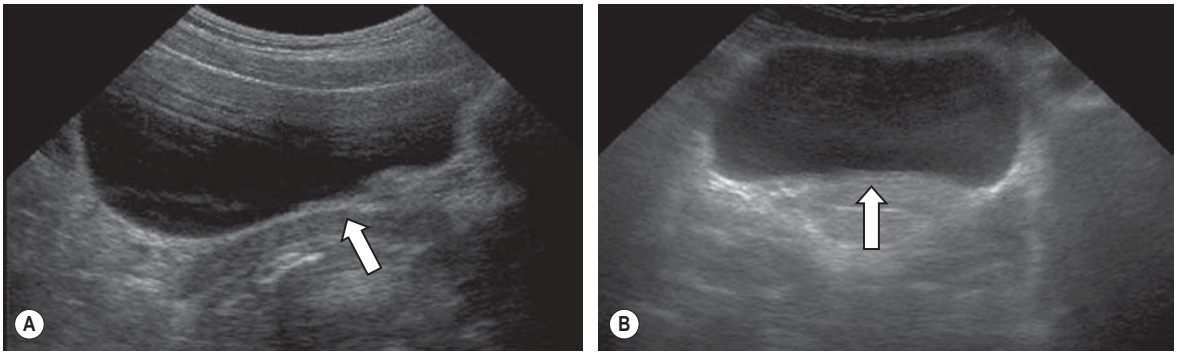

Fig. 2.57 Ultrasound image showing an isolated response of the pelvic floor muscles. The arrow notes where the bladder can be seen to indent with a proper pelvic floor contraction. (A) parasagittal abdominal view; (B) transverse abdominal view. *(Courtesy of Lee 2004a.)*

joint can, in turn, cause a 'rotational malalignment' as the force is transmitted, in succession, to the innominate, the SI joint, the sacrum and, finally, the lumbosacral junction. Torquing forces of this kind can result from:

1. asymmetrical weight-bearing on account of an anatomical (true) or a functional leg length difference
2. attempts by the pelvic girdle to compensate for problems to transfer load through the lumbo-pelvic-hip complex in order to reduce vertical shear forces through the SI joint:
   a. *compensated Trendelenburg gait for insufficient 'force' closure*
      Weakness in the left hip abductors makes them less effective (= decreased force closure) for stabilizing the left hip and SI joint for proper load transfer through the hip, SI joint and up through the lumbosacral junction. When walking, the person can compensate by leaning the trunk into the impaired left side during mid-stance, moving the centre of gravity outward from midline and more directly over top of the hip joint, thereby
      i. decreasing the need for left abductor muscle action to achieve stability of the left hip joint
      ii. decreasing vertical shear forces through the left SI joint (Figs 2.58A, 2.1C)
   b. *true Trendelenburg gait for insufficient 'form' closure*
      Left hip instability can be caused by degeneration (osteoarthritis) of the joint and/or ligament laxity and the joint may be inflamed and painful. The person may compensate for the impaired ability to transfer loads through the left hip by leaning away from that side (adducting the pelvis, abducting the left femur) in mid-stance, thereby
      i. bringing the centre of gravity closer to midline (away from the left hip joint and toward the SI joint
      ii. decreasing stress on the painful left hip joint
      iii. depending more on the strong left hip abductors to ensure stability of the left hip joint and also of the pelvic unit in the coronal plane (Fig. 2.58B)

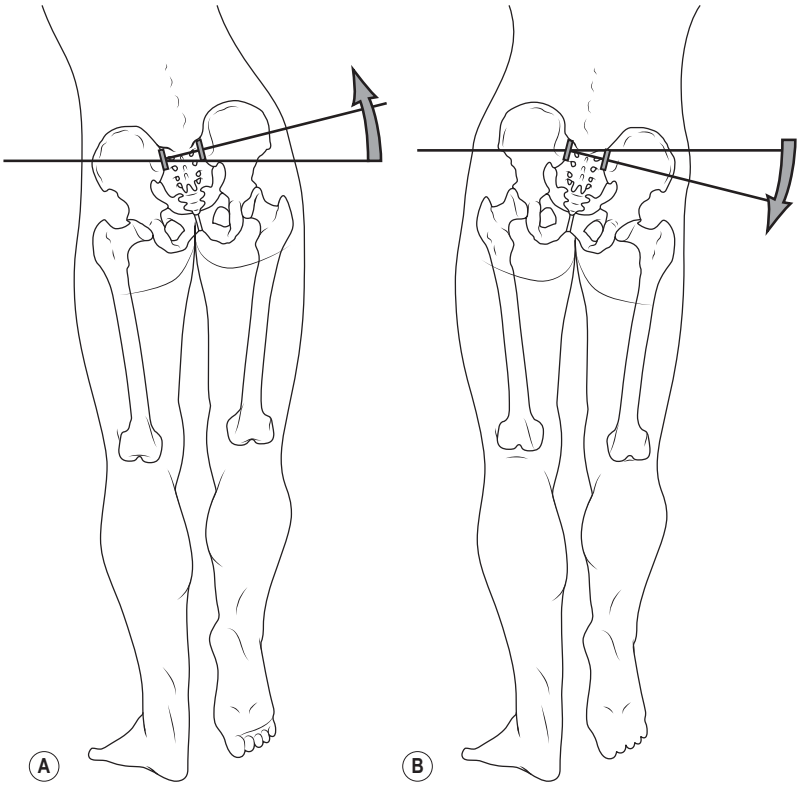

Fig. 2.58 A. Compensated Trendelenburg; B. True Trendelenburg (see also Fig. 3.93). *(Courtesy of Lee 2004a.)*

3. a change in weight-bearing caused by trying to avoid a painful condition involving a lower extremity; e.g. excessive supination of the foot and external rotation of the leg to avoid a painful osteoarthritic 1st and/or 2nd MTP joint
4. unilateral or asymmetrical muscle tightness or contracture acting on an innominate; for example:
   a. an 'anterior' rotational force exerted by a tight
      i. rectus femoris by way of its origin from the anterior inferior iliac spine (AIIS)
      ii. iliacus, TFL or the inferior band of the iliofemoral ligament pulling on the ilium when the hip joint is stabilized and cannot flex (Figs 2.4A, 2.46B,C, 2.59)
   b. a 'posterior' rotational force exerted by a tight biceps femoris, either directly, by way of its attachments to the ischial tuberosity, or indirectly, when continuations with the sacrotuberous (ST) ligament allow it to exert a pull all the way up to the ST origins from the sacrum and ilium (Figs 2.6, 2.59)
   c. asymmetrical forces created by contracture or scarring of the fascia that envelops the muscles of the trunk, hip girdle and thigh, with its extensive connections to the hip joint capsule and ligaments, the pelvis itself and proximally to the thoracolumbar and anterior abdominal fascia (Figs 2.31, 2.33)

Myofascial contracture and lengthening

Myofascial problems and treatment are discussed at length in Ch. 8. At this point, suffice it to say that contracture or lengthening of the fascia, musculotendinous units, ligaments and capsules are one of the major long-term complications of malalignment and a frequent cause of its recurrence. It is the nature of soft tissues to contract when placed in a shortened position and to lengthen when put under increased tension for prolonged periods of time.

Contracture can occur:

1. actively (e.g. as a result of chronic shortening of a muscle as it contracts continuously in reaction to joint instability or pain) or
2. passively (e.g. wherever the origin and insertion are moved closer together, as would happen to right rectus femoris when the right innominate is 'stuck' in an 'anterior' rotated position)

Alternatively, these tissues can undergo lengthening when subjected actively or passively to forces that increase tension by stretching on the muscle or by moving its origin and insertion further apart. Someone with 'rotational malalignment' usually presents with a pelvic obliquity and compensatory scoliosis (Fig. 2.60). The myofascial tissue:

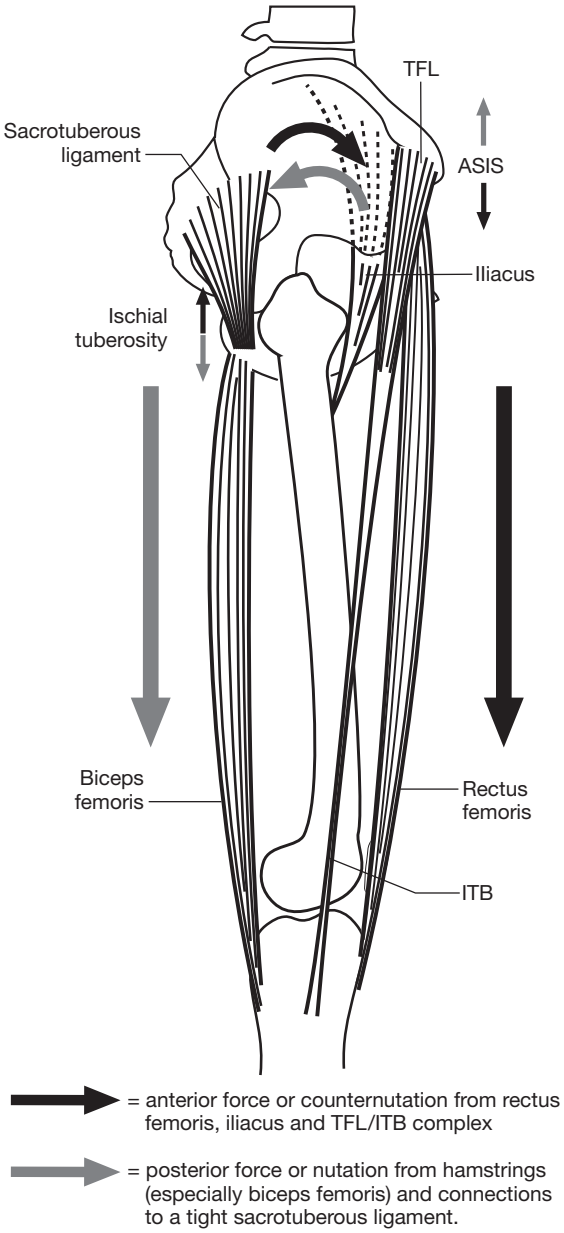

Fig. 2.59 Torquing/rotational forces on the innominate caused by tightness in the attaching muscles or ligaments (see Figs 2.46B,C for an anterior view). ASIS, anterior superior iliac spine.

1. on the relatively shortened concave side
   - may eventually shorten and augment any compressive force on the ipsilateral facet joints and aspects of the vertebrae and discs
2. on the relatively lengthened convex side
   - may elongate with time and decrease its ability to help counter joint instability on that side

There may also be contracture of muscles that have been in a chronic state of contraction in reaction to joint instability and/or pain. Myofascial tissue that is constantly placed in a shortened position will eventually undergo some reorganization. The gradual replacement of the muscle element with an increasing amount of fascial tissue between the muscle fibres and muscle fibre atrophy may eventually lead to end stage contracture (see Ch. 8).

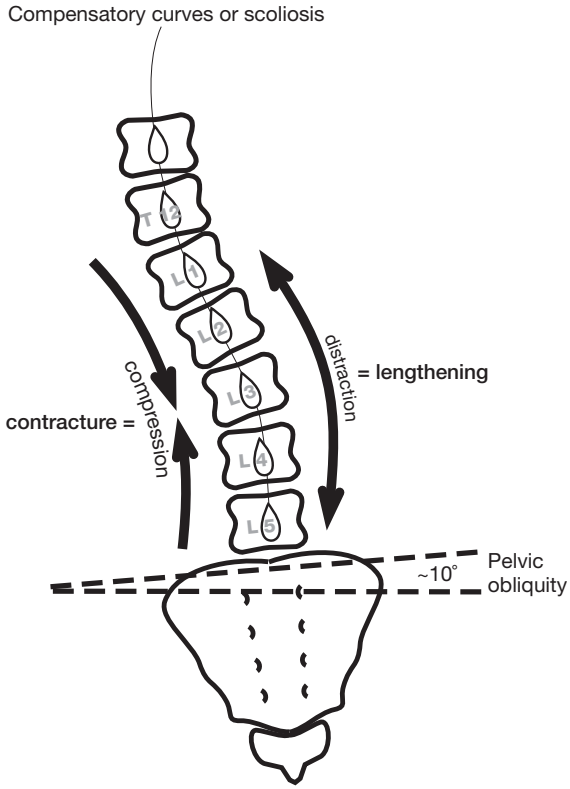

Fig. 2.60 Typical pelvic obliquity and compensatory scoliosis seen with an 'upslip' and 'rotational malalignment'. With time, myofascial lengthening occurs on the lumbar convex side and contracture on the concave side.

Failure to treat myofascial contractures has been identified as one of the factors responsible for the recurrence of malalignment following realignment of the bony elements of the pelvis and spine (Shaw 1992). Recurrence may also be attributable to connective tissue lengthening that has resulted in joint instability.

Contractures must be considered as a possible cause of some of the new aches and pains, often in areas which were not previously a problem, that people frequently report during the first 2-4 weeks following initial realignment. On achieving realignment, tension is increased in the structures that have shortened with long-standing malalignment; they may now unexpectantly become a cause of localized and/or referred discomfort and outright pain. These new symptoms gradually abate and eventually disappear altogether as normal length is regained and alignment finally maintained.

SACROILIAC JOINT 'UPSLIP' AND 'DOWNSLIP'

The degrees of freedom of the SI joint normally allow for approximately 2 degrees of upward and downward (craniocaudal) translation of an innominate relative to the sacrum (Fig. 2.9; William & Warwick 1980, 2004). Excessive upward or downward movement can result in the 'fixation' of an innominate - getting 'stuck', so to speak - in what are referred to as an SI joint 'upslip' and 'downslip' position, respectively.

Sacroiliac joint: unilateral 'upslip'

An 'upslip':
1. may co-exist with a 'rotational malalignment' and/or an 'outflare/inflare'
2. occurs considerably less often than 'rotational malalignment' (about 10-20% versus 80%, respectively, of all those noted to have one or more of the three common presentations)

The more obvious causes of a right or left 'upslip' include:

1. *traumatic upward forces*

   These would have to be transmitted straight upward:

a. through the innominate itself, such as on falling and landing directly on the ischial tuberosity on one side
b. through the leg to the acetabulum, with the knee straight and the hip joint in a relatively neutral position, so that the leg does not exert a rotational force on the innominate; such a situation might occur, for example, when:
   i. landing hard on the extended extremity in a fall, on a dismount or just missing a step (Figs 2.20A, 2.61A)
   ii. the foot is jammed against the floorboards of a crashing car, bobsled or other vehicle (Fig. 2.51A)

A traumatic 'upslip' like this can cause or aggravate a shear injury involving the ipsilateral SI joint and/or symphysis pubis that may increase joint instability and predispose to recurrence of the 'upslip' (Fig. 2.51B).

2. *injury to a muscle that can pull upward on the innominate*

For example, left quadratus lumborum can be sprained or strained on leaning forward and side-flexing to the right to pick an item up from the floor, especially if this proves heavier than expected (Figs 2.43A, 2.62). An ongoing increase in tension in that muscle subsequently, pulling upward by way of its origin from the posterior iliac crest, can eventually result in a 'left upslip' which may persist until tension in that muscle is finally released to allow the left innominate to slide down to the point where the SI joint surfaces are once again aligned.

However, in the absence of a history of trauma, more subtle forces that could cause an 'upslip' to

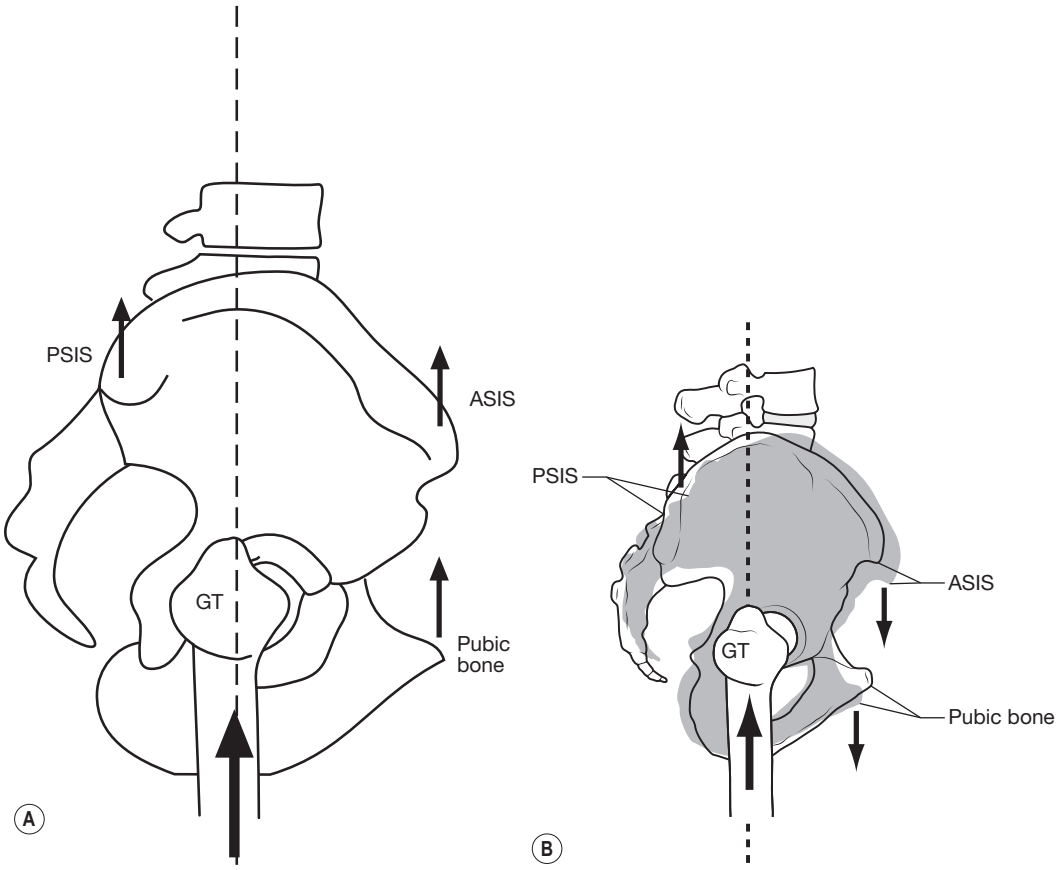

Fig. 2.61 (A) 'Right upslip' caused by a unilateral femoral upward force transmitted through the hip joint to the innominate. (B) The 'upslip' is hidden by the shift of all the pelvic landmarks with a coexistent 'right anterior rotational malalignment'. ASIS, anterior superior iliac spine; GT, greater trochanter; PSIS, posterior superior iliac spine.

occur initially and are probably to blame for its persistance/recurrence include:

1. *an imbalance of tension in right compared to left hip girdle muscles*
   This involves in particularly those that show 'facilitation' as part of the 'malalignment syndrome' (see Ch. 3); typical of these is:
   - a unilateral increase in the resting tone involving quadratus lumborum, latissimus dorsi, psoas major/minor (Figs 2.62, 3.43), external and/or internal abdominal obliques, in isolation or in combination (Figs 2.32, 2.33).
2. *coronal (frontal) plane asymmetry*
   Rotation of the pelvic unit around the sagittal axis in the coronal plane for whatever reason results in a secondary pelvic obliquity; e.g. as caused by an anatomical (true) LLD or a functional LLD seen with 'rotational malalignment'. Counterclockwise rotation of the pelvis, for example, results in the sacrum now 'tilting' to the left and would change the direction of the SI joints so that:
   a. the left is now at a greater angle, increasing surface compression forces and stability of the joint on this side
   b. the right SI joint is now more vertical and the surfaces subjected to greater shear stresses on loading (Fig. 2.1C), increasing the possibility of an 'upslip' occuring on this side as the right innominate is at increased risk of moving craniad relative to the sacrum on right weight-bearing or with an upward force applied to the right iliac crest (e.g. tense quadratus lumborum), femur or ischial tuberosity (e.g. fall onto the right knee or buttock, respectively)

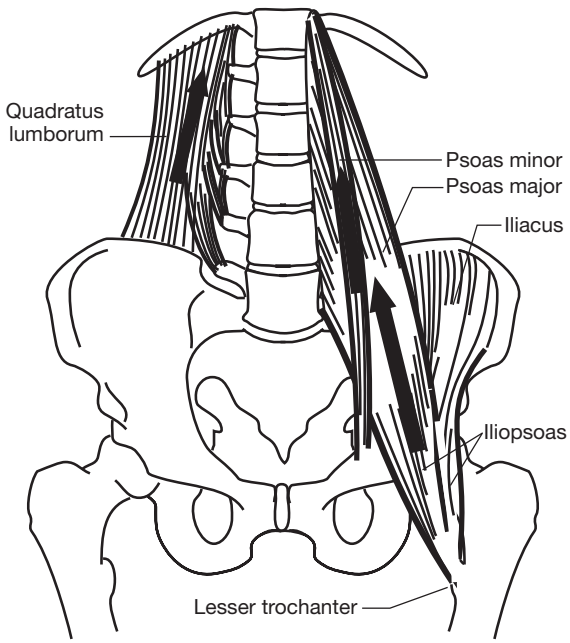

Fig. 2.62 Muscles capable of generating forces (arrows) that can result in an 'upslip'.

As with 'rotational malalignment', a unilateral 'upslip' is associated with the findings typical of the 'malalignment syndrome' (Ch. 3). In addition, on the side of the 'upslip':

1. the leg will be shorter to an equal extent both in long-sitting and lying (see 'sitting-lying' test below)
2. there results a specific pattern of pelvic ring distortion in that all ipsilateral landmarks, anterior and posterior, have moved upward relative to the sacrum itself and to the innominate on the opposite side.

Appendix 2 gives the examination findings typically seen with a right 'upslip' and these findings are detailed below in the discussion on 'Establishing the diagnosis of malalignment'.

Sacroiliac joint: 'bilateral upslip'

A 'bilateral upslip' is present when both innominates have moved upward an equal amount and 'jammed', something that may occur with a straight upward force when landing fairly symmetrically on:

1. both ischial tuberosities (e.g. falling backward onto ice or other hard surface)
2. both feet, with the knees in exension, provided the hip joint is in 'neutral' alignment so that forces end up being transmitted straight up through the acetabulum bilaterally
3. the distal femur or the patella bilaterally, with the knees in flexion and hip joints in 'neutral'

Sacroiliac joint: 'downslip'

A unilateral 'downslip' occurs rarely and the diagnosis is frequently delayed or missed altogether. Typically, there is a history of excessive traction on an extremity; examples of this include:

1. incidents where the person is hurled forward while one leg remains tethered, such as can occur with the failure of one ski binding to release, or

with entrapment of one foot in the toe straps of a crashing bicycle or the stirrup while riding horseback
2. trying to rapidly extract an extremity that has sunk into a hole; for example, a foot suddenly stuck in mud on a boggy running trail or in quicksand

A 'downslip' is frequently misdiagnosed and the person treated initially for an 'upslip' of the opposite SI joint. It is often only when measures aimed at correction of the so-called 'upslip' repeatedly fail that the therapist begins to suspect that the problem is actually a 'downslip' on the opposite side and appropriate treatment is finally started. Sometimes, a person who has been instructed in how to use traction ends up with a 'downslip' on account of having overcorrected for an 'upslip' by applying traction: too much, too often or when it was not even indicated because the 'upslip' had already been corrected.

'Bilateral downslips' can occur but will not be discussed further other than to say they should be considered in the differential diagnosis whenever there is a history of the body having been catapulted forward or downward while both legs/feet were entrapped or secured (e.g. failure of bindings to release when both skies suddenly get stuck in a mogul/snow bank and the skier is thrown forward; inadvertent excessive traction on lower extremities of a bunji jumper as a result of retraining bindings having been applied incorrectly).

PELVIC 'OUTFLARE' AND 'INFLARE'

'Outflare' and 'inflare' refer to movement of the innominates outward and inward, respectively, around the vertical axis in the transverse plane (Figs 2.13, 2.17). A normal bilateral 'outflaring' and 'inflaring' have invariably been linked to simultaneous 'anterior' or 'posterior' rotation of the innominates around the coronal axis. The following are some of the descriptions offered as to how and why this should happen.

'Outflare' linked to 'anterior innominate rotation'

As previously described (DonTigny 1990), the anterior widening of the sacrum causes the innominates to 'spread on the sacrum'; i.e. flare out whenever the innominates rotate anteriorly and downward relative to the sacrum (Fig. 2.17). More recently, he suggested that 'SIJD [SI joint dysfunction] is essentially always caused by an anterior rotation of the innominate bones cephalad and laterally [= 'outflare'] on the sacrum' (DonTigny 2007). 'Inflare' supposedly occurs with a 'posterior' rotation of the innominates relative to the sacrum and with sacral nutation.

'Outflare' linked to trunk flexion in standing

During the initial 50-60 degrees forward flexion in standing the sacrum nutates; the ilia rotate anteriorly 'in the sagittal plane' (Kapandji 1974) and flare outward (see 'Biomechanics' above; Fig. 2.17).

'Outflare' or 'inflare' linked to innominate rotation?

1. the posterior aspect of innominates that are rotating posteriorly have been described as gliding medially because of the posterior narrowing of the sacrum, causing the pelvis to open anteriorly; the same would occur with sacral nutation (Lee 1999)
2. 'inflare' has also been seen in conjunction with 'anterior' rotation and sacral counternutation (JS Gerhardt, pers. comm. 1999).

Other factors that may determine whether an 'outflare' or 'inflare' occurs, and the extent of it, include:

1. tightening or actual contracture of posterior and anterior SI joint ligaments, respectively
3. contraction of transversus abdominis, producing a force that would tend to pull the right and left ASIS together - predisposing to inflare of the innominates (Fig. 2.30)
4. tight muscles; e.g. adductors and gracilis, predisposing to 'outflare'; abductors and piriformis, predisposing to 'inflare'.

'Outflare'/'inflare' in the normal gait cycle

During the normal gait cycle (Figs 2.12, 2.13A, 2.41), the pelvic unit rotates around the vertical axis and there occurs:

1. an inflaring on the swing-side, as the innominate moves forward in the transverse plane; simultaneous posterior rotation of the innominate places the sacrum into relative nutation on this side, which helps stabilize/'lock' the SI joint in preparation for heel-strike and weight-bearing
2. an outflaring on the weight-bearing side, as the innominate moves backward in the transverse plane; simultaneous anterior rotation of the innominate results in relative sacral counternutation, SI joint laxity and increased ability to absorb shock

The malalignment presentations of 'outflare' and 'inflare'

When there is malalignment in the form of a 'flare' presentation, the person typically seems to have become 'stuck' in either a:

1. 'right outflare, left inflare' pattern, with the innominates rotated clockwise around the vertical axis, or
2. 'right inflare, left outflare' pattern, with the innominates rotated counterclockwise around the vertical axis

When considering pathological 'outflare' and 'inflare', other facts to appreciate include the following:

First, a unilateral 'outflare' or 'inflare' can be seen in isolation; for example, a 'right outflare' only (with the left innominate and sacrum still in alignment) could occur as the result of:

1. lax anterior, tight posterior right SI joint ligaments
2. chronic increase in tension or spasm in right hip adductors and/or gracilis, pulling outward and up on their origin from the pubic bone, just lateral to the symphysis pubis (Fig. 2.63)

Second, the more common clinical presentation is with the innominate fixed in a position of an 'outflare' on one, 'inflare' on the opposite side, as if one is compensating for the other. Aside from some of the possible contributing causes cited above, other factors to consider include:

1. Reversal of the convex-concave relationship of the SI joint surfaces in the long and short arms (Figs 2.2, 2.3B) allows for innominate rotation medially or laterally around a vertical axis which could result in inflare or outflare dysfunction, respectively (Greenman 1990).
2. Normally, in the course of each gait cycle, the innominate passing through the swing phase is observed to rotate from outflare-to-inflare, while that on the opposite side passing through the stance phase rotates from inflare-to-outflare. The abnormal presentation shows the pelvic ring seemingly 'fixed' in the transverse plane in sitting, standing and during the gait cycle, with the innominates either in:
   a. the 'right outflare, left inflare' pattern
      - in this case, the landmarks of the pelvic unit (e.g. ASIS, PSIS - Fig. 2.13Ai-iii) consistently end up forward on the left side relative to the right and the left ASIS ends up higher when lying supine (Fig. 2.64)
   b. the 'right inflare, left outflare' pattern
      - all the pelvic landmarks are forward on the right side and the right ASIS is higher when lying supine.

On realignment, right and left pelvic landmarks will again be symmetrical and the previous side-to-side difference detected when using a level for comparison of the height of the ASIS in supine-lying no longer apparent (Fig. 2.65).

Third, a pelvic 'outflare/inflare' presentation may possibly be the result of the changes caused by one of the other presentations when seen in conjunction with:

1. a 'rotational malalignment' - the 'outflare' can be seen on the side of the 'anterior' rotation and the 'inflare' on that of the 'posterior' rotation, or vice versa; commonly noted patterns are:
   a. 'right anterior and outflare, left posterior and inflare'
   b. 'left anterior and outflare, right posterior and inflare'
2. an 'upslip' - either the 'outflare' or 'inflare' can appear on the side of the 'upslip'.
3. both of these presentations at the same time.

Finally, tightness or adhesions in the surrounding tissues may determine whether an 'outflare' or

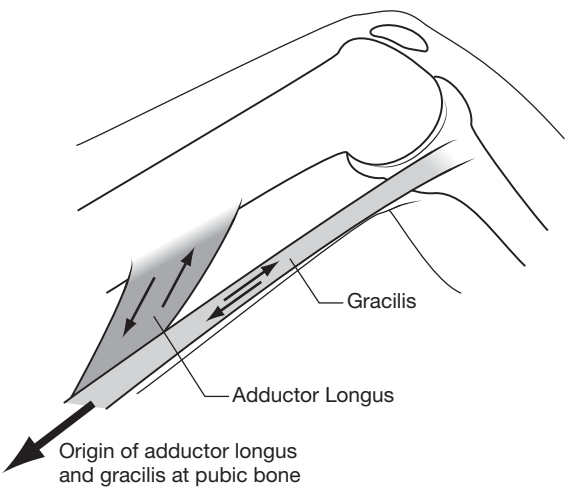

Fig. 2.63 Forces generated by adductor longus and gracilis: 1) adduction of leg; 2) traction forces on inner pubic bone origin, which (a) can result in an innominate 'outflare', (b) can be harnessed to correct an innominate 'inflare' using muscle energy technique (MET; see Ch. 3).

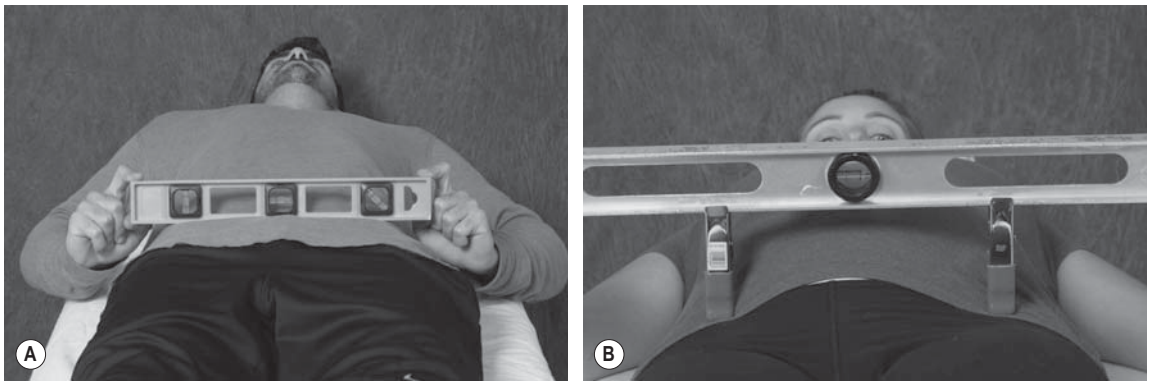

Fig. 2.64 'Right outflare, left inflare': (A/B) a level resting on top of the right and left ASIS shows elevation of left side; (B) 'feet' (clamps) attached to the level rest on right and left ASIS; they raise the level to help bring the bubble into view (e.g. for someone who is obese, pregnant)

Fig. 2.65 ASIS now level, bubble in centre, following correction of the 'outflare/inflare' (same subject as in Fig. 2.64A).

'inflare' occurs together with innominate rotation in the sagittal plane. Factors to consider include:

1. adhesions and/or scar tissue formation involving the lower posterior pelvic ligaments (considering a sacral axis of rotation around the S3 level; Fig. 2.49) and the long (dorsal) sacroiliac ligament would tend to hold the posterior aspect of the innominate medially and predispose to persistence of an 'outflare' as well as 'posterior' innominate rotation (Figs 2.5A, 2.19B)
2. contracture or scarring of the inguinal ligament would predispose to an 'inflare' and 'anterior' rotation because of its interconnections with ligaments and fascia crossing the symphysis pubis and anchoring to the opposite pubic bone (Fig. 2.4A)

The umbilicus and the gluteal cleft conveniently demarcate the anterior and posterior midline, respectively. If a 'right outflare/left inflare' are present:

1. the right ASIS will have moved outward and the left inward relative to the umbilicus; with the thumbs resting against the inside of the ASIS:
   a. the thumb on the 'inflare' side will appear closer to centre; whereas that on the 'outflare' side ends up further away (Figs 2.13Bi; 2.66)
   b. the index fingers meet off-centre, on the 'outflare' side, when the palms are swung inward (pivoting on the thumbs; Fig. 2.67)
2. the right PSIS will have moved inward and the left outward relative to the gluteal cleft (Fig. 2.13Aii,iii and Ci).

On realignment, the thumbs are again equidistant from midline (Figs 2.13Bii,Cii; 2.71Ei) and the index fingers meet in centre (Fig. 2.69).

Correlation of the PSIS to the gluteal cleft is more likely to be accurate, as it allows for an easier comparison with the landmarks lying closer together. Also, the umbilicus is frequently off-centre pre- and post-partum or as a result of previous surgery (e.g. appendectomy, unilateral hernia repair) and visceral adhesions (e.g. traumatic, surgical or post-partum). In addition, the umbilicus may appear in centre when an 'outflare/inflare' is actually present; for example, it may appear equidistant from the right and left ASIS as a result of having been pulled

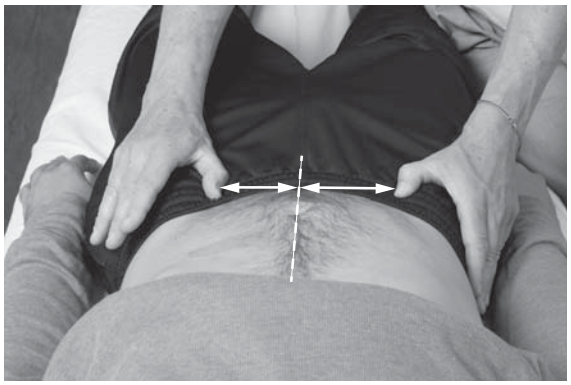

Fig. 2.66 'Right outflare, left inflare' present: thumbs anchored to inside of ipsilateral ASIS are not equidistant from umbilicus and central hairline marker (left ASIS is closer, right further away); left finger tips end up off the bed, right touching.

Fig. 2.67 Index fingers pivoted inward fail to meet in centre; index on subject's right ends up outward from, left inward (actually across) the centre line, in keeping with the right 'outflare' and left 'inflare', respectively.

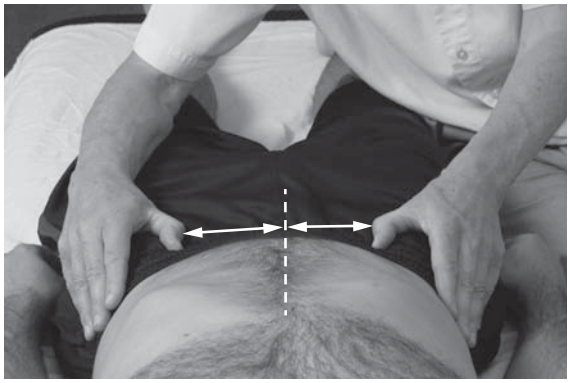

Fig. 2.68 With correction of the 'outflare/inflare', thumbs anchored to inside of ipsilateral ASIS are now equidistant from midline; right/left finger tips now equal distance off the bed.

Fig. 2.69 Following realignment, index fingers again meet in midline.

toward the side of the 'outflare' by a unilateral tightness caused by scar tissue or adhesions or an increase in tension in muscles such as transversus abdominis, rectus abdominis or external/internal obliques. An even easier, and probably more accurate way of determining 'outflare' and 'inflare' that depends on determining ASIS/PSIS displacement, both relative to the centre and forward/backward position in the transverse plane, is outlined in Box 2.2 and will be discussed at length in Ch. 7.

The recognition of an 'outflare' and 'inflare' is important from a treatment perspective in that:

1. they can result in specific clinical problems relating to altered biomechanics, stress being placed particularly on the hip and SI joints, lumbosacral region and specific muscles, ligaments and other soft tissues (see Ch. 3)
2. 'rotational malalignment' and 'upslip' may resist treatment efforts using the muscle energy technique of manual therapy until a coexistent 'outflare' or 'inflare' has been corrected first (see Ch. 7)
3. attempts aimed at first correcting the 'outflare' and 'inflare' are successful in simultaneously correcting a coexistent 'rotational malalignment' in 70 to 80% of cases but are unlikely to correct a coexistent 'upslip'

BOX 2.2 Determining 'outflare' and 'inflare'

Look for a change in the relative position of:

1. the ASIS when lying supine
   a. relative to the umbilicus: outward with an 'outflare', inward with an 'inflare' (Figs 2.13A,Bi, 2.66, 2.67)
   b. relative to the table: low on the 'outflare', high on the 'inflare' side (Figs 2.13Aiii, 2.64)
2. the PSIS when lying prone
   a. relative to the sacral spinous processes or gluteal crease:
      -inward on the 'outflare', outward on the 'inflare' side (Fig. 2.13 Ci)
   b. relative to the plinth or table top: relatively high on the 'outflare', low on the 'inflare' side

Always remember that:

1. the height will also be affected by a 'sacral torsion' around the vertical or an oblique axis; to lesser extent, by 'rotational malalignment' (e.g. the ASIS displacement forward and down to the table with 'anterior' and backward and up from the table with 'posterior' rotation of an innominate)
2. assessment in prone-lying is usually a more accurate way of determining 'outflare/inflare', even when there is a coexistent 'rotational malalignment'.

ESTABLISHING THE DIAGNOSIS OF MALALIGNMENT

The initial step in the diagnosis of malalignment is to establish whether asymmetry is present and, if so, whether it is caused by one (or a combination) of the following:

1. an anatomical (true) leg length difference (LLD),
2. one of the 3 common presentations of pelvic malalignment, with a functional LLD (seen with an 'upslip' and 'rotational malalignment')
3. vertebral rotational displacement
4. sacral torsion

Examination is preferably carried out on a firm, even surface. Sitting or lying on a soft or sagging support, or across a break in the surface (a feature common to medical plinths; Fig. 3.20A), may affect the assessment and lead to incorrect conclusions and possibly misdiagnosis. If the reader is interested in carrying out mobilization procedures other than the simple manual therapy techniques presented in this text, a more thorough determination of the type of pelvic and spine malalignment present is of the utmost importance. Such a detailed assessment is, however, not usually necessary in order to apply the material presented here to the clinical setting. Advanced assessment and treatment techniques are best learned in a formal teaching setting, hands-on workshops and from selected papers, books and educational videos/DVDs (see DVD information provided and listings under 'References' and 'Useful addresses and web sites').

Box 2.3 outlines the basic questions to be answered by the examination.

PELVIC OBLIQUITY

The presence of a pelvic obliquity may become obvious from noting that the pants, a belt or underwear are up on one side as the person walks, stands or sits (Figs 2.70, 2.76B, 2.90, 6.4, 6.5). A more accurate examination to determine whether the pelvic landmarks are lying level or obliquely relies on side-to-side comparison with:

1. visualization or palpation of the sometimes very easily apparent 'dimples of Venus' on the buttocks, about 1 cm above the PSIS and overlying the hollows - or sacral 'sulci' - formed

BOX 2.3 Examination for pelvic malalignment

1. Is the pelvis level or oblique?
2. Are the bony landmarks of the pelvis symmetrical or asymmetrical?
3. What happens on the 'sitting-lying' test (described in detail below)?
4. Is there any sacral torsion or excessive nutation or counternutation of the sacrum?
5. Is there an obvious curvature of the spine (e.g., a scoliosis, increased lumbar lordosis, thoracic kyphosis) and/or any rotational displacement of isolated vertebrae?
6. Is there excessive gapping and/or displacement of the symphysis pubis at rest or on stressing the joint?
7. Is there an abnormal increase in tension and/or tenderness localizing to specific muscles and ligaments?
8. What are the findings on sacroiliac joint and pelvic girdle testing for:
   a. function, motion/mobility and stability
   b. 'form' and 'force' closure?
9. Is the basic musculoskeletal, neurological and vascular examination normal?

Fig. 2.70 Belt angled up on right in standing, indicating pelvic obliquity (inclined to right).

by the junction of the base of the sacrum with the posterior iliac crest on either side (Figs 2.6, 2.71A, 2.87B)

2. the index and/or middle fingers lying on the lateral iliac crests (Fig. 2.71B)
3. the thumbs or index fingers resting on the superior rim of the pubic bones (Fig. 2.71C)
4. thumbs pressed upward against the inferior aspect of the ASIS (Fig. 2.71D), PSIS ('X' on Fig. 2.71Eii), ischial tuberosities (Fig. 2.71F), ILA (Figs 2.3A 2.71 G, 2.87B) or inside of PSIS (Fig. 2.71Ei)

Assessment of the sacral base/sulci and ILA prove helpful in determining sacral alignment, torsion and rotation around the vertical axis (Box 2.1; Figs 2.21, 2.71Gi,ii, 2.87-2.89).

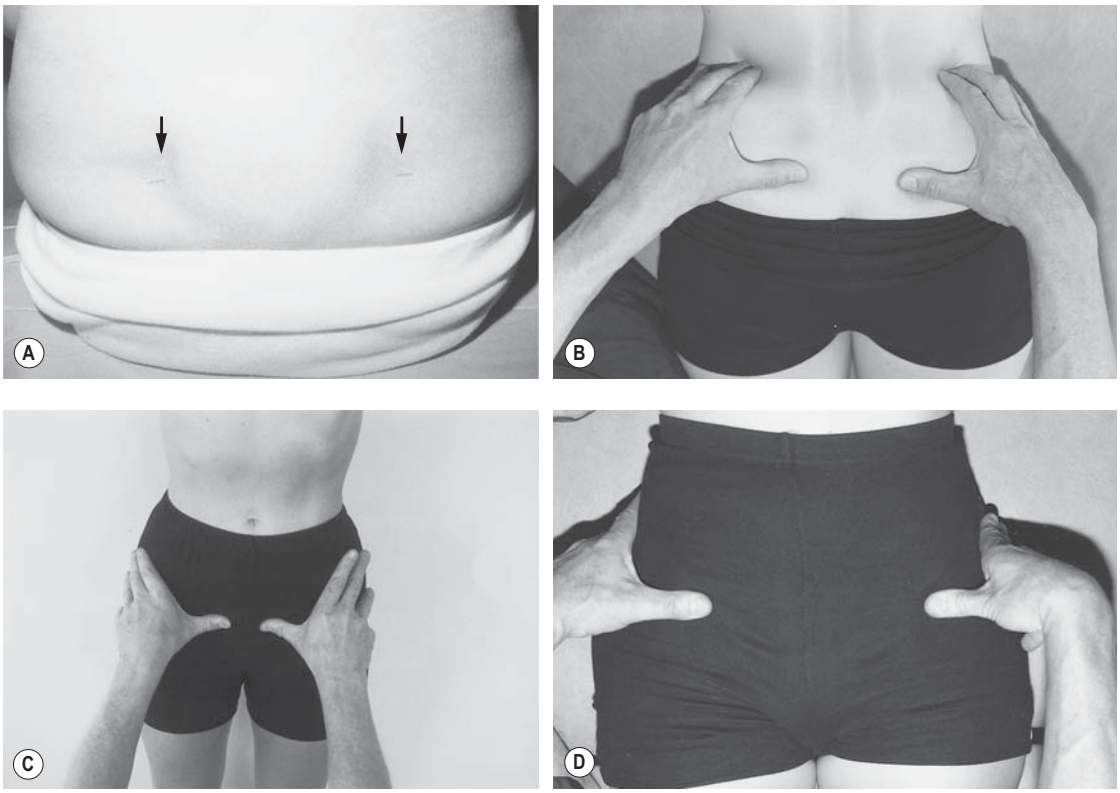

Fig. 2.71 Landmarks when the pelvis is aligned and the leg length equal. (A) 'Dimples of Venus', about 1 cm above the inner margin of the posterior superior iliac spine (PSIS) - see also Fig. 2.6A. (B) Fingers on the iliac crests, thumbs against the inferior aspect of the PSIS. (C) Superior pubic bones (thumbs resting on the superior aspect). (D) Anterior superior iliac spine (thumbs resting against the inferior aspect).

(Continued)

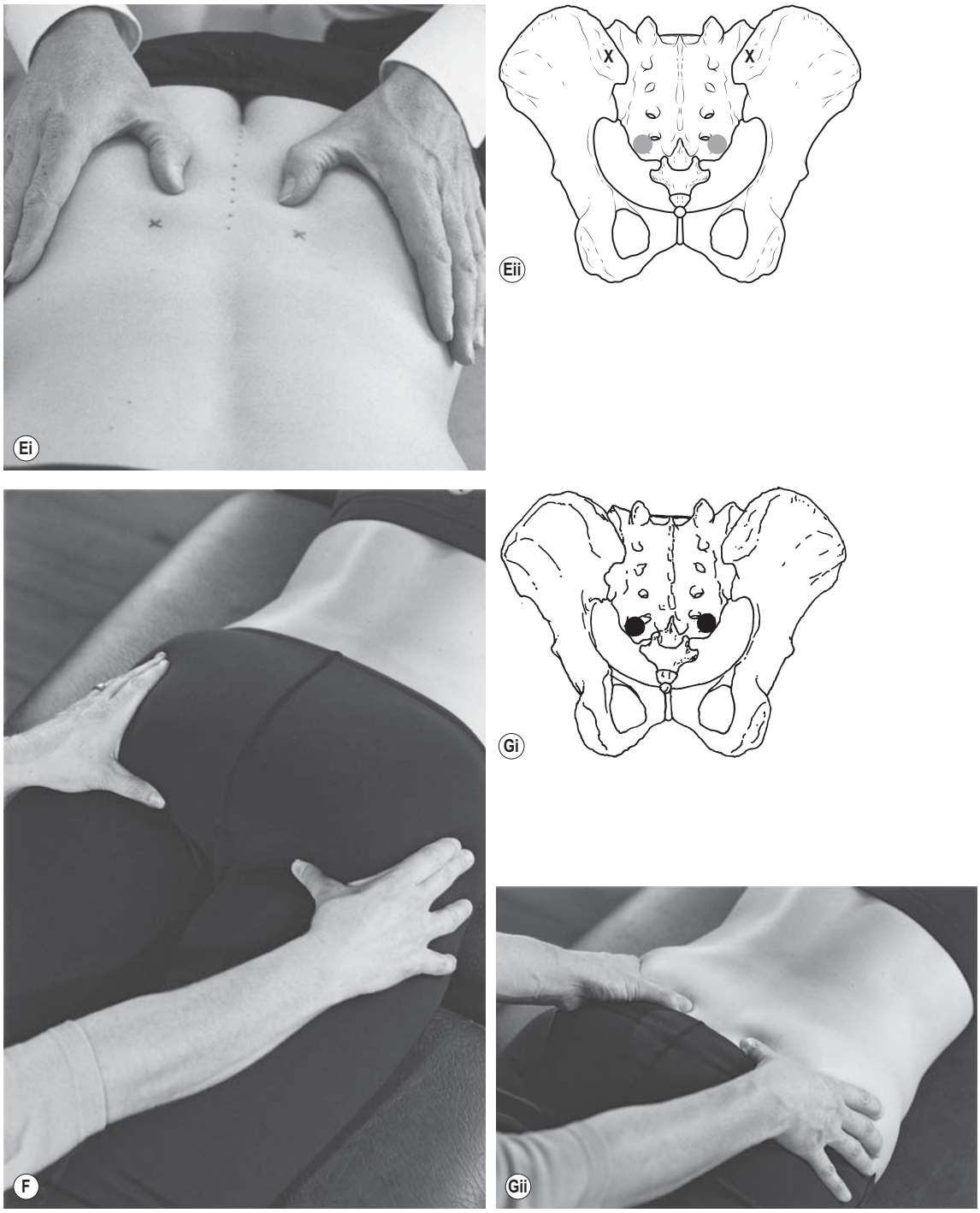

Fig. 2.71—cont'd (E) PSIS: i) thumbs resting against the inner aspect are equidistant from midline (broken line running upward from gluteal cleft) ii) 'X' marks the right/left PSIS. (F) Ischial tuberosities. (Gi,ii) Inferior lateral angle, at the S5 level. (Figs 2.71Eii, F,G: *Courtesy of © Diane G. Lee Physiotherapist Corp.)*

In standing

1. If the pelvis appears level, this suggests (but does not confirm) that the person has equal leg length and that there is no indication of 'rotational malalignment' and/or an 'upslip'; it does not rule out an underlying 'outflare/inflare' (Figs 2.71B,C; 2.72A)
2. If the pelvis is oblique, there could be:
   a. an anatomical (true) LLD (Fig. 2.72B), or
   b. a functional lengthening of the leg as the result of an 'upslip' or 'rotational malalignment' (Figs 2.73A-D).

In sitting and lying supine or prone

If the pelvis is now level, this suggests an anatomical (true) leg length difference as the cause of the obliquity seen in standing. The LLD itself will still be evident in prone and supine-lying but all the pelvic landmarks will now be symmetrical in these positions (Fig. 2.72B). If the pelvic obliquity persists when sitting, with the iliac crest now elevated either on the same side or opposite to what is seen in standing, pelvic malalignment is probably present (Figs 2.73A-D, 2.76B). A less likely cause is a side-to-side difference in the actual height of the innominates that may become evident after pelvic fracture(s) or with impaired development (e.g. a hemi-pelvis; Fig. 3.87).

BONY LANDMARKS OF THE PELVIS

In practice, assessment depending on comparison of the pelvic landmarks may not be entirely accurate because of imbalances in muscle tension or strength, congenital or acquired side-to-side differences of

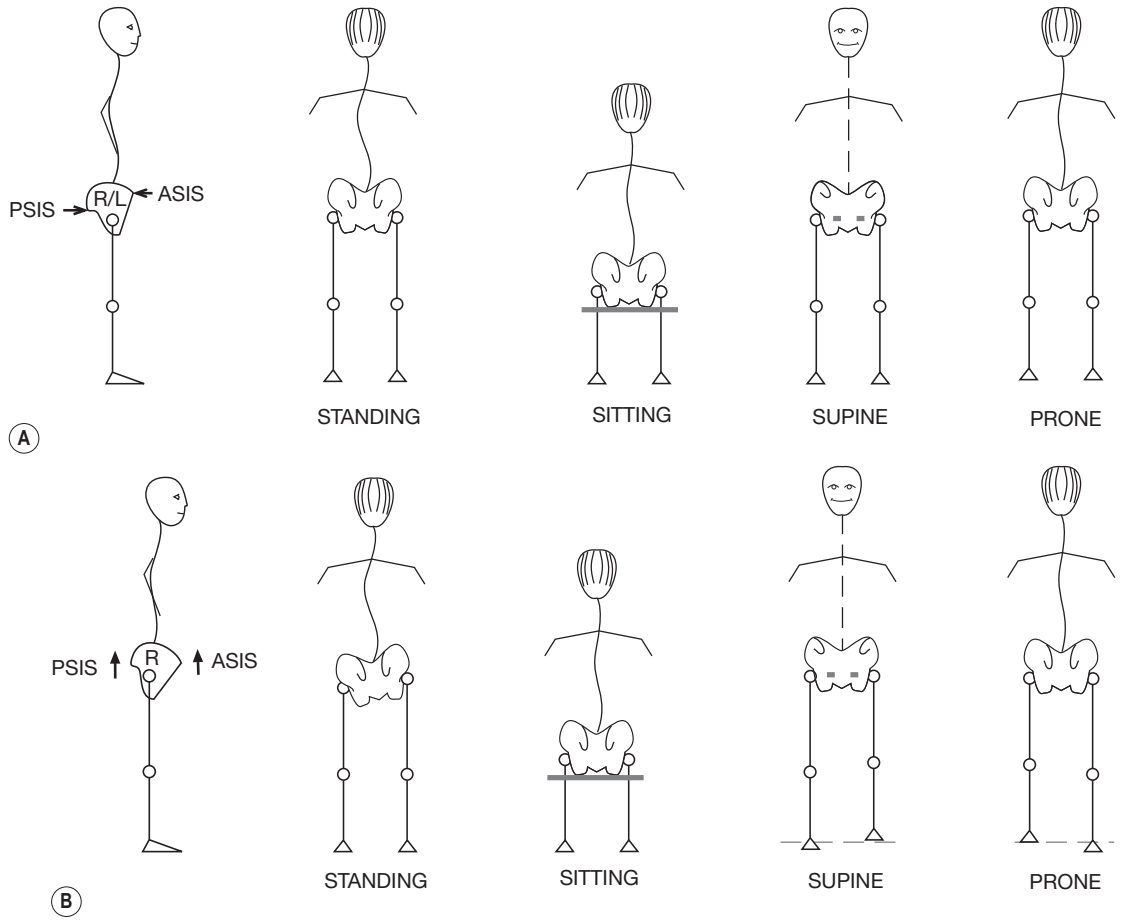

Fig. 2.72 Effect of leg length on the aligned pelvis. (A) Aligned: leg length equal. (B) Aligned: an anatomical (true) LLD (right leg long – pelvis up on right when standing, level sitting and lying). ASIS, anterior superior iliac spine; PSIS, posterior superior iliac spine.

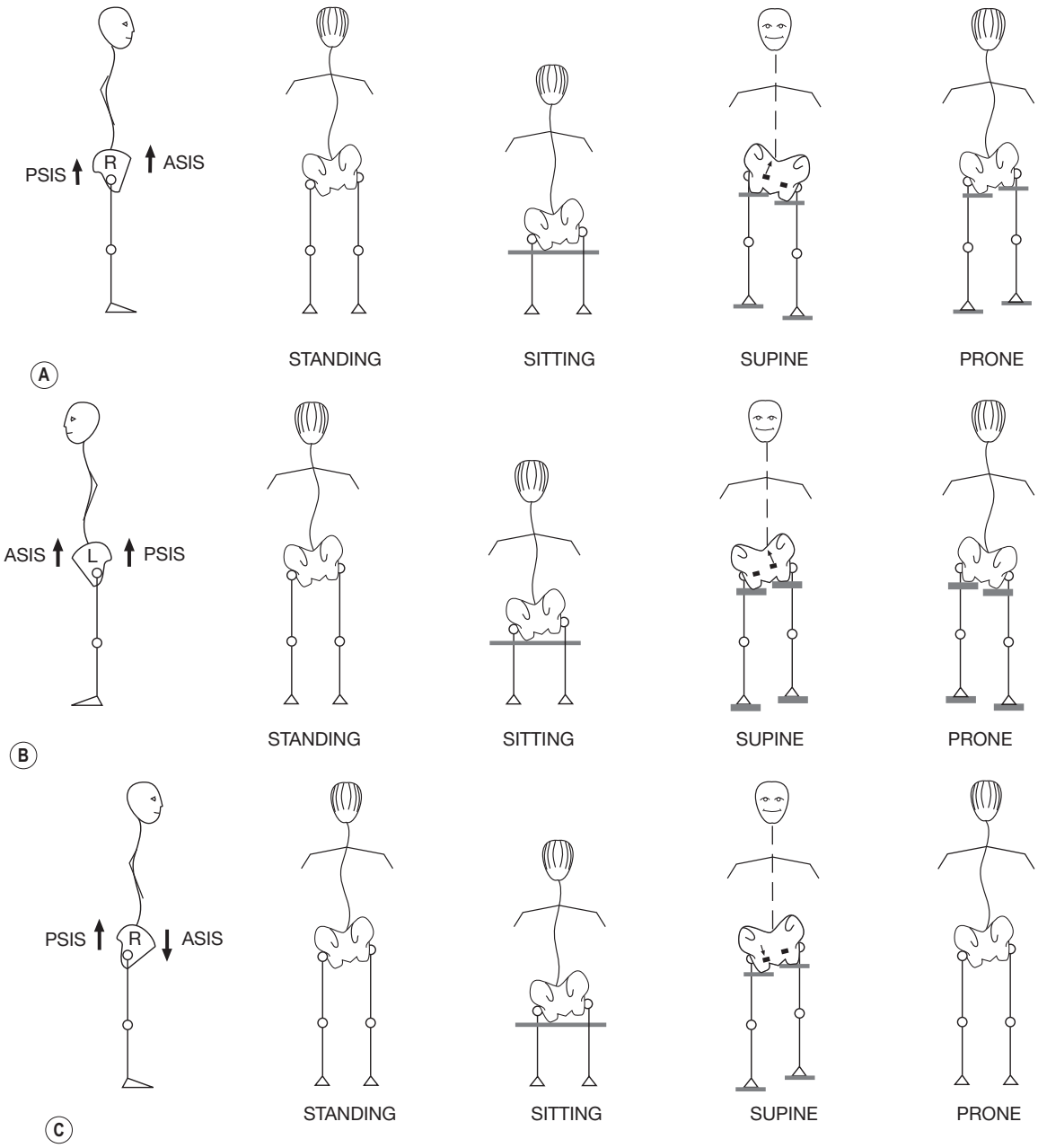

Fig. 2.73 Pelvic obliquity related to malalignment (some typical changes noted in standing, sitting, lying). (A) 'Right upslip' (all right pelvic landmarks are up in all 3 positions). (B) 'Left upslip' (right iliac crest often up in standing and sitting; left definitely up in lying). In both (C) 'right anterior rotational malalignment' (most common pattern) and

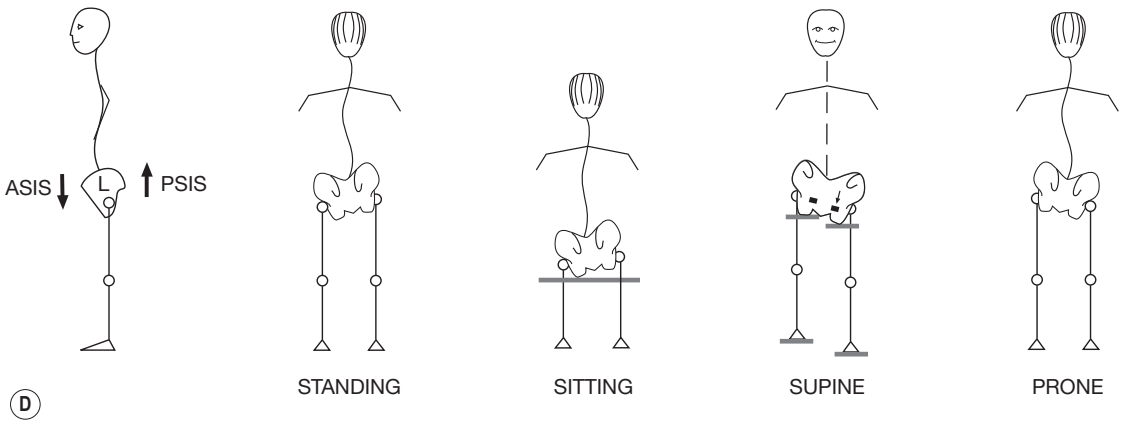

Fig. 2.73—cont'd (D) 'left anterior rotational malalignment' (less common pattern): all landmarks asymmetrical side-to-side, front-to-back. ASIS, anterior superior iliac spine; PSIS, posterior superior iliac spine.

bony contours, or a unilateral tendency to pronation or supination when weight-bearing.

> Attempts to establish the presence or absence of malalignment must never be limited to the assessment of landmarks alone but should be supplemented by the findings on examination for pelvic obliquity and leg length differences in various positions.

In alignment and with leg length equal

1. The iliac crests will be level when standing, sitting, and lying prone or supine (Figs 2.71, 2.72A).
2. The right and left ASIS and PSIS will be level when standing, sitting and lying. On a lateral view, the ASIS is positioned upward (craniad) relative to the PSIS by approximately the same amount on both sides.
3. The right and left superior and inferior pubic rami are level when lying supine or standing (Fig. 2.71C), the ischial tuberosities level in lying prone or standing (Fig. 2.71F).
4. The right and left ASIS and PSIS will be level in the coronal plane when assessed in supine- or prone-lying. Also, there is no rotation of the pelvis around the vertical axis (i.e. no rotation clockwise or counterclockwise; Fig. 2.9) or coronal axis (i.e. minimal or no tilting).

In alignment, with an anatomical (true) leg length difference

1. Only in standing are all landmarks elevated on the side of the long leg, with a uniform obliquity of the pelvic crests and superior pubic rami on clinical examination (Fig. 2.72B). A standing anteroposterior X-ray of the pelvis shows:
   a. a uniformly sloping obliquity of the sacral base, iliac crests and superior pubic bones, with no displacement of the innominates relative to the sacrum or of the pubic bones relative to each other
   b. a difference in the height of the femoral heads on standing views of the pelvis, which amounts to the true LLD (Fig. 2.74A).

Sacroiliac joint 'upslip'

On the side of the 'upslip', there is a simultaneous elevation of all the pelvic landmarks, anteriorly and posteriorly. Unlike in the case of the anatomical LLD, where the obliquity gradually slopes upward to the long-leg side in standing, one is dealing here with an obliquity that is actually disrupted on the side where the innominate has translated upward relative to the sacrum.

'Right upslip'

There is an upward displacement of the right ASIS, AIIS and pubic rami anteriorly, the PSIS and ischial tuberosity posteriorly (Figs 2.61A, 2.73A, 2.82). The

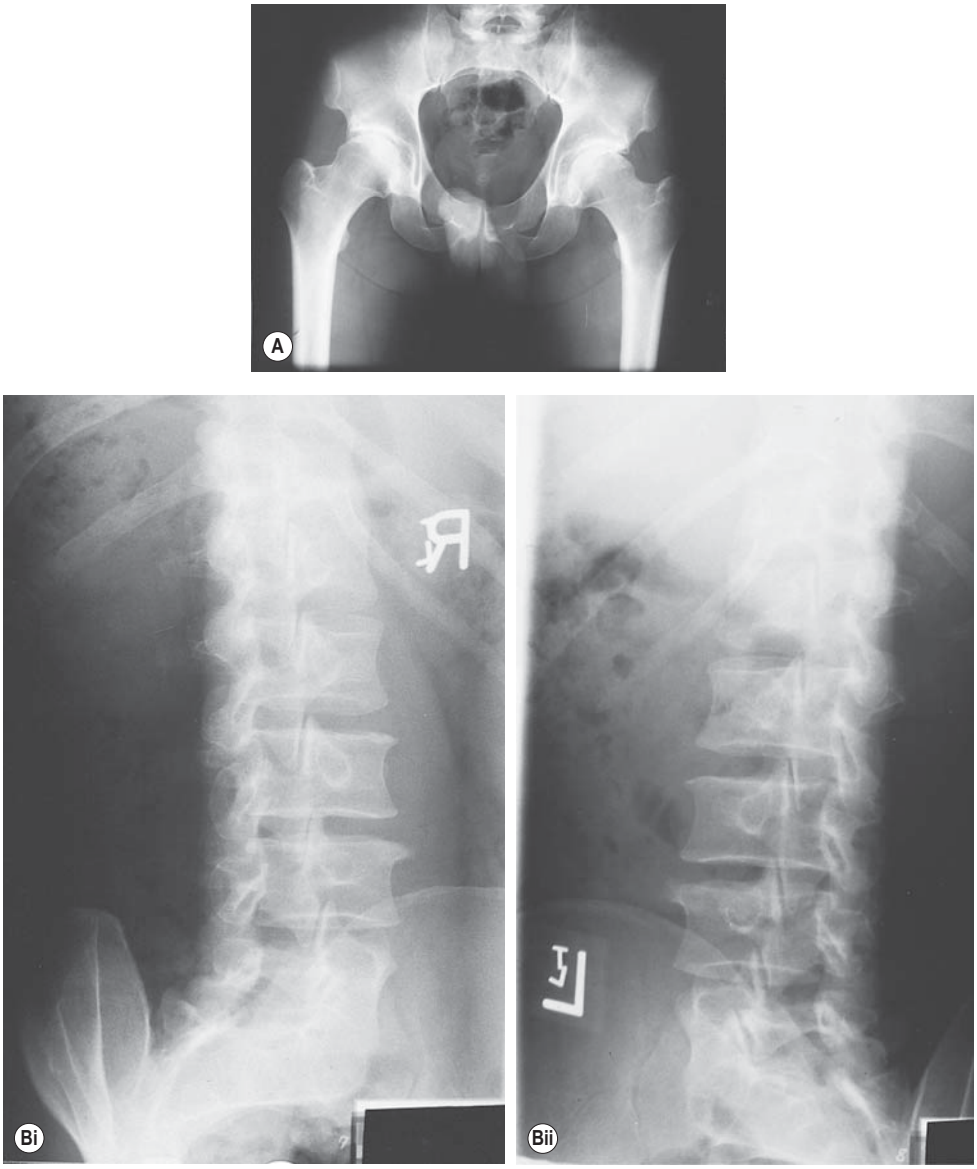

Fig. 2.74 X-ray: standing view of a person with anatomical (true) leg length difference - right leg long. (A) A-P view: right femoral head higher than left; note the uniform obliquity of the superior pubic rami (inclined to right; no displacement at symphysis pubis) and the similarity in appearance of R/L hip/sacroiliac joints and lesser trochanters. (B) (i) Right and (ii) left oblique views: the facet joints appear to be of uniform width except for right L4-L5, narrowed by what appear to be osteoarthritic changes.

right superior pubic ramus usually shifts upward by 3-5 mm, sometimes more, relative to the left one; this difference can be appreciated as a step deformity at the symphysis pubis on palpation and on X-ray. The right leg is pulled upward passively with the right innominate, so that it appears to be shorter than the left leg when the person is lying prone or supine (Fig. 2.73A); this shortening usually amounts to some 5-10 mm. In standing, however, the iliac crest is often elevated on the side of the 'upslip' so that the right leg appears to be the longer one in that position. In fact, this elevation of the right iliac crest

frequently persists during sitting, when the pelvis would be expected to tilt down on the right to fill the space between the ischial tuberosity and seating surface created by the right innominate having moved upward relative to the sacrum. This finding may be due to factors such as:

1. some rotation of the pelvis in the coronal plane
2. asymmetric increase in muscle tension or actual spasm, which should also be suspected whenever there is persistence of an 'upslip' (e.g. involving ipsilateral quadratus lumborum, psoas major/minor; Fig. 2.62)

'Left upslip'

The iliac crest often appears up on the right side in standing (as if the pelvis is dropping down with the left leg being 'short') and in sitting (as if to fill in the gap between the ischial tuberosity and surface). The 'upslip' is most easily appreciated on examination in the supine and prone positions, in which case the left leg is noted to be shortened and the left ASIS, PSIS, pubic bone, iliac crest and ischial tuberosity have translated upward along the vertical plane relative to the sacrum and these same landmarks on the right side (Fig. 2.73B).

'Rotational malalignment'

Anterior and posterior superior iliac spines (ASIS, PSIS)

With 'anterior' rotation of an innominate bone around the coronal axis in the sagittal plane, the ipsilateral PSIS moves upward (cephalad) and the ASIS and pubic bone downward (caudad); whereas on 'posterior' rotation, it is the ASIS and pubic bone that moves upward and PSIS downward. The anterior or posterior rotation of the innominate on one side is usually compensated for by the contrary rotation of the innominate on the opposite side, which has the effect of amplifying both the side-to-side and front-to-back asymmetry of the landmarks. One can usually make the diagnosis of a 'rotational malalignment' on the basis of this complete asymmetry of the ASIS and PSIS (Figs 2.42; 2.73 C,D; 2.76).

Pubic bones

With a 'right anterior, left posterior' innominate rotation, there will be rotational displacement of the pubic bones evident at the symphysis pubis:

1. the right pubic bone rotates anteriorly, the left posteriorly around the coronal axis
2. there is also some craniodaudal translation in the vertical plane, relative to each other: downward (caudad) with 'anterior', upward with 'posterior' rotation; there results a displacement at the symphysis pubis that is usually easily apparent both on clinical examination (Fig. 2.76C) and on anteroposterior X-rays of the pelvis (Fig. 2.75)

> In other words, as a result of either 'anterior' or 'posterior' rotation of one innominate, all the bony landmarks of the pelvis end up completely asymmetrical in all positions of examination, both on anterior-to-posterior and side-to-side comparison.

'Outflare and inflare'

The landmarks primarily used to detect an 'outflare' and 'inflare' are the ASIS, PSIS and midline markers such as the umbilicus and symphysis pubis anteriorly and gluteal crease posteriorly.

In someone who is in alignment

1. anterior assessment in supine-lying
   a. right and left ASIS are level in the coronal plane

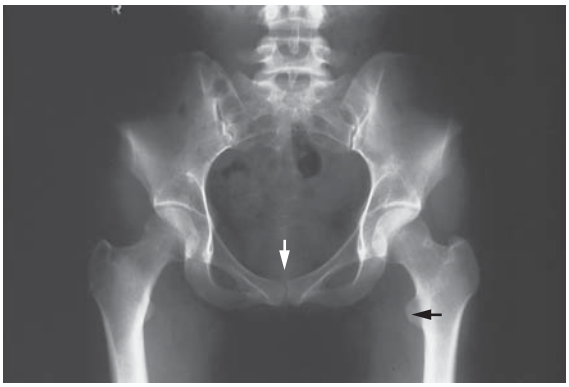

Fig. 2.75 X-ray: standing A-P view of the pelvis in a person with equal leg length and 'right anterior, left posterior' rotational malalignment. Note: (1) femoral heads level but pelvic crests oblique; (2) approximately 3 mm downward displacement of the right superior pubic ramus relative to the left at the symphysis pubis; (3) apparent asymmetry of the sacroiliac joints and lesser trochanters (the left appearing larger, the right smaller; compare with Figs 2.74A, 4.30A).

b. the thumbs placed on the tips of the ASIS are up an equal distance from the surface the person is lying on and a ruler or level ends up horizontal (Fig. 2.65)
c. right and left ASIS and PSIS are equidistant from centre (Figs 2.13Bii,Cii, 2.68, 2.69, 2.71Ei)
   i. anteriorly, one can use the umbilicus or an obvious central hairline (provided these have not been shifted off-centre by adhesions, scar tissue, organomegaly or masses), also the symphysis pubis, as a central marker (Figs 2.66-2.69)
   ii. the tips of the index or middle fingers meet in centre when the hands are rotated inward, with the thumbs anchored against the medial aspect of the ASIS to serve as a pivot point (Fig. 2.69)

2. posterior assessment in prone-lying
   - right and left PSIS are level in the coronal plane and equidistant from centre, with the gluteal crease usually serving best as a marker (Figs 2.13Cii; 2.71Ei)
3. the ASIS and PSIS and the pubic bones remain level in the coronal plane and there is no rotation around the vertical axis in the transverse plane on viewing the pelvis from front or back; therefore, there is no forward protrusion of the ASIS detectable on one side compared to the other when:
   a. lying prone or supine (Fig. 2.65)
   b. standing with the heels and back against the wall, or
   c. sitting with the buttocks and trunk pressed evenly into the back of the chair.

In someone with a 'right outflare, left inflare' (Figs 2.13, 2.64, 2.66):

1. the innominates have rotated clockwise around the vertical axis in the transverse plane
2. the right innominate flares outward, the left inward relative to the midline anteriorly
3. the right ASIS ends up away from centre in the supine position (Fig. 2.13Bi) and the right PSIS toward the centre when lying prone (Fig. 2.13 Ci); findings are reversed on the left side
4. a level shows the tip of the right ASIS to be comparatively lower (= 'outflare') than the left (= 'inflare') side in supine-lying (Figs 2.13Aiii; 2.64)
   - these same findings will also be evident in sitting and standing; in this example, a finger placed on the tips of the ASIS would show the left to be displaced forward, the right relatively backward in the transverse plane when the person or an examiner looks directly downward at the front of the pelvis

In someone with a 'right inflare, left outflare'

The opposite findings would be evident:

1. right ASIS is in toward, left away from the midline when lying supine; whereas right PSIS is out from and left in toward midline when lying prone
2. tip of right ASIS is higher, left lower on comparison, using a level or other technique

Diagnosis of 'outflare' and 'inflare' is simplified by the fact that, when lying supine and looking at the height of the tips of the ASIS:

RULE OF 4 'I's FOR DIAGNOSING AN 'INFLARE':

ASIS is 'HIGH' on the 'INFLARE' side and moved 'IN' toward the midline; treatment requires resisting attempts to push 'INWARD' with the knee on that side (**NOTE**: 4 words with an 'I' in them, demarcating that an 'INFLARE' is present on this side)

RULE OF 4 'O's FOR DIAGNOSING AN 'OUTFLARE':

ASIS is 'LOW' on the 'OUTFLARE' side and moved 'OUT' from the midline; treatment requires resisting attempts to push 'OUTWARD' with the knee on this side (**NOTE**: 4 words with an 'O' in them, demarcating that an 'OUTFLARE' is present on this side).

Treatment of 'outflare' and 'inflare' will be discussed in detail in Ch. 7.

'SITTING-LYING' TEST

This test affords an individual and those caring for patients a quick way of establishing whether malalignment is actually present and, if so, to find out whether there is a 'rotational malalignment', 'upslip', 'flare' or a combination of these, so that appropriate treatment can be initiated.

Leg length is compared by initially noting the level of the medial malleoli in the 'long-sitting' (sitting up with legs out in front, knees extended) and then 'supine-lying' positions (Figs 2.77A, 2.78A). Trying to compare the high points of the malleoli is sometimes diffcult, especially if the malleoli are

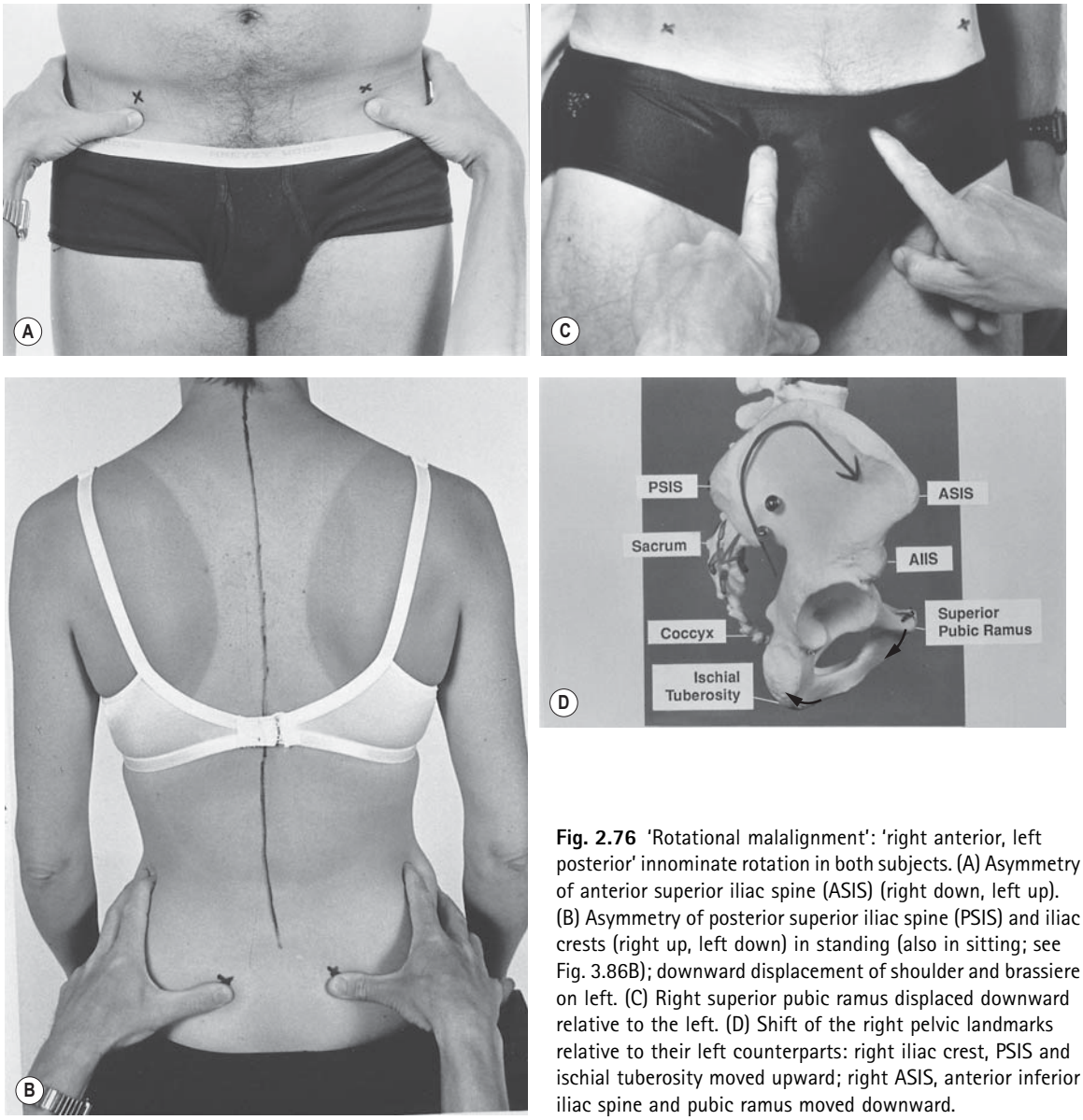

Fig. 2.76 'Rotational malalignment': 'right anterior, left posterior' innominate rotation in both subjects. (A) Asymmetry of anterior superior iliac spine (ASIS) (right down, left up). (B) Asymmetry of posterior superior iliac spine (PSIS) and iliac crests (right up, left down) in standing (also in sitting; see Fig. 3.86B); downward displacement of shoulder and brassiere on left. (C) Right superior pubic ramus displaced downward relative to the left. (D) Shift of the right pelvic landmarks relative to their left counterparts: right iliac crest, PSIS and ischial tuberosity moved upward; right ASIS, anterior inferior iliac spine and pubic ramus moved downward.

uneven in contour developmentally or as a result of injury, not very prominent or quite a distance apart (as seen, for example, in a person with 'knock-knees' or genu valgum). It is much easier, and more accurate, to compare the level of the thumbs placed in the hollow immediately below the medial malleolus on each side, directly overlying the medial ankle ligaments (Figs 2.77B, 2.78B). Point the tip of each thumb straight downward (distal phalanx vertical) so that you are now comparing the relative level of your interphalangeal joints (i.e. knuckles) which end up closer together and are more clearly demarcated than the malleoli, making side-to-side comparison more accurate. Remember to hold onto the ankles lightly - the thumbs are only serving you as a guide to compare side-to-side leg movement and length on sitting and lying. A common mistake is to hold on forcefully, at the risk of impairing free upward and downward movement of the legs, making the person tense up or causing actual discomfort.

Fig. 2.77 Sitting part of the 'sitting-lying' test in male subject. (A) Long-sitting. (B) Left leg appears longer than the right.

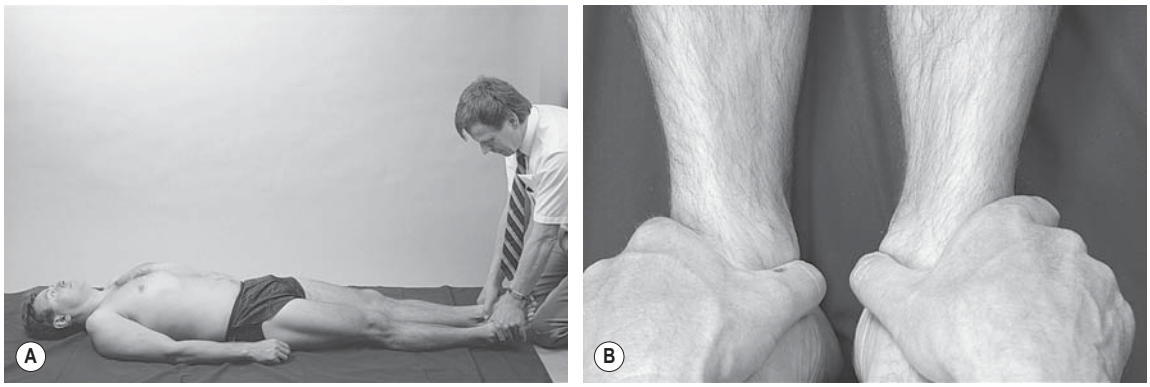

Fig. 2.78 Lying part of the 'sitting-lying' test in same subject. (A) Supine-lying. (B) There has been a shift in the leg length: the right leg has lengthened relative to the left leg (findings the reverse of those noted in Fig. 2.77B).

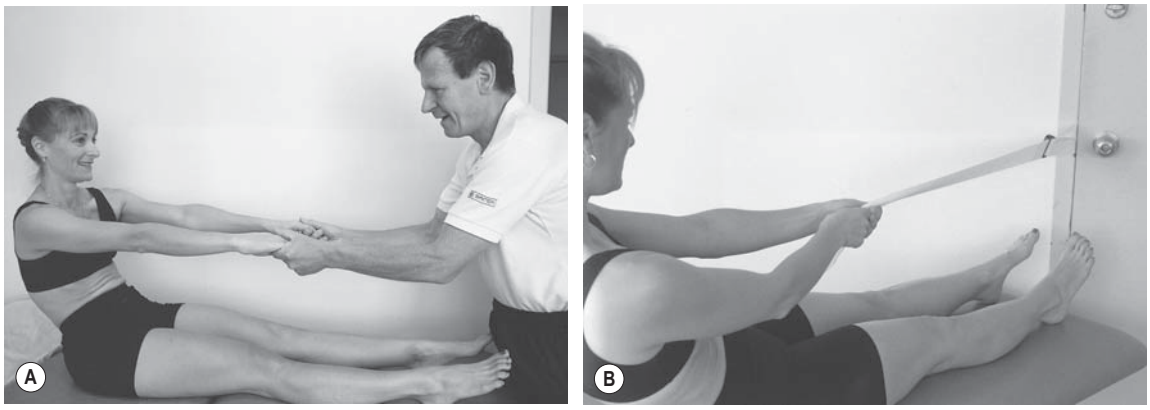

Fig. 2.79 'Sitting-lying' test: assisting sitting up to minimize contraction of any other muscles attached to the pelvic ring and decrease any error. (A) Assisted by a second person. (B) Subject using a strap or rope to pull up on (and let herself down with) while concentrating on detecting a leg length difference and any shift of the feet relative to each other on changing position.

At home, the test is best performed with the person lying on a firm bed, carpeted floor or even a table; a soft surface could interfere with the comparative movement of the legs on changing position from sitting to lying and may allow the pelvis and trunk to sink down unevenly. The heels must be able to slide without hindrance. If one or other heel gets caught up on the surface it will, in turn, shift the pelvis on that side and make the test invalid. A sheet covering the plinth or a towel placed under the heels will prevent them getting caught up on a vinyl or leather surface, especially if they are sweaty; alternately, the person can just keep their socks on for this test. If a smooth surface is not available at home, try lying on the floor; when out on the field, place a jacket under the heels, the smooth lining facing upward, which should allow the feet to move upward and downward more easily.

The person initially lies supine and is then asked to sit up. A shift of the pelvis or other error is less likely if the person avoids, as much as possible, activating leg, pelvic or trunk muscles that can influence movement of the pelvis; this can best be achieved:

1. on a 2-person test: having someone assist by holding on to the person's outstetched hands and gently pulling him/her up (Fig. 2.79A)
2. on a 1-person test: by pulling oneself up hanging on to a belt, strap or other anchored support (Fig. 2.79B).

During the motion of sitting up, concentrate on the movement of the feet - are the legs moving downward together (i.e. both lengthening)? Once you are sitting up, establish the relative leg length - are they the same length or is one leg longer than the other? The next step is to lie down, with the examiner's assistance or the aid of the support, while concentrating on whether:

1. the legs move upward together (i.e. shorten at the same rate)
2. if there is a short leg in sitting and the legs move up together on lying, is that leg short the same amount in both the sitting and lying positions?
3. one leg lengthens, the other shortens; that is, is there a shift in the relative leg length which reverses again on sitting up?

The manoeuvre is best repeated one or two times for confirmation of the findings observed initially. Sometimes initial findings may not match up with other changes detected on examination (e.g. shift of landmarks in a pattern typical of an 'upslip', 'outflare/inflare' or 'rotational malalignment') but, on repeat testing, are seen to change in a way that is consistent with the presentation of malalignment suspected as the person starts to relax and the pelvis and legs can move more freely. If a shift in length are suspected to be occurring on going from one position to another but proves hard to detect, consider doing the following:

1. with the person in long-sitting
   - using a ball-point or felt pen, make marks on the skin or socks directly adjacent to each other on the inside of the feet at the part where they come closest together; e.g. at the malleoli or the medial aspect of the 1st MTP joint (base of the first toe)
2. on lying-down
   a. does a difference in leg length become apparent, with the right and left marks separating?
3. if the marks did separate on lying down and the person then sits up:
   a. does this difference persist but remain exactly the same?
      - this would be in keeping with either an 'upslip' or a 'true' LLD)
   b. does the shift in the marks reverse, so that they come to match up again the way they were when initially drawn in sitting?
      - this would be in keeping with the shift that occurs with 'rotational malalignment'
4. are these findings consistent on repeating the 'sitting-lying' test once or twice?

Clinical correlation: 'sitting-lying' test

Barring excessive tension or contracture in the pelvic and hip girdle structures (e.g. unilateral contracture of quadratus lumborum or psoas major/minor pulling up on the ipsilateral innominate, with seeming 'shortening' of that leg; Fig. 2.62), the more common presentations on the 'sitting-lying' test are those described below.

Aligned, leg length equal

In supine-lying, the acetabula lie anterior and up (craniad) relative to the ischial tuberosities (Fig. 2.80A). On moving into the long-sitting position, flexion

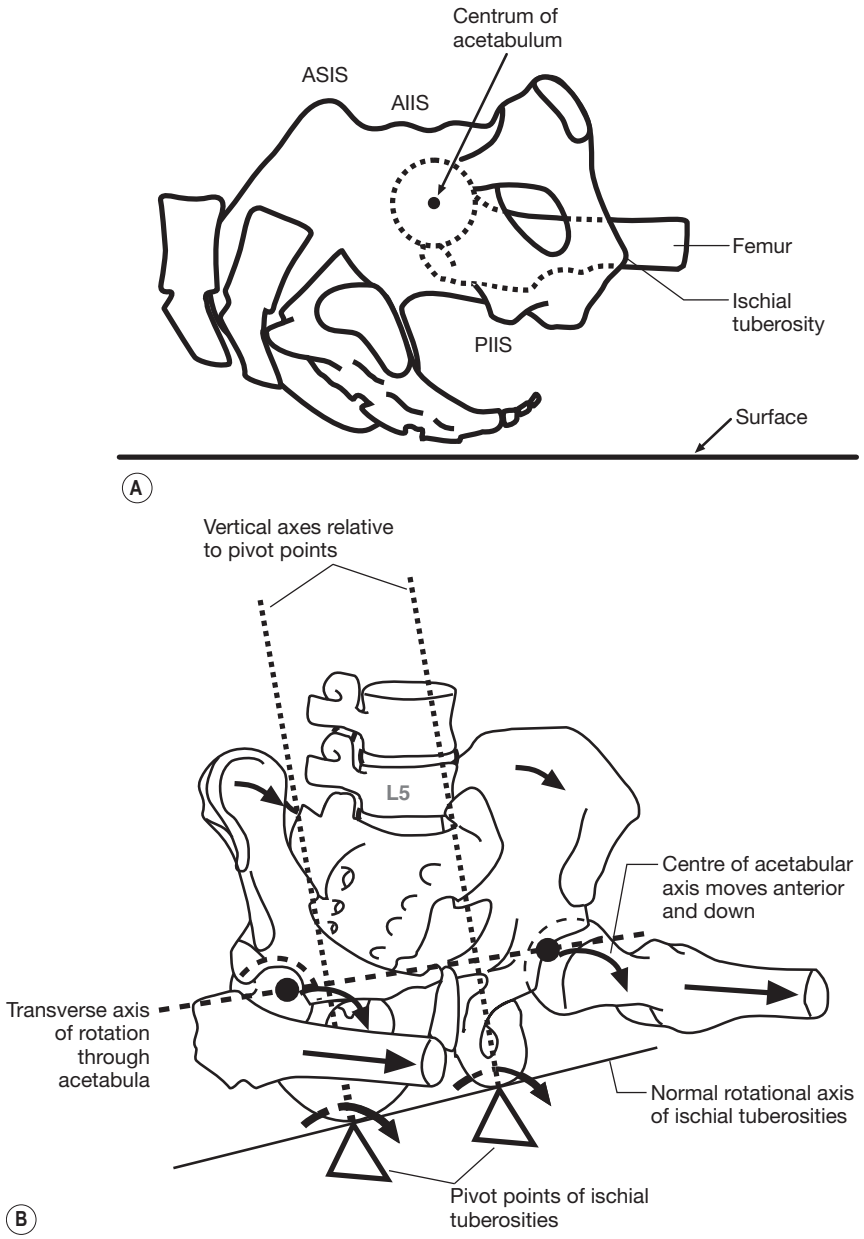

Fig. 2.80 'Sitting-lying' test: aligned, leg length equal and all landmarks symmetrical. (A) Supine-lying: the acetabula lie anterior and craniad relative to the ischial tuberosities. (B) Moving into long-sitting: the innominates pivot over the ischial tuberosities and the acetabula move forward and caudad, causing the legs to lengthen equally. ASIS, anterior superior iliac spine; AIIS, anterior inferior iliac spine; PIIS, posterior inferior iliac spine. *(Redrawn courtesy of DonTigny 1997.)*

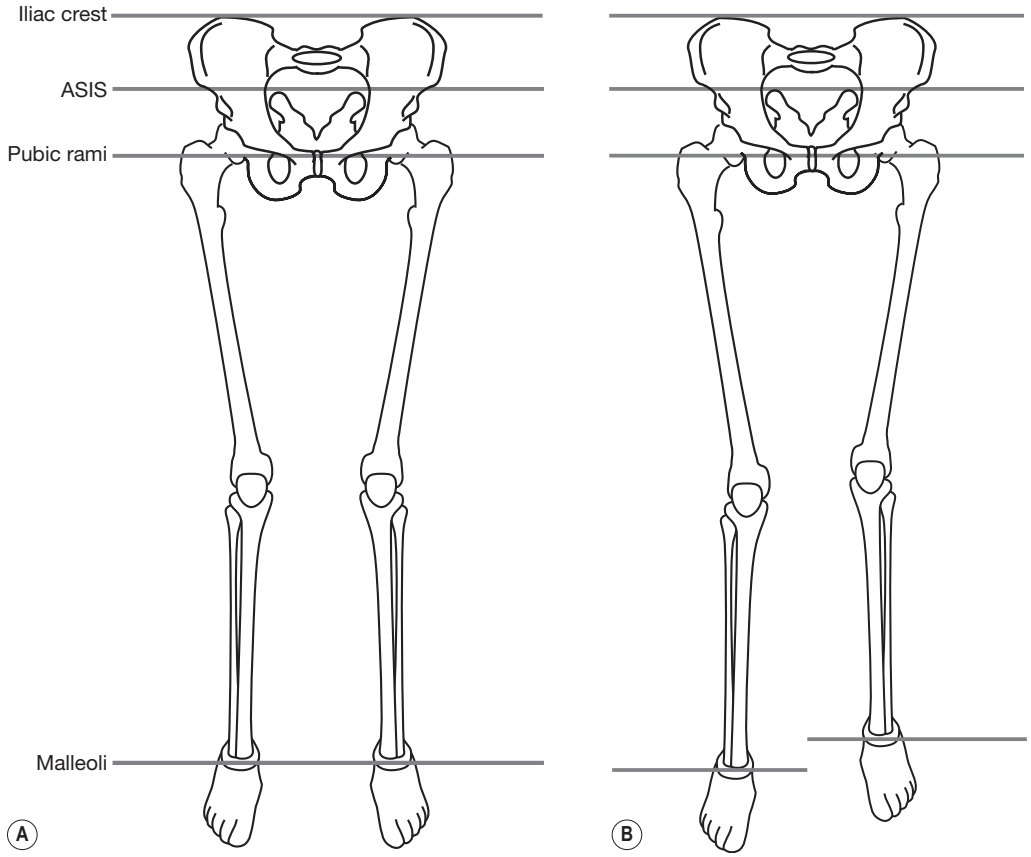

Fig. 2.81 'Sitting-lying' test: in alignment, the pelvic landmarks on the right match all those on the left. (A) Leg length equal: the malleoli match in sitting and lying. (B) Anatomical (true) leg length difference: right leg longer to the same extent in both sitting and lying. ASIS, anterior superior iliac spine.

occurs initially in the thoracic and then the lumbar spine, at which point the pelvic unit starts to tilt forward and eventually pivots over the now weight-bearing tuberosities as one unit. The acetabula are, therefore, moved even further anteriorly and also downward (caudad) so that the legs appear to lengthen to an equal extent (Fig. 2.80B). On returning to supine-lying, the pelvis tilts backward as one unit, the acetabula are moved in a posterior direction and upward (craniad) and the legs appear to shorten, again to an equal extent. The feet, therefore, move together: downward as the person assumes the long-sitting position, upward on supine-lying. The examiner's thumbs in the hollows just below the malleoli will match exactly in both positions (Fig. 2.81A). The pelvic landmarks are also all symmetrical in both prone and supine-lying (Figs 2.71, 2.72A).

'Outflare' and 'inflare'

Leg movement and lengthening/shortening are as for 'aligned, leg length equal', provided there is no coexistent true LLD and/or associated 'upslip' or 'rotational malalignment'. In other words, the legs are of equal length and move together, downward on long-sitting and upward on supine-lying.

Aligned, anatomical (true) leg length difference present

One leg is longer than the other (Fig. 2.72B). The pelvis, however, still rotates forward and backward around the coronal axis in the sagittal plane as one unit on long-sitting and supine-lying, respectively. Therefore, the legs and feet move downward and upward together and no change occurs in the length of either leg - the difference between the malleoli corresponds to the 'true' LLD and remains the same in both positions (Fig. 2.81B). All the pelvic

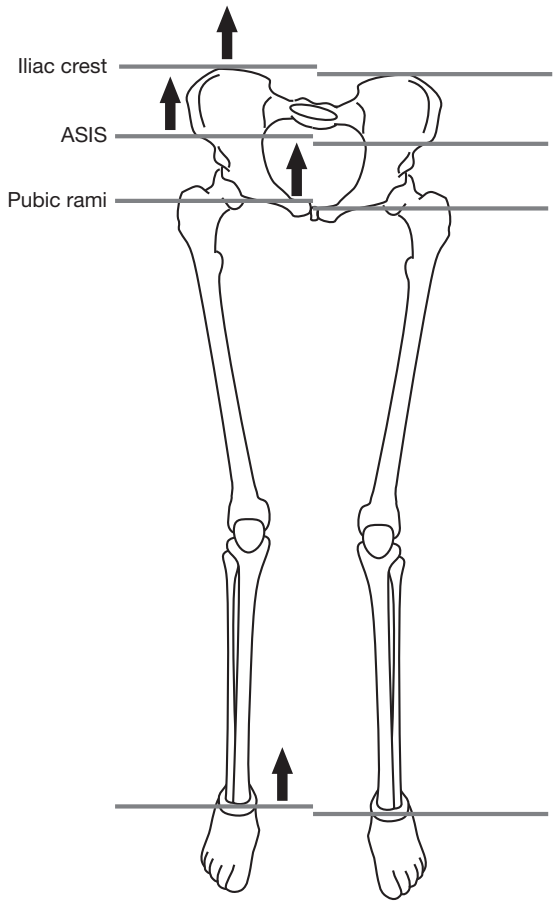

Fig. 2.82 'Sitting-lying' test: right sacroiliac joint 'upslip'. The right leg remains short to an equal extent in sitting and lying; the right anterior and posterior pelvic landmarks are all displaced upward on the right side relative to the sacrum and left innominate. ASIS, anterior superior iliac spine.

landmarks are higher on the side of the long leg in standing but level when sitting and lying.

Sacroiliac joint 'upslip'

With a 'right upslip', the right innominate is shifted straight upward (craniad) relative to the sacrum (Figs 2.73A, 2,82). The pelvis continues to move as one unit so that the legs still lengthen and shorten to an equal extent on long-sitting and supine-lying, respectively. The right leg will, therefore, appear to be shorter in both positions by at least the amount of relative upward shift that has occurred. However, that difference may be accentuated considerably by any reactive increase in tension of muscles in the ipsilateral flank and hip girdle region (Fig. 2.62). Similar to the situation with an anatomical LLD, the malleoli do not match, the difference remains the same in sitting and lying, and the feet move downward and upward together. The right anterior and posterior innominate landmarks, however, have all moved upward (craniad) (Figs 2.61A, 2.73A). The findings are the opposite for a 'left upslip' (Fig. 2.73B).

Sacroiliac joint 'downslip'

In the case of a 'right downslip', the right innominate will have moved downward relative to the sacrum, the right leg will be consistently longer in both long-sitting and supine-lying, and all the innominate landmarks on the right side will be displaced downward (caudad) relative to those on the left in both the supine and the prone position. The findings are the reverse for a 'left downslip'.

'Rotational malalignment'

When the person is in alignment, also with a 'true' LLD, 'upslip' or 'outflare/inflare' present, the pelvic ring moves as one unit on changing from sitting to lying or the reverse - any rotation around the SI joints is symmetrical. On sitting up, the pelvis pivots over the ischial tuberosities and rotates uniformly around an axis running through the acetabulae, causing them to move anterior and caudad so that the two legs lengthen to an equal extent (Fig. 2.80B).

With 'rotational malalignment', the pelvis no longer moves as one unit - there is now contrary rotation of the innominates around the coronal axis in the sagittal plane on sitting and lying. Assuming that the sacrum itself is still aligned (i.e. no sacral torsion, excessive nutation or counternutation), the following are the findings seen with:

'right anterior, left posterior' innominate rotation

1. in supine-lying
   Weight bearing is primarily on the dorsum of the sacral and coccygeal part of the pelvis (Fig. 2.80A). With the contrary rotation of the innominates, the right acetabulum will have been displaced downward (caudad) and posterior, the left upward (craniad) and anterior. There results a relative lengthening of the right and shortening of the left leg.
2. on moving up into the long-sitting position (Fig. 2.83), pressure is eventually exerted on:
   a. the anterior aspect of the ischial tuberosity of the right innominate, resulting in further

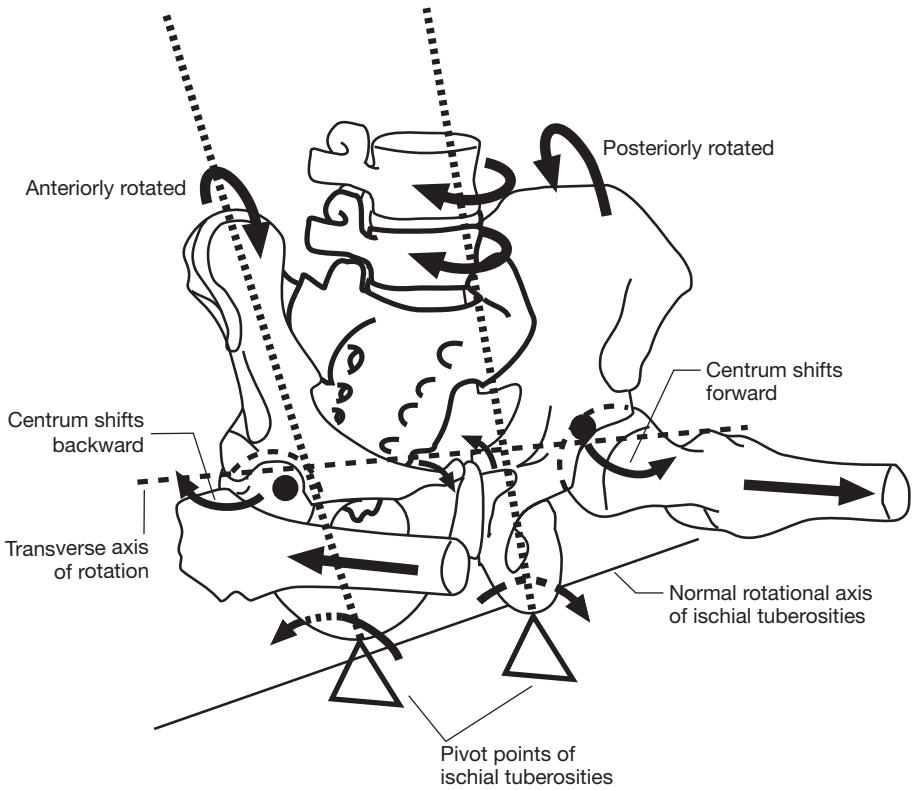

Fig. 2.83 'Sitting-lying' test: 'rotational malalignment'. Innominates have pivoted in contrary directions (right anterior, left posterior) and right ischial tuberosity is raised off the plinth, subjecting the left to increased weight-bearing. Centrum of each acetabulum moves in an opposite direction relative to the vertical and coronal axes, causing the right leg to shorten and the left to lengthen on long-sitting; the reverse occurs on supine-lying. *(Redrawn courtesy of DonTigny 1997; see also Fig. 2.80.)*

'anterior' rotation around the coronal axis to the point that the acetabulum is moved craniad, pulling the right leg up with it so that it appears to shorten

b. the posterior aspect of the ischial tuberosity of the left innominate, resulting in further 'posterior' rotation to the point that the acetabulum moves caudad, pushing the left leg downward so that it appears to lengthen

Pressure on these sites also causes some clockwise rotation of the pelvic unit around the vertical axis in the transverse plane, augmenting the apparent shortening of the right, lengthening of the left leg on sitting up.

In other words, there results a difference in leg length that changes on going from lying to sitting and the reverse. With a 'right anterior, left posterior' rotation:

1. on sitting up, there will be a relative lengthening of the left and shortening of the right leg; whereas
2. on lying supine, the reverse occurs so that the right leg now lengthens and the left shortens (Fig. 2.84).

'left anterior, right posterior' rotation

Findings opposite to those described above will be observed in someone with this pattern of 'rotational malalignment'.

If the innominates are indeed 'fixed' in a 'right anterior, left posterior' rotation:

1. the right superior iliac crest will now be higher than the left, with an obvious gap under the right ischial tuberosity and the seating-surface; whereas the left crest is lower so that the left ischial tuberosity ends up bearing more weight (Figs 2.73C, 6.4A,C)
2. not only does the right '**leg lengthen lying**' but there will also be a concomitant downward (caudad) displacement of the right anterior landmarks; i.e. the right anterior **landmarks are lower** (while those on the left will have moved upward) - the side-to-side difference is most easily discerned on comparison of right versus left ASIS and superior pubic bones (Fig. 2.76A,B). These changes, which together are indicative of the side of an 'anterior' rotation, are easily remembered by **'THE RULE OF THE 5 'L's**.

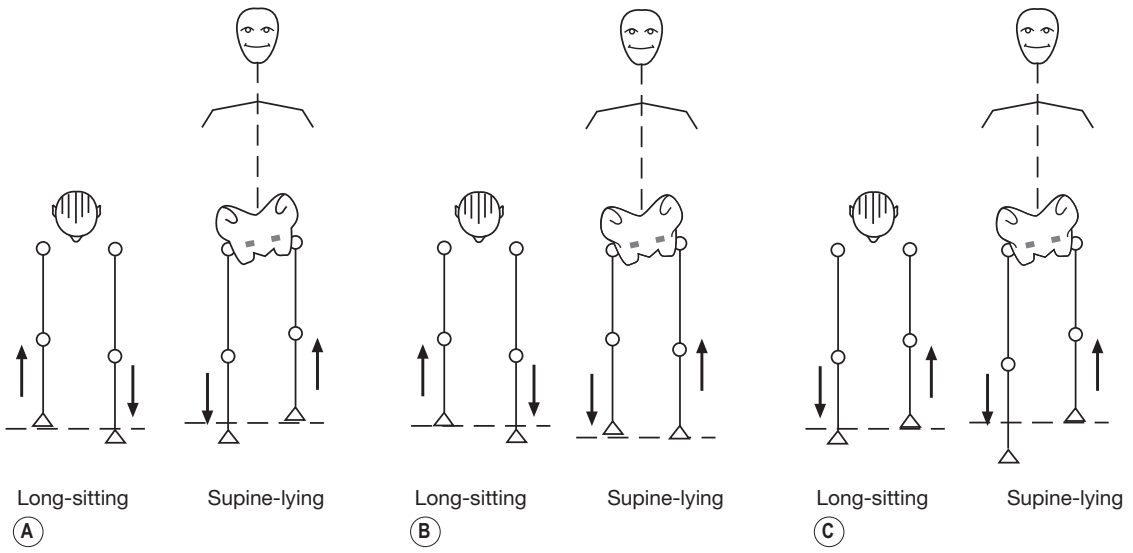

Fig. 2.84 'Sitting-lying' test: 'rotational malalignment' presentation. Suspect 'right anterior, left posterior' innominate rotation in all three cases, given the lengthening of the right leg relative to the left on moving from long-sitting to supine-lying. Note the asymmetry of the pelvic landmarks. (A) The right leg is shorter sitting, longer lying; this is the most common pattern. (B) The right leg is shorter sitting and still shorter, but less so, lying. (C) The right leg is longer sitting and, even more so, lying.

'THE RULE OF THE 5 'L's:

'**L**EG **L**ENGTHENS **L**YING, **L**ANDMARKS **L**OWER' = the side of the 'anteriorly' rotated innominate

Always keep in mind that there is just an apparent change in leg length on this test when 'rotational malalignment' is present. The emphasis is on detecting whether a shift occurs: any 'relative' shortening and lengthening of the legs on side-to-side comparison. For example, the right leg may be:

1. shorter than the left in sitting but longer in lying (Fig. 2.84A)
2. shorter than the left in sitting, still shorter but to a lesser extent in lying (Fig. 2.84B)
3. longer in sitting and even more so in lying (Fig. 2.84C).

In all three cases, there has been a relative lengthening of the right leg, consistent with a 'right anterior' rotation which could then be verified by noting that in each of these cases there is also asymmetry of all the landmarks on both anterior-to-posterior and side-to-side comparison, the anterior landmarks being lower on the right compared to left side (Fig. 2.76). In someone with a 'left anterior, right posterior' rotation, the opposite leg length changes and pelvic asymmetries would be evident (Figs 2.73D, 2.85).

An underlying 'true' leg length difference will influence which leg actually ends up appearing longer or shorter in the long-sitting or supine-lying position when malalignment is present. However, at this point, the asymmetry of all the landmarks makes it impossible to discern the true leg length other than by a comparison of the femoral heads on a standing anteroposterior X-ray view of the pelvis (Figs 2.74A, 2.75). This problem is discussed in more detail under 'Functional leg length difference' in Ch. 3.

The difference in leg length detected on moving from one position to the other may be less than 5 mm or as much as 25-40 mm; most will show a change of about 5-10 mm. It must again be emphasized that when carrying out the 'sitting-lying' test, the actual length of either leg, or which leg is longer or shorter, is not what matters in the presence of a 'rotational malalignment'. What does matter is that:

1. there is a 'shift' - a relative change in leg length, suggesting 'rotational malalignment' is probably present
2. the right foot moves in a direction contrary to the left on this test

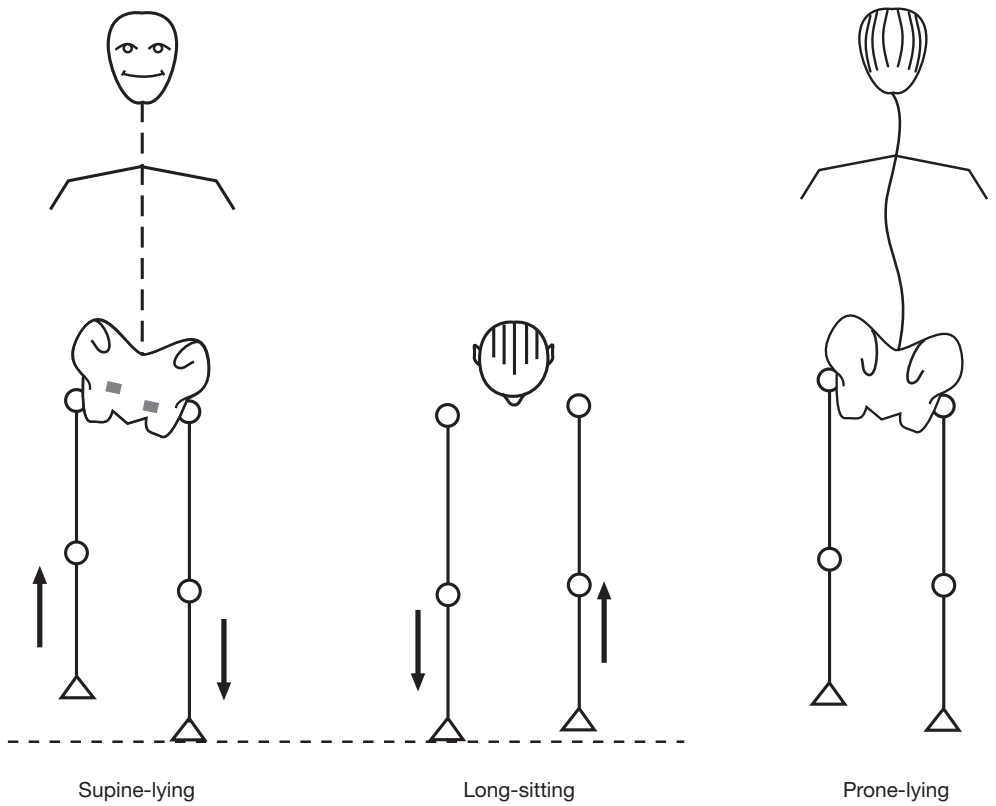

Fig. 2.85 'Sitting-lying' test: 'rotational malalignment'. Probable 'left anterior, right posterior' innominate rotation; confirm this by checking for asymmetry of pelvic landmarks; on side of 'anterior' rotation: Leg Legthens Lying, Landmarks Lower.

3. the side on which there is a relative lengthening of the leg on lying supine is likely to be the side of an 'anterior' rotation but this should always be confirmed by verifying that the anterior innominate landmarks on this side are, indeed, lower
4. all the pelvic landmarks are asymmetrical on anterior-to-posterior and side-to-side comparison in all positions of examination: standing, sitting and lying.

These four findings are pathognomonic of 'rotational malalignment'. However, false positives can occur with the 'sitting-lying' test for a number of reasons in a person who is actually in alignment and whose legs should lengthen and shorten to an equal extent on sitting and lying, respectively. For example:

1. Tightness of right gluteus maximus or hamstrings could impair anterior rotation on this side on sitting; if the left still rotates anteriorly normally, the left leg might appear to lengthen relatively more in sitting, then shorten on lying, so that it mistakenly appears that the right 'leg lengthened lying'
2. Tightness of right iliopsoas/rectus femoris could impair the normal posterior rotation of the right innominate on supine-lying. Pelvic tilt anteriorly is not impaired, so that the legs can lengthen the same amount on sitting-up. However, because right innominate posterior rotation is impaired by the tight muscles, there is relatively more left posterior rotation. The left leg will appear to shorten more than the right, again giving the mistaken impression that the right 'leg lengthened lying'.

In both cases, the 'sitting-lying' test suggests that, relatively, the right 'leg lengthened lying', giving the false impression that one is dealing with a 'right anterior, left posterior rotational malalignment'. However, the pelvic landmarks would be symmetrical and there would be no evidence of any findings typical of the 'malalignment syndrome' (Ch. 3).

It is for this reason that one must always check the position of the major landmarks (ASIS and pubic rami anteriorly; iliac crest, PSIS and ischial tuberosity posteriorly) to confirm the impression gained on the 'sitting-lying' test. To summarize, in regard to malalignment, the differential diagnosis to consider:

1. **when one leg is shorter by an equal amount in both sitting-up and lying-down**
   a. a 'true' LLD - all the landmarks are aligned; Fig. 2.81B)
   b. an 'upslip' - all these landmarks, both anterior and posterior, have moved upward on the side of the 'upslip' (Fig. 2.82)
2. **when leg length is equal**
   a. a pelvis in alignment - the landmarks are all symmetrical; Fig. 2.71)
   b. an 'outflare/inflare' presentation - there is counter- or clockwise rotation of these landmarks in the transverse plane and displacement relative to the centre (Figs 2.13, 2.64-2.68)
3. **when leg length shifts**
   a. suspect a 'rotational malalignment' (landmarks all asymmetrical) but
   b. rule out the person is not sitting or lying slightly asymmetrically with a wallet or other object in a back pocket or on account of a break in the plinth (Figs 2.107A, 2.108A, 2.114, 2.128, 2.129, 3.20A).

In order to reduce error, try to carry out the assessment of the landmarks in the same way each time, following the procedure outlined in Box 2.4. Which eye is dominant (Point 2, below) can usually be established quite easily:

1. hold up an index finger just in front of your nose so that it overlies a narrow mark, sign or other object some 5–10 meters away (e.g. fire alarm, clock, power pole).
2. close your left eye, leaving the right one open:
   a. if your index finger continues to overlie the object, you are probably right-eye dominant
   b. if your index finger moves to one side of the object, see what happens when you now close your right eye and leave the left one open
      - if the finger continues to overlie the object, you are probably left-eye dominant
3. if your finger shifts away from the object on closing either eye, consider your 'more dominant' eye to be the one that causes the lesser amount of shift when it alone is open

Therefore, if you are right-eye dominant:

1. approach the person with your right side adjacent to his or her side, whether they are lying supine or prone (Figs 2.66-2.69)

BOX 2.4 Assessing the anatomical landmarks

1. Whenever possible, face the person's front or back directly (Figs 2.76, 2.93, 2.95).
2. If this is not possible, try to approach the person so that you can place your dominant eye as close to his or her midline as possible (e.g. if you are left-eye dominant, sit with your left side next to the person lying supine or prone; Fig. 2.86).
3. Avoid looking at the landmarks at an angle, if at all possible, as this may hide/distort any differences.
4. Orientate right and left markers the same way in order to make side-to-side comparisons easier and more accurate. For example, the thumbs should both be:
   a. flexed 90 degrees at the interphalangeal joint when resting against the malleoli, tips pointing straight downward (Figs 2.77B, 2.78B)
   b. pointing straight upward (craniad), parallel to midline, when resting against the inside of the ASIS or PSIS to detect 'outflare' or 'inflare' (Figs 2.13B,C, 2.66, 2.68, 2.71Ei)
   c. aligned horizontally when resting against the lower part of ASIS, PSIS or along the superior pubic rami in order to detect a relative upward displacement or rotation (Figs 2.71, 2.76)

Fig. 2.86 'Left eye dominant' examiner sitting/standing to left of subject to bring his left eye closer to her midline.

2. sit on the side of the plinth (rather than standing and having to lean/twist forward), to decrease the angle between your eyes and the table; this helps to cut down any error on comparison of landmarks (especially those in close proximity, such as the pubic bones), or side-to-side differences in height and rotation
3. bring the right eye as close to the person's midline as possible, in order to increase the accuracy of side-to-side comparisons of landmarks

The opposite applies if you are left eye dominant (Fig. 2.86).

It is useful to get into the habit of standing or sitting by the person on the correct side, both to facilitate the assessment and to make it more accurate. This approach also proves valuable at the time of carrying out alignment corrections using muscle energy and other treatment techniques as it allows for quick feedback on whether or not realignment has been achieved (Figs 7.9Cii, 7.11, 7.13, 7.14).

TORSION OF THE SACRUM

Torsion of the sacrum refers to rotation of the sacrum relative to the innominates, around the three major axes (Fig. 2.9), the right or left oblique axis, or all of these (Box 2.1; Figs 2.10, 2.14, 2.21, 2.42, 2.88, 2.89). Sacral torsion is a natural part of daily activities such as reaching, throwing, walking and running. Torsion involves motion around these various axes and is governed by the movement of the trunk, pelvic bones and lower extremities. Normal sacral movement into nutation on initial trunk flexion, and nutation on extension, has been described above (Figs 2.11, 2.17, 2.18), as has movement around the oblique axes during the gait cycle (Figs 2.21, 2.41) and on unilateral facet joint impaction (Fig. 2.52).

The sacrum may actually become pathologically fixed so that there results a loss of motion into certain directions. The following are three of the more common reasons for the occurrence of such a loss of motion or 'fixation' of the sacrococcygeal complex:

1. a movement that inadvertently exceeds the physiological limit available in that direction
2. contracture of ligaments, capsules, fascia or other connective tissue that can affect the position of the complex; e.g. sacrospinous, long dorsal sacroiliac, sacrotuberous ligaments (Figs 2.4A, 2.5A, 2.19, 2.21)
3. asymmetrical impaction, as in a fall onto the right or left side of the complex
4. contractural shortening or excessive tension or spasm in one of the muscles that attaches to the sacrum or coccyx (e.g. piriformis; Fig. 2.46A)

The muscles primarily involved are the piriformis and iliacus. Piriformis originates from the anterior aspect of the sacral base; the diagonal direction of its pull rotates the sacral base posteriorly and down relative to the ilium. Iliacus rotates the ilium anteriorly, inward and down relative to the sacrum (Fig. 2.46). Either movement causes a wedging of the ilium against the anteriorly widening sacrum and would normally help to stabilize the SI joint; if excessive, however, it can result in a loss of mobility or even a complete 'jamming' of the already incongruous iliac and sacral surfaces (Figs 2.2, 2.3, 2.7B).

Sacral landmarks

The diagnosis of torsion around the vertical or one of the oblique axes can usually be made simply by observing 'the lie of the sacrum': comparing the position of distinguishing landmarks when the person lies prone.

1. position of the sacral base as judged by the sacral sulci

   The sulci are formed by the junction of the ala ('wings') of the sacral base with the ilium on either side. Locate the depression on each side at the junction of L5 and S1 with the tip of an index finger and then run the fingers outward at this level until they abut the medial edge of the posterior iliac crest (approximately 1.5-2.5 cm lateral to the midline, often clearly demarcated by an overlying dimple; Figs 2.6, 2.71A). Now gently push the tip of each index finger into the depression, or 'sulcus', formed at this junction of the sacrum with the pelvis (Fig. 2.87B -indicated by right index). The true depth of the sulcus is approximately 1.0-1.5 cm, usually reduced to about 0.5-1.0 cm by the overlying skin and subcutaneous tissues. The depth of the right sulcus should equal that on the left and lie level in the coronal (frontal) plane.
2. the inferior lateral angle (ILA)

   This is the corner formed at the point where the inferior part of the sacrum rapidly starts to taper toward its junction with the coccyx (Fig. 2.3A, 2.71Gi). It is usually easily palpable through the overlying soft tissues, 1.0-1.5 cm up and out from the sacrococcygeal junction (Fig. 2.71Gii).

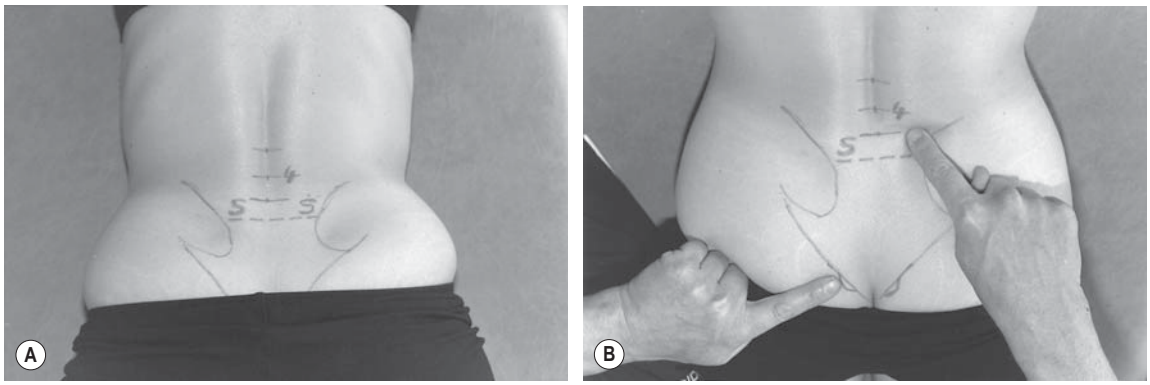

Fig. 2.87 Assessment of sacral landmarks in a prone-lying person. Note: the clinician with 'right eye dominance' should carry out the examination from the person's left in order to bring that eye closer to midline. (A) In alignment; the right and left sacral sulci (S) are of equal depth and level (as is the sacral base, demarcated by the dotted line); the solid line at '4' demarcates the L4 spinous process. (B) 'Left-on-left' rotation: the right index finger lies in the depressed right sacral sulcus, the left index finger on the ILA (the latter denoting the elevated left sacral margin; see also Figs 2.6, 2.71Gi)

3. the position of the sacral apex
   The sacral apex is the terminal part of the sacrum to which the coccyx attaches (Fig. 2.3A). Press the pulp of the index fingers or thumbs firmly down, through the soft tissues, onto the right and left lateral edges of this caudal part of the sacrum (just below the ILA). The fingers will normally lie at the same depth and equidistant from midline.

In the absence of rotation of the sacrum around the vertical axis or torsion around one of the oblique axes, comparison of right to left sacral base (sulci), sacral apex and ILA will show that these respective sites:

1. lie at an equal depth
2. are level in the coronal plane; that is, there is no relative displacement, upward (craniad) on one side and downward (caudad) on the other, except in the case of:
   a. a 'true' LLD, and then only when examined standing
   b. a functional LLD, as seen with an 'upslip' and 'rotational malalignment', where the pelvic unit as a whole tilts to right or left

However, it should be noted that whenever the sacral base is uneven on account of a 'true' LLD or malalignment, compensatory rotation around the sagittal axis can occur to the point that the person may present with the sacral base level in the coronal plane even though the LLD or malalignment persists (as discussed in Ch. 3; Fig. 3.90A,B).

Sacral torsion patterns

The following are some of the commonly occurring patterns of excessive or 'fixed' sacral torsion. The reader is referred to Richard (1986), Fowler (1986) and Greenman (1997) for further descriptions of these various forms and their effects on the lumbar spine.

'Left/left' or 'left-on-left' sacral torsion

The sacrum is fixed in forward rotation around the left oblique axis (Figs 2.21, 2.42, 2.50). Therefore, the right sacral sulcus (indicated by the right index finger in Fig. 2.87B) is depressed, the base having rotated anteriorly and downward (caudad); whereas the left sacral apex (left finger) and ILA is elevated, having rotated posteriorly and upward (craniad). The right ILA, like the right sulcus, also comes to lie anteriorly and caudad; the left ILA, posteriorly and craniad.

'Right/right' or 'right-on-right' sacral torsion

The sacrum is 'fixed' in forward rotation around the right oblique axis (Figs 2.14, 2.50, 2.52B). Findings are opposite to those seen with a 'left-on-left' torsion.

Rotation posteriorly around the left or right oblique axis

Rotation occurs in the direction opposite to that described for 'left-on-left' and 'right-on-right' forward rotations described above. The base rotates backward instead of forward around the left or right oblique axis, resulting in a 'left-on-right' and 'right-on-left' pattern, respectively (Fig. 2.88).

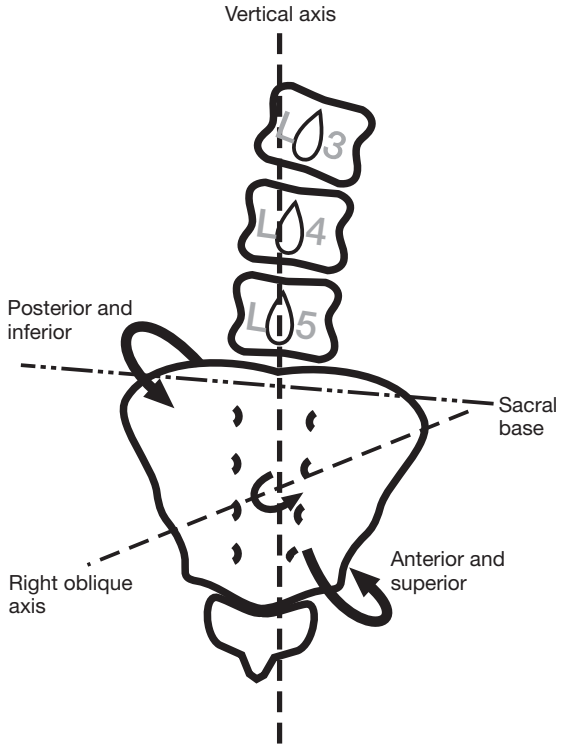

Fig. 2.88 Example of a 'backward' rotation: 'right-on-left' rotation around the right oblique axis.

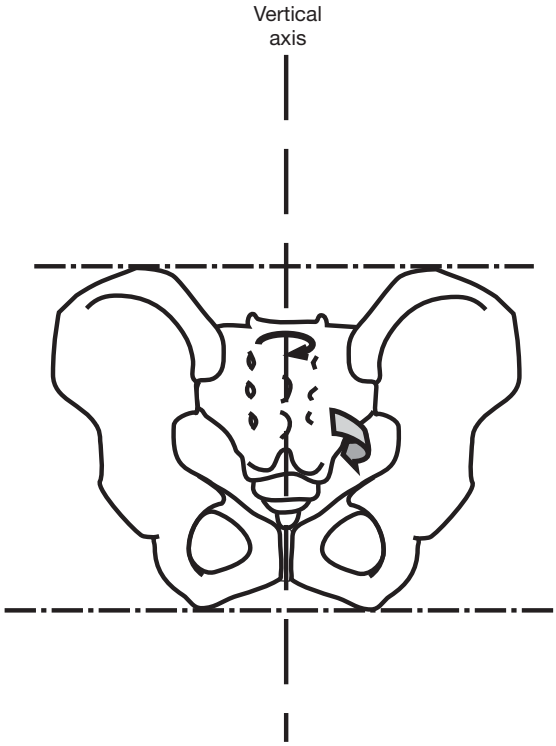

Fig. 2.89 Right unilateral anterior sacrum: rotation counterclockwise around the vertical axis.

Particularly significant is the fact that:

1. The forward rotations - 'left-on-left' and 'right-on-right' - accentuate the lumbosacral angle, increasing the lumbar lordosis and making the lumbar segment suppler.
2. The backward rotations - 'left-on-right' and 'right-on-left' - reduce the angle, and hence the lordosis, with a stiffening of the lumbar segment. Even worse, there may actually be formation of a lumbar kyphosis. These 'backward' presentations have been linked to distressing and seemingly unrelated problems (Richard 1986), including headaches and dysfunction of any or all of the following:
   a. gastrointestinal system (e.g. diarrhea alternating with constipation)
   b. genitourinary system (e.g. frequency, nocturia)
   c. menstrual cycle, and
   d. pelvic floor dysfunction

Right or left 'unilateral anterior sacrum'

The entire sacrum has rotated excessively to the right or left around the vertical axis in the transverse plane.

For example, a right unilateral anterior sacrum (i.e. sacral rotation counterclockwise; Fig. 2.89):

1. brings all the sacral landmarks anteriorly on the right and posteriorly on the left side
2. puts the following structures under increased tension:
   a. on the right side (sacrum in relative nutation)
      - anterior SI joint ligaments and capsule, also the sacrotuberous, sacrospinous, and interosseous ligament (Fig. 2.19A)
   b. on the left side (sacrum in relative counternutation)
      - posterior SI joint and long dorsal sacroiliac ligament (Fig. 2.19B)
3. jams the anteriorly-widening sacrum against the innominate on the left side.

Excessive rotation in the sagittal plane

As discussed further below ('Simultaneous bilateral SI joint malalignment'; see also Figs 2.11, 2.15-2.19), the sacrum presents in either:

1. excessive nutation, with the base fixed in an anterior position, and accentuation of the lumbar lordosis
2. excessive counternutation, with the base fixed in a posterior position, and flattening of the lumbar lordosis or even formation of a lumbar kyphosis.

Clinical correlation: sacral torsion

Unilateral anterior sacrum or sacral torsion around one of the oblique axes may occur in isolation or in addition to an anatomical (true) LLD or any of the three common presentations of malalignment. The sacral displacement may disappear completely on correction of the pelvic malalignment. However, as indicated above, if the sacral displacement persists it can continue to cause symptoms of its own and will require specific treatment measures (see Chs 7, 8).

CURVES OF THE SPINE AND VERTEBRAL ROTATIONAL DISPLACEMENT

It is rare to find a spine that is 'straight'. Most of us have some minor 'scoliotic' curves even when in alignment. 'Rotational malalignment' and an 'upslip' are usually associated with a more obvious scoliosis, which may simply be indicative of an attempt to compensate for the pelvic obliquity and to ensure the head ends up aligned as best as possible in all three planes so as not to compromise balance and vision. In addition, there may be one or more isolated vertebrae that are excessively rotated, or 'displaced', to the point they interrupt the particular segmental curve that they are a part of – cervical, thoracic or lumbar - and they stand out relative to the vertebra above and below. Such an apparent impingement of a vertebra between the adjacent vertebrae because of excessive rotation in a clockwise or counterclockwise direction (and the simultaneous side-flexion and extension or forward flexion) will henceforth be referred to as a '*vertebral rotational displacement*'.

To ascertain whether excessive curvature of the spine and/or rotational displacement of individual vertebra(e) is present, first examine the person from the back in standing, looking to see if the iliac crests, shoulders and inferior angles of the scapulae appear level or not (Figs 2.70, 2.90, 2.95A). Note any curvature(s) formed by the spinous processes. Is the spine straight, as it might be in someone who is in alignment? Does there appear to be one uniform curve or the more common double (or scoliotic) curve, with:

1. a lumbar component convex to one side, usually reversing around the thoracolumbar junction to give rise to a thoracic curve convex in the opposite direction (Figs 2.70, 2.72A, 2.73, 2.76B, 2.90)
2. the thoracic segment usually reversing proximally at about the cervicothoracic junction but sometimes as far down as the T4 or T5 level, to give rise to the cervical curve (Fig. 2.91).

Having the person bend forward brings the spinous processes into better relief and may make these curves more obvious. Alternately, asking the person to bring the scapulae together by contracting the rhomboid muscles may accentuate a curvature, particularly of the thoracic part of the spine, and help determine the proximal and distal points of reversal which form the cervicothoracic and thoracolumbar curves of the spine, respectively. Back extension tends to accentuate more the lumbar spine

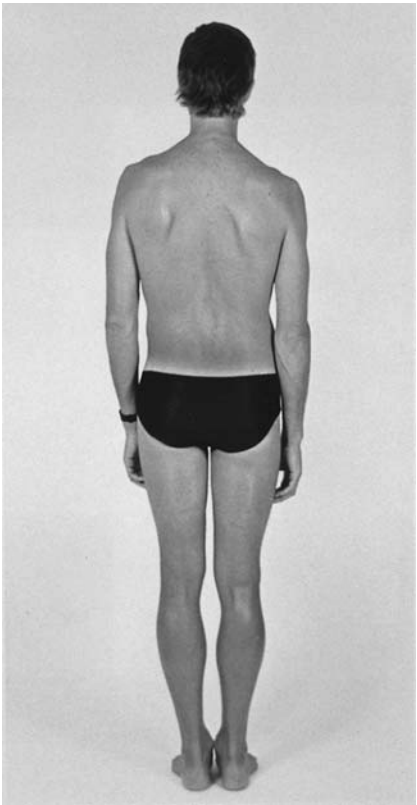

Fig. 2.90 Standing photo showing pelvic obliquity (iliac crest up on right), scoliotic curves (thoracic convex left, lumbar right) and depression of right scapula and shoulder. The right knee is partially flexed, as if the person were attempting to lower the pelvis on the high side.

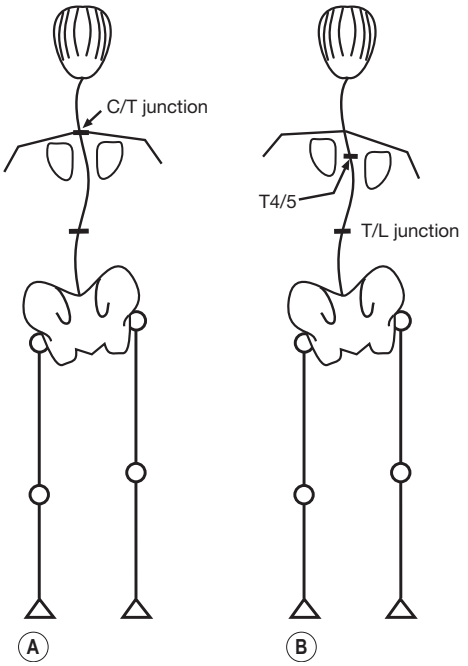

Fig. 2.91 Site of curve reversal at the proximal end of the thoracic spine. (A) More common: at the cervicothoracic (C/T) junction. (B) Less common: at the T4 or T5 vertebral level. T/L, thoracolumbar.

region (Fig. 2.120C). On side flexion, a completely flexible scoliotic curve will usually become one uniform curve; however, an interruption of this curve may still be evident on this manoeuvre, sometimes only on going to the right or left side, on account of:

1. the presence of pelvic malalignment and/or rotational displacement of one or more vertebrae
2. reactive muscle tightening or spasm to counter instability (e.g. joint laxity with ligament lengthening or osteoarthritis) and/or
3. pain from a structure being further strained or compressed by the manoeuvre (e.g. facet joints; Fig. 2.52B)

There may be failure of an area, or even an entire segment, to bend along with the rest of the spine. The lumbar segment, for example, may appear stiff as a rod on bending to one or both sides in someone whose thoracic segment still flexes easily to right and left (Fig. 2.92).

Next, examine the spine with the person sitting and do a side-to-side comparison of the level of the pelvic crests, shoulders and scapulae.

1. If the pelvis is now level, and any curves of the spine evident on standing have decreased or disappeared completely, these curves were

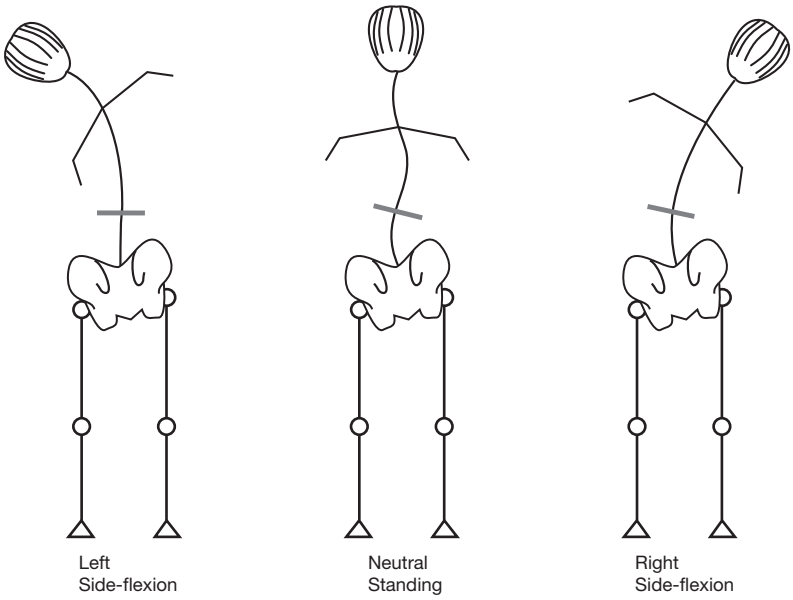

Fig. 2.92 Flexibility of the scoliotic curve noted when standing upright: flexibility of the lumbar segment is normal on right side-flexion but restricted on bending into the left.

probably 'functional', helping to compensate for the pelvic obliquity caused by an anatomical ('true') LLD (Fig. 2.72B).

2. At this initial stage of the examination, there may still be a residual, chronic increase in muscle tension that had been triggered by the LLD but may settle down with treatment, a heel raise (if indicated) and time to allow for further straightening of the spine.
3. Any residual curves may just represent the 'intrinsic' curves which most of us are blessed with, evident even when we are in alignment (Fig. 2.72A).

With the person lying supine, determine the slope of any persistent pelvic obliquity (Fig. 2.73A-D) and rule out the presence of an 'outflare/inflare' (Figs 2.13, 2.64-2.69). Then go on to a comparison of the right and left clavicle and ribs - these structures may provide some indication of the effect of a thoracic convexity or excessive rotational displacement of individual vertebrae on the anterior chest region. Tenderness and/or an actual anterior protrusion or recession of a clavicular joint may be indicative of a torsional effect on the clavicles caused by the malalignment that could, with time, result in further ligament laxity and, eventually, an actual subluxation or even dislocation of that joint (Figs 2.93A, 2.94B). Then apply light pressure to the 2nd to 11th right and left costochondral junctions individually - tenderness at one or more levels may be indicative of stress put on these joints by rotation of individual

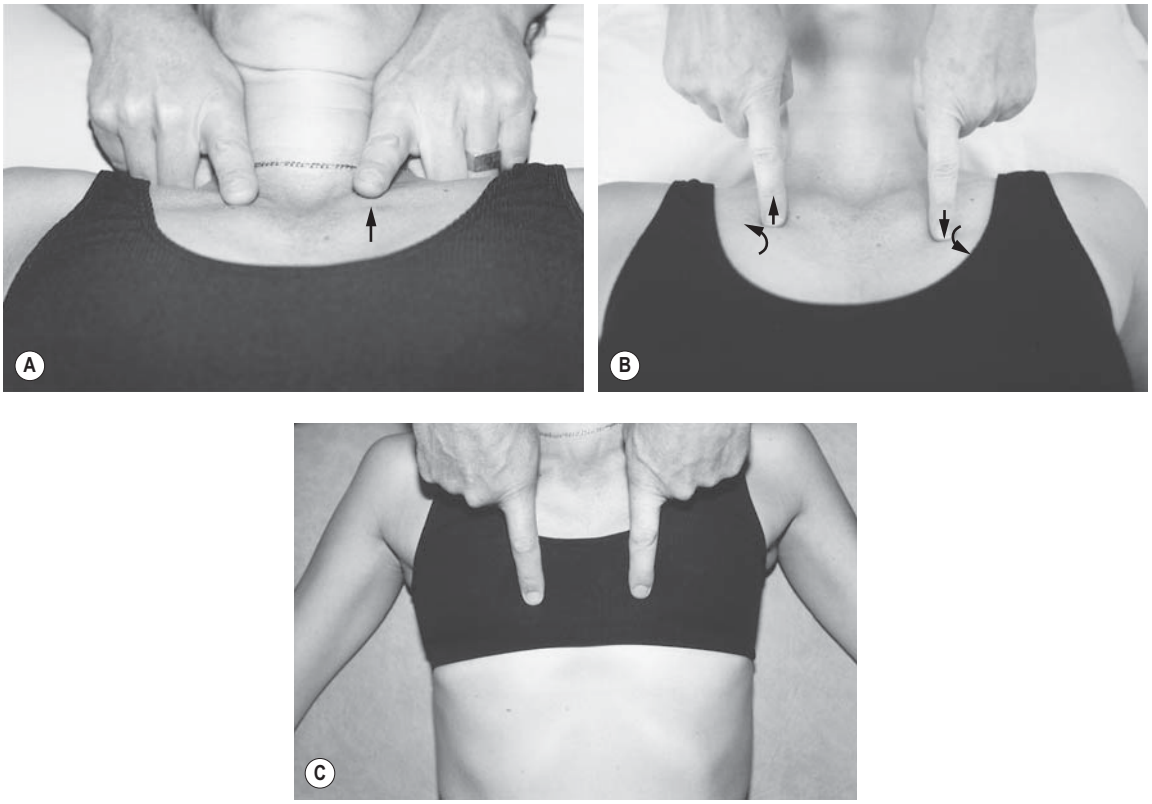

Fig. 2.93 Involvement of the ribs and clavicles with malalignment. (A) Posterior rotation of the left clavicle, resulting in anterior protrusion (and possibly eventual subluxation) at the left sternoclavicular junction, with the reverse findings on the right. (B) 1st to 4th, 5th or 6th rib level inclusive: showing the more commonly seen displacement of these upper left ribs downward and forward (anteriorly) relative to the right ones, which are displaced upward and backward (posteriorly) at these upper levels (thoracic convexity is to the left; see Figs 2.95, 3.15B). (C) 5th or 6th rib level (i.e. at or near the level of the apex of the thoracic convexity): the right and left ribs now match in both planes; the ribs below this level will show the right ones displaced downward and forward relative to the left ones, reflecting the change in direction of the thoracic curve below the apex.

thoracic vertebra(e) and the attaching ribs. The site of tenderness anteriorly can sometimes help localize a problem to a particular rib (e.g. subluxation) or vertebral level (which may turn out to be tender and/or displaced on examination of the spine itself). For example, tenderness of the 4th or 5th costochondral junction uni- or bilaterally is suggestive of a problem at around the T3-T6 vertebral levels of the spine (Figs 2.93C, 2.94A). However, there is not always a history of anterior chest discomfort or finding of costochondral tenderness in conjunction with an excessive vertebral rotational displacement.

The displacement of a clavicle or of one or more specific ribs on one side only (Fig. 2.93B), with or without tenderness over one or both sternoclavicular joints or any costochondral junction(s), can occur for a number of reasons. However, it may be seen simply as the result of these sites being put under increased biomechanical stresses by a functional thoracic convexity or a more localized problem, such as rotation of a clavicle or a specific vertebra (Fig. 2.94). In a person who has a left thoracic convexity, for example, when examined in supine-lying:

1. typically, the anterior chest cage shows the left 1st to 4th, 5th or 6th rib inclusive to lie 'anterior and down' a gradually decreasing amount on comparison to the right side; this is in keeping with the progressively decreasing 'right side-flexion, right rotation, and forward-flexion' of the upper thoracic vertebrae which, on the left side, pushes the ribs at these levels anteriorly and rotates them around the coronal axis while the opposite occurs on the right side - these changes account for the difference in their position at the costochondral junction on side-to-side comparison
2. either the 4th, 5th or 6th rib ends up level with their right counterpart
3. from this point down, the pattern reverses: the ribs on the right side now come to lie increasingly 'anterior and down' compared to the left ones; the point where this reversal occurs reflects the apex of the thoracic spine convexity.

Illustrated in Fig. 2.94 is the effect that an isolated excessive left rotational displacement of T5 has on the right and left ribs. The T5 vertebral body has rotated counterclockwise, left side-flexed as well as flexed forward. The 6th rib attaches to the inferior part of T5 vertebra at the costovertebral (C-V) joint and is actually affected more than the 5th rib. Overall effects of the T5 displacement include:

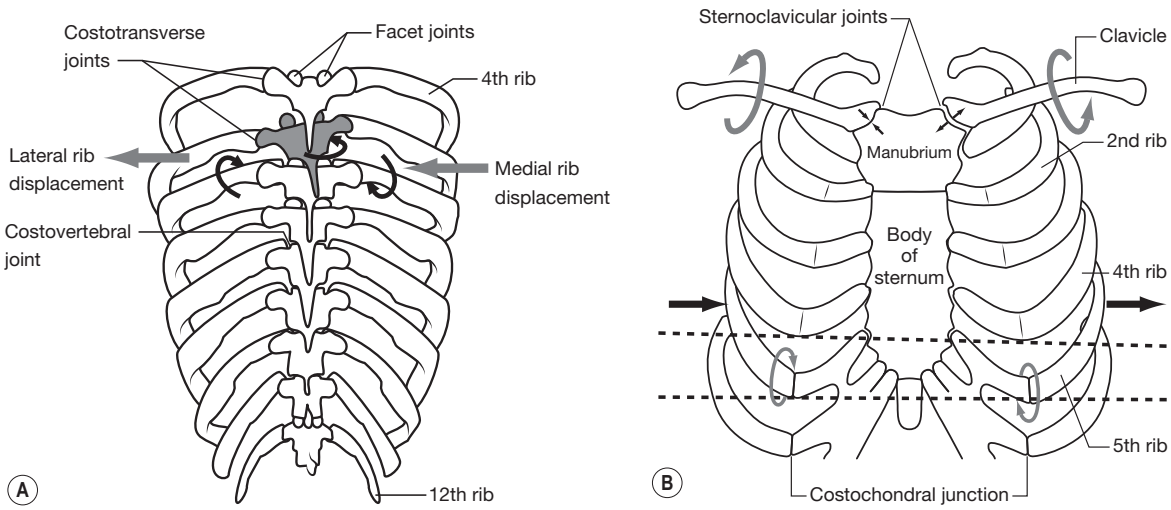

Fig. 2.94 T5 vertebral rotational displacement to the left, with simultaneous left side-flexion and either forward flexion or extension; i.e. a left 'FRS' or 'ERS' pattern, respectively (see also Figs 3.6, 3.13). (A) Posterior view: deviation of the T5 spinous process to the right, with contrary rib displacement and rotation; note the right facet joint compression, left 'distraction' or opening, and increase in stress on the costotransverse and costovertebral joints at this level. (B) Anterior view: stress on the bilateral 5th costochondral junctions through the ribs. Also illustrated are the typical opening and closing of the sternoclavicular joints caused by contrary rotation of the clavicles seen in conjunction with the compensatory scoliosis associated with pelvic malalignment.

1. on the right 6th rib
   a. pulling the rib upward (craniad) and medially at the C-V joint
   b. causing the rib to pivot around the transverse process (TP), at the costotransverse (C-T) joint
   c. posterior rotation of the rib around the coronal axis in the sagittal plane (as indicated by the arrow)
   d. pulling the right rib medially by its posterior attachments, with resultant distraction forces on the right C-V/C-T joints and, anteriorly, the C-C junction
2. on the left 6th rib
   a. displacement of the 6th rib downward and laterally at the C-V joint
   b. pivoting at the C-T joint, so that the rib rotates anteriorly around the coronal axis
   c. shifting of the rib backward and laterally, and
   d. compression forces on the left C-V/C-T joints and C-C junction.

Overall, stress is increased on the joints, capsules, and ligaments at all these anterior and posterior sites as well as the annulus, ligaments and disc itself because of T5 having rotated relative to the adjacent vertebrae.

Protrusion or recession of the anterior end of an isolated rib or ribs should raise suspicion of rib subluxation and/or possibly rotational displacement of a specific thoracic vertebra (Fig. 2.94), although these findings can also occur as a result of the ribs adjusting to an acute change in the thoracic convexity below the cervicothoracic level (Fig. 2.91).

Finally, look at the back with the person lying prone, his or her head resting in a face-hole or with the chin over the edge to prevent the upper spine from being twisted by a rotation of the head and neck (Fig. 2.95). Check the level of the pelvis and scapulae. If any curves are present, are they convex in the same direction as in standing and sitting? Again, does the upper thoracic curve start to reverse at the cervicothoracic junction, or at some point below (Fig. 2.91)?

To help to define these curves better, stand at the person's head and lay the pulp of your index fingers lightly against the right and left side of the protuberant spinous process of C7. Then run these fingers down alongside the thoracic and lumbar spinous processes and onto the sacrum. Note the direction in which the tips of your fingers point as they sweep downward and the sites at which their direction changes - usually at the apex of the thoracic and lumbar convexities (Fig. 2.95B-E).

Also note whether the smooth, contrasting curves formed by the spinous processes of the thoracic and lumbar segments are at any point acutely interrupted by a seemingly excessive rotational displacement of one or more of the vertebrae relative to the others. A rotation will henceforth be specified by the direction of rotation of the vertebral body. Examples of such a displacement include:

1. 'Left L4'

   Whereas Fig. 2.96A shows L4 aligned with L1-L5 to form a uniform lumbar convexity, this smooth curve is interrupted in Fig. 2.96B, with the body of L4 now 'left rotated'. Simultaneously running the index and middle finger along the right and left side of the spinous processes shows that of L4 deviating to the right; alternately, just one index or middle finger run alongside at about a 10-15 degree angle will
   a. bump into the bony protrusion of the L4 spinous process on the right and
   b. sink into a hollow created at this level by the L4 left rotation.
2. 'Left T5', 'Left T3'

   Findings for a 'left T5' rotation have been discussed above (Fig. 2.94A). In the case of a 'left T3', running a finger along the right and left side of the spinous processes from T6 upward shows a sudden right deviation of the T3 spinous process indicating that the T3 vertebral body has rotated to the left (counterclockwise) relative to the vertebrae above and below (Fig. 2.97A,B,C,E). A finger running alongside the spinous processes on the right side will abut the spinous process of T3 and be forced to move outward to get around it (Fig. 2.97D); whereas a finger on the left side would dip into the hollow created between T2 and T4 by rotation of that spinous process to the right.

The finger gliding past the level of the displaced vertebra may elicit a reflex contraction of the paravertebral muscles: the superficial and deep multifidi and adjacent erector spinae muscles. It may also cause outright pain and/or a spontaneous withdrawal reaction.

One can usually palpate, or even see, an increase in tension in the paravertebral muscles, and provoke pain from these muscles, also from the supraspinous, interspinous and facet joint ligaments, in particular.

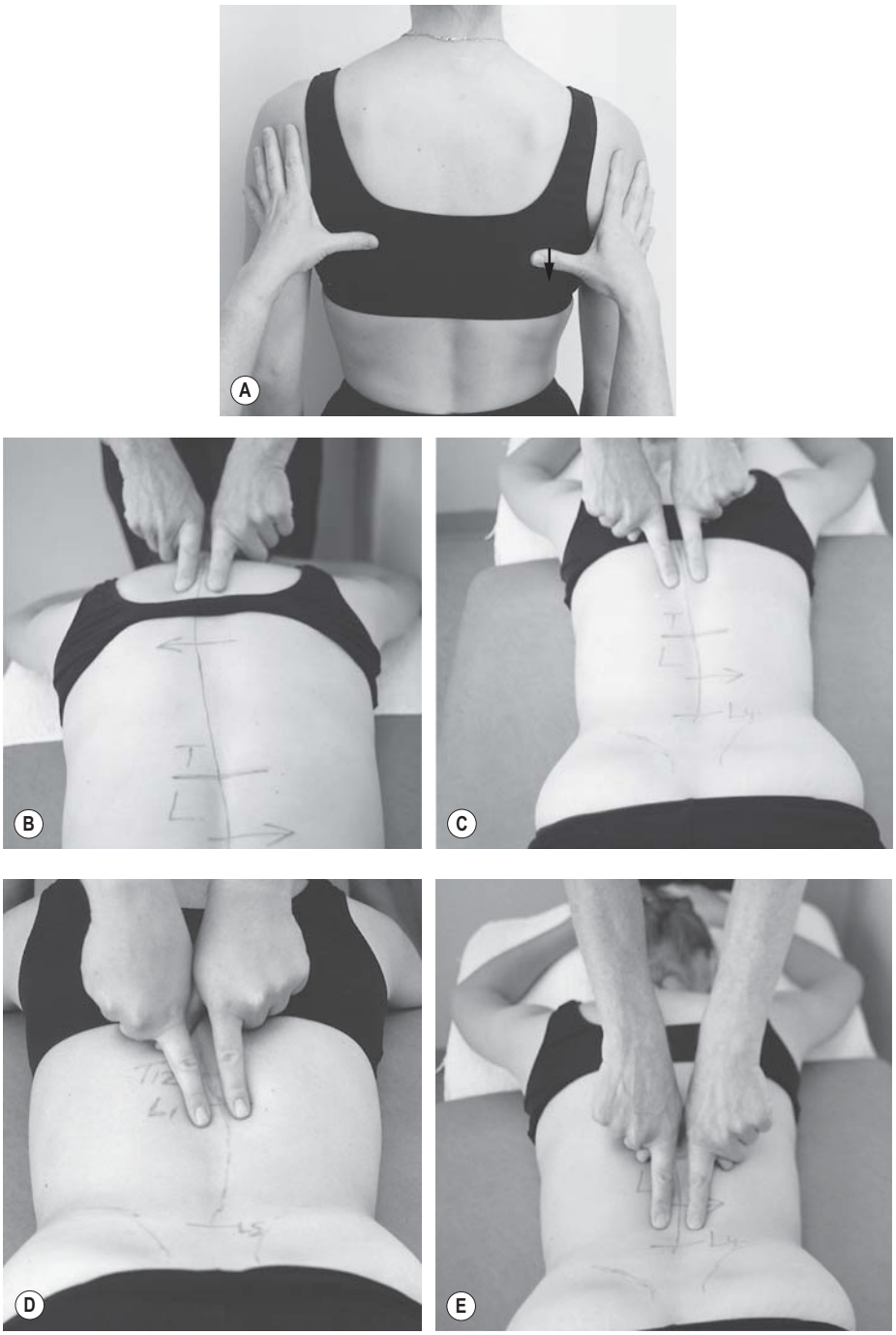

Fig. 2.95 Determining the direction of a thoracic and lumbar convexity. (A) In standing, downward displacement of the right scapular apex and the depressed right shoulder suggest (but do not confirm) a thoracic curve primarily convex to left (see also Fig. 2.91). (B) Left thoracic, right lumbar convexity (the apex of each curve is marked by a horizontal arrow); fingers alongside the spinous processes above thoracic apex - pointing to left. (C) Fingers below the thoracic apex - now pointing to right. (D) Fingers above lumbar apex - still pointing to right. (E) Fingers below lumbar apex - again pointing to left.

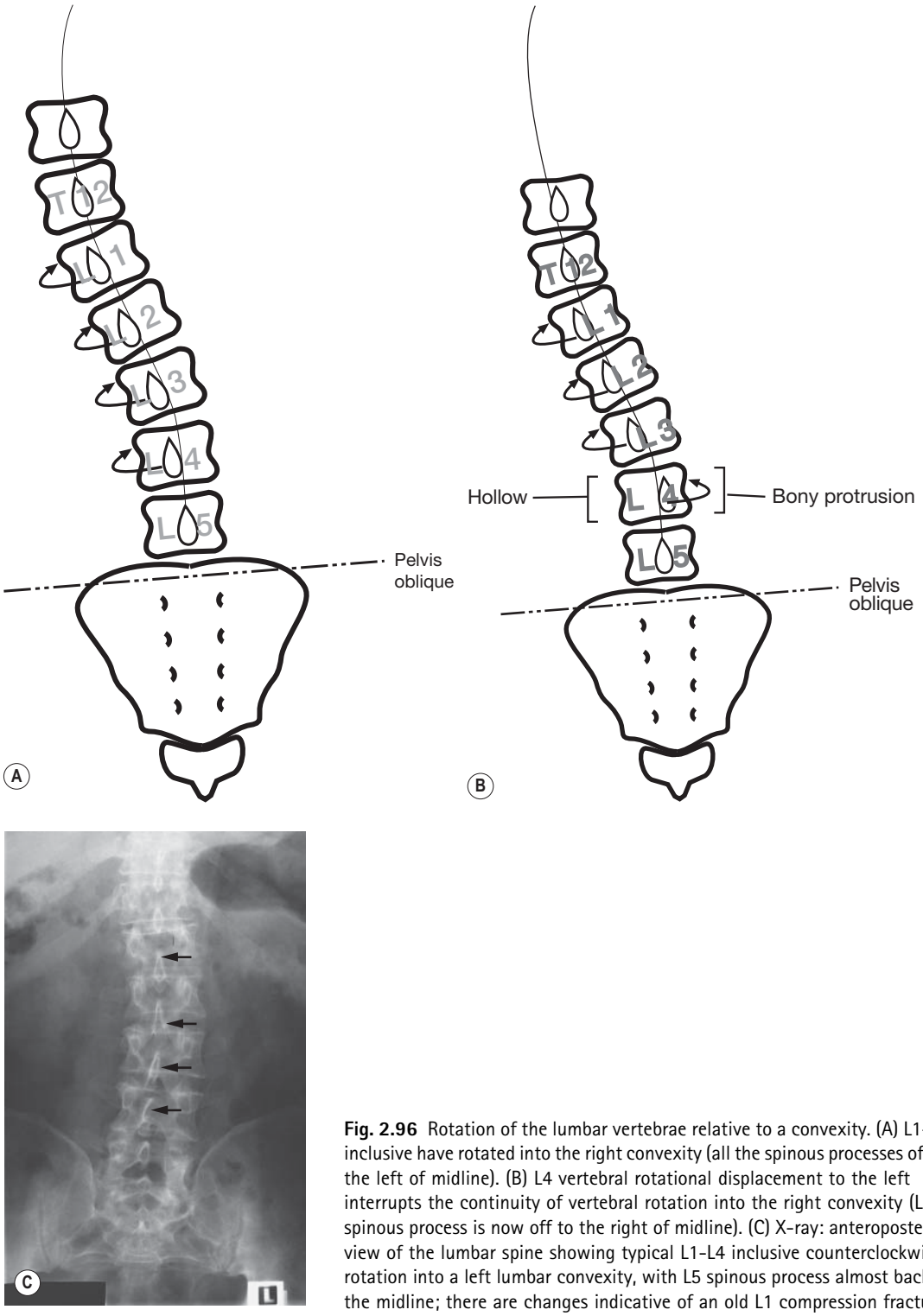

Fig. 2.96 Rotation of the lumbar vertebrae relative to a convexity. (A) L1–L4 inclusive have rotated into the right convexity (all the spinous processes off to the left of midline). (B) L4 vertebral rotational displacement to the left interrupts the continuity of vertebral rotation into the right convexity (L4 spinous process is now off to the right of midline). (C) X-ray: anteroposterior view of the lumbar spine showing typical L1-L4 inclusive counterclockwise rotation into a left lumbar convexity, with L5 spinous process almost back in the midline; there are changes indicative of an old L1 compression fracture.

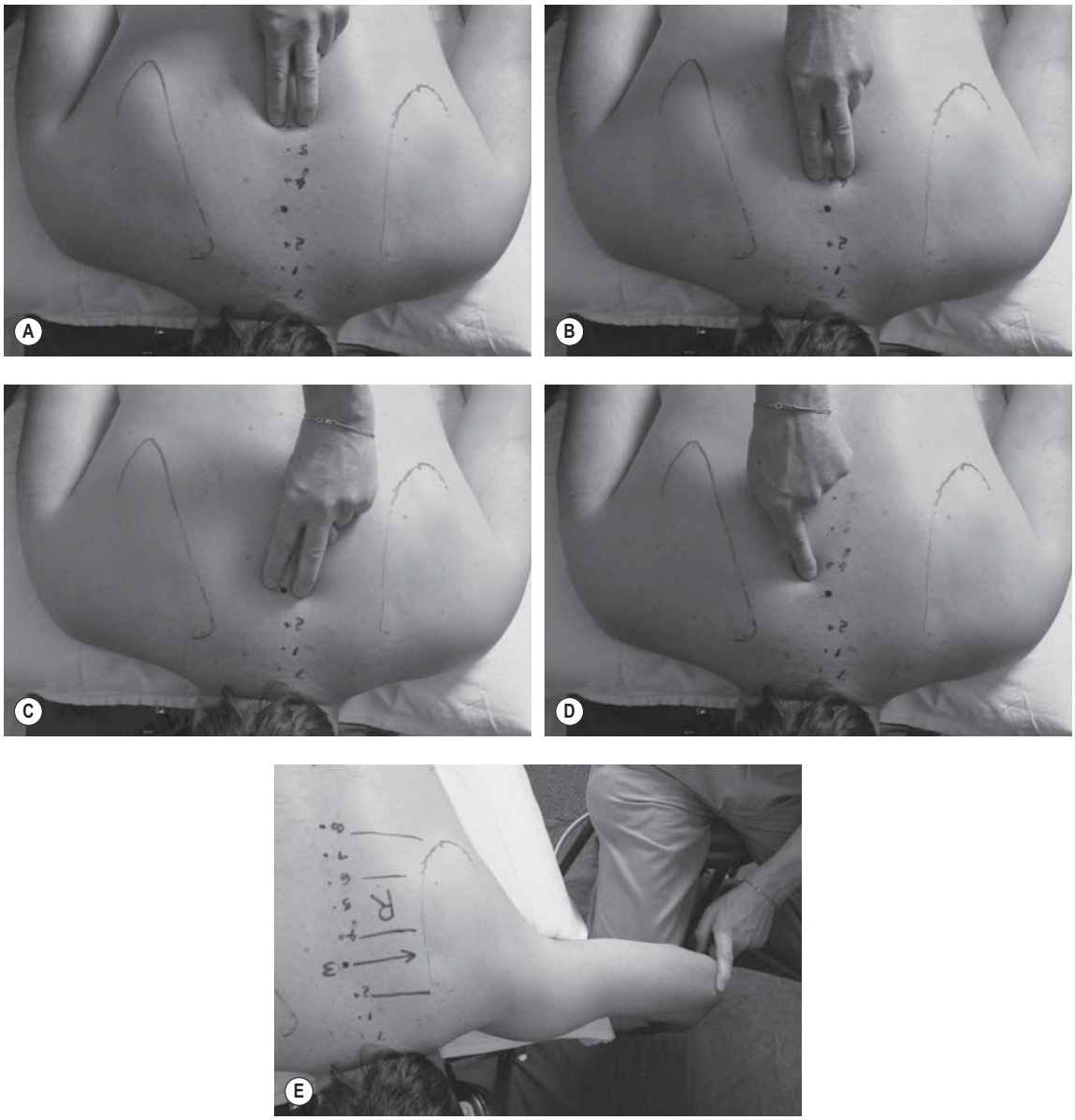

Fig. 2.97 Detecting a vertebral rotational displacement (see Figs 2.95, 2.96). There is a gentle curve of the upper thoracic spine segment, convex to left. (A,B) Index and middle fingers running upward (craniad) alongside thoracic spinous processes show T6,T5, T4 and T2,T1,C7 lying in line with this curve. (C) Fingers have to wind around T3 spinous process, which deviates to the right (= vertebral body rotated counterclockwise). (D) Index finger running along right side abuts on the deviating T3 spinous process; on the opposite side, there would be a 'hollow' detectable at this level. (E) Muscle Energy Technique (MET) to realign T3; arrow marks direction of pull generated on spinous process with left rhomboid contraction on resisted left elbow elevation.

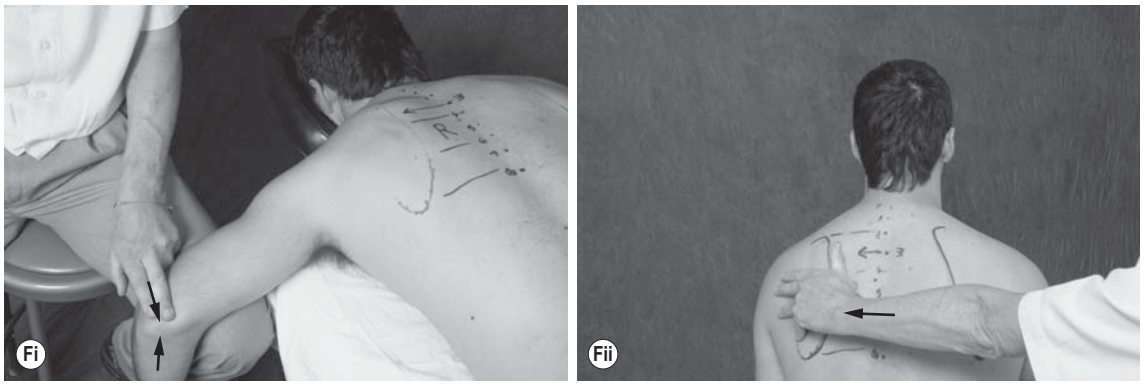

Fig. 2.97—contd (F) MET carried out by activating rhomboid (i) lying prone: blocking attempt to raise the elbow straight up toward the ceiling (ii) sitting: blocking attempt to move the scapula medially (see Chs 7, 8).

A force applied to the spinous processes in a posterior-to-anterior and right-left translatory direction may elicit pain from the displaced - and sometimes also immediately adjacent - vertebra(e) by stressing the soft tissues, intervertebral ligaments, capsules and facet joints in the vicinity (Fig. 4.20). It should, however, be noted that not all vertebrae that appear excessively rotated, or displaced, are symptomatic, prove painful on examination or even show an associated reactive increase in tension in the adjacent muscles.

Clinical correlation: curves of the spine

Anatomical (true) leg length difference

Compensatory scoliosis - usually a 'triple' curve, with a lumbar, thoracic and cervical component - is evident on standing. As the pelvis becomes level in sitting and lying (Fig. 2.72B), the curves are decreased, or sometimes even abolished, except at sites of any persistent rotational displacement of isolated vertebrae (Figs 2.94, 2.96, 2.97).

Sacroiliac joint 'upslip'

A right or left 'upslip' also results in obliquity of the pelvis, with formation of a compensatory scoliosis.

1. With a 'right upslip' (Fig. 2.73A), the pelvis is raised on the right side. The lumbar segment may be convex into either the high or the low side of the pelvis.
2. With a 'left upslip' (Fig. 2.73B), the obliquity may actually again be high on the right side in both standing and sitting but inclined up to the left in both prone and supine-lying, as expected. The direction of the curves remains constant in all positions, the lumbar curve usually convex to left and thoracic to right.

'Outflare/inflare'

Innominate rotation occurs around the vertical axis in the transverse plane so that, provided the leg length is equal, there is no pelvic obliquity. As in the case of someone with equal leg length, a scoliosis may still be present and is likely to be more obvious when standing.

'Rotational malalignment'

There is typically the triple curve with reversal at the thoracolumbar and cervicothoracic junctions. The curves usually persist in standing, sitting and lying prone but may change direction on moving from one position to another (Fig. 2.73C,D)

The pelvic obliquity is caused, in part, by:

1. contrary rotation of the innominate(s), with elevation of the iliac crest on the side of the 'anterior' rotation
2. an associated rotation ('tilting') of the pelvic unit around the sagittal axis in the coronal plane
3. the functional LLD

Which pelvic crest is higher or lower is, however, also influenced by other factors, including whether there is an underlying anatomical (true) LLD, a coexistent sacral torsion or an SI joint 'upslip'. It may, therefore, vary depending on the position of examination. Most prevalent is a consistent

elevation of the right superior iliac crest. Perhaps it is this variability in the factors responsible for the pelvic obliquity that might explain why one also sees such variability in the curvatures evident on examination but it does not help to predict:

1. the presentation of scoliotic curves one might expect on examining someone with malalignment
2. whether the curves defined when standing will persist in sitting and lying, or
3. whether the curves will persist in sitting and reverse on lying prone

More important than noting a change of the particular curves in the various positions of examination is to accept that:

1. scoliotic curves are likely to be more obvious in someone presenting with a pelvic obliquity for whatever reason than if the pelvis were level, but in both cases are not necessarily of significance or the cause of any symptoms
2. emphasis should be on recognition and treatment of an underlying malalignment problem and any secondary symptoms
3. the curves are usually less pronounced in sitting and lying, particularly once realignment has been achieved

EXAMINATION OF THE SYMPHYSIS PUBIS

The examiner should note whether any of the following occur.

Pain on palpating or stressing the joint

The symphysis may be painful on direct palpation. Pain caused by joint distraction may indicate primarily a ligamentous or capsular problem as these are put under increased tension (Figs 2.98, 3.66). Pain caused by joint compression is more likely to indicate joint pathology (Figs 2.99, 2.100). Degenerative changes on X-ray and a positive bone scan could be in keeping with such pathology; certainly findings suggestive of 'osteitis pubis' can result with increased stress on the joint caused by sacroiliac and/or hip joint dysfunction and malalignment. However, degenerative changes are by no means pathognomonic for symptoms arising from the joint itself. Superoinferior translation gives information on joint stability; pain provoked in this way probably is less specific because the manoeuvre stresses both the symphysis pubis and SI joint, also attaching soft tissue structures (Fig. 2.101). Similarly, anteroposterior translation stresses both joints. These tests are more likely to suggest isolated symphysis pubis involvement if pain is experienced just in the midline anteriorly (Fig. 2.112B).

Disturbance of joint symmetry

The joint may actually be asymmetric but asymptomatic. Pain felt in this area may also arise from other nearby structures (e.g. adductor origin, pelvic floor muscles, ligaments) or have been referred to a pubic symphysis that is actually in alignment (e.g. from an SI joint or iliolumbar ligament; Fig. 3.46).

'Anterior' or 'posterior' rotation of an innominate bone does not occur without simultaneous rotation of one pubic bone relative to the other. Similarly, an 'upslip' or 'downslip' causes a simultaneous upward or downward translation, respectively, both at the SI joint and the symphysis pubis. The vertical displacement at the symphysis is usually some 3–5 mm and readily discernible:

1. on comparison of the level of the mid- or index fingers or lateral edge of the thumbs placed on the upper edge of the superior pubic ramus, 1.5-2.0 cm to either side of the midline (Figs 2.71C, 3.86D)
2. by appreciating a sudden drop or rise in the contour as one sweeps a finger along the upper edge from one side to the other
3. on the anteroposterior X-ray view of the pelvis (Fig. 2.75).

As indicated previously, this displacement is associated with an obliquity of the pubic bones that remains evident on standing, sitting and lying, in keeping with the obliquity of the whole pelvic unit.

Instability of the joint

Instability may become apparent as:

1. excessive gapping (greater than 5 mm) noticeable on joint palpation
2. excessive movement of the joint on subjecting it to translatory forces: superoinferior (Fig. 2.101) and anteroposterior (Fig. 2.112B)
3. suspicion of separation of the pubic bones on routine X-rays (see Fig. 2.75).

It should, however, be pointed out that even marked instability may not become readily apparent on clinical examination, or even routine anteroposterior views of the pelvis, especially when these are taken with the person lying supine. If instability is

Fig. 2.98 Pain provocation test: transverse anterior distraction (symphysis pubis and anterior sacroiliac joint capsule and ligaments) with simultaneous posterior sacroiliac joint compression. *(Courtesy of Lee & Walsh 1996.)*

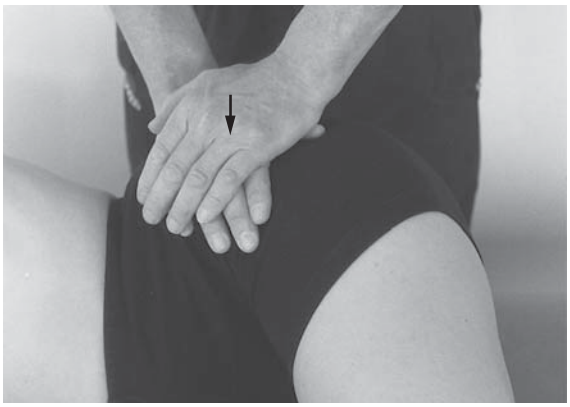

Fig. 2.100 Pain provocation test: anterior compression and posterior gapping achieved with a downward force on the upper innominate in side-lying. *(Courtesy of Lee & Walsh 1996.)*

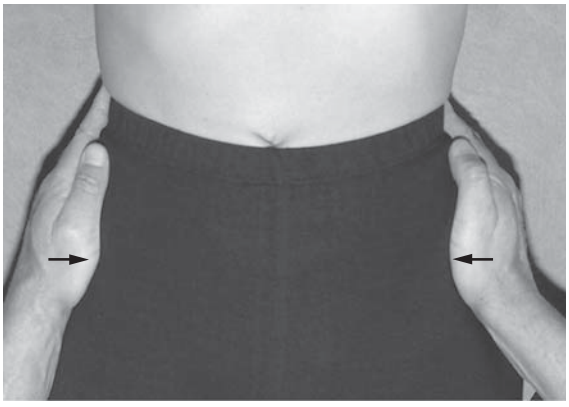

Fig. 2.99 Pain provocation test: medial compression of the innominates results in anterior compression and posterior distraction. *(Courtesy of Lee & Walsh 1996.)*

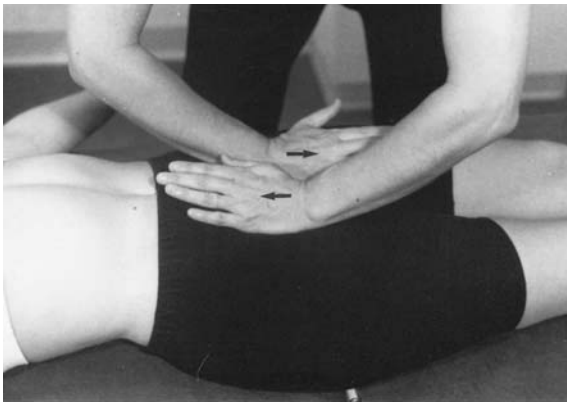

Fig. 2.101 Superoinferior translation test for the pubic symphysis. *(Courtesy Lee & Walsh 1996.)*

suspected, X-rays should be taken while stressing the joint, which can be achieved by:

1. carrying out an active straight leg raising test (see under 'Functional tests' below); this test has an advantage in that it can be carried out with the person lying supine (Figs 2.102A, 2.126A, 2.128)
2. maintaining a 'flamingo' or 'figure-4' position, standing alternately on the right and left legs, with the hip and knee of the opposite leg flexed and the foot resting against the weight-bearing leg at knee level (Fig. 2.102B)
3. standing on a stool and alternately letting one leg hang down while bearing full weight on the other one (Fig. 2.102C).

Clinical correlation: alignment at the symphysis pubis

Aligned, anatomical (true) leg length difference

With an anatomical long right leg, the right pubic bone lies higher than the left in standing (Fig. 2.72B). There is no actual displacement of the pubic bones relative to each other, just a uniform obliquity that inclines from left to right, which is evident on palpation and on a standing anteroposterior X-ray but abolished on sitting or on lying supine (Figs 2.74A, 2.81).

Sacroiliac joint 'upslip'

On the side of the 'upslip', there will usually be a 3–5 mm step-wise upward displacement of the

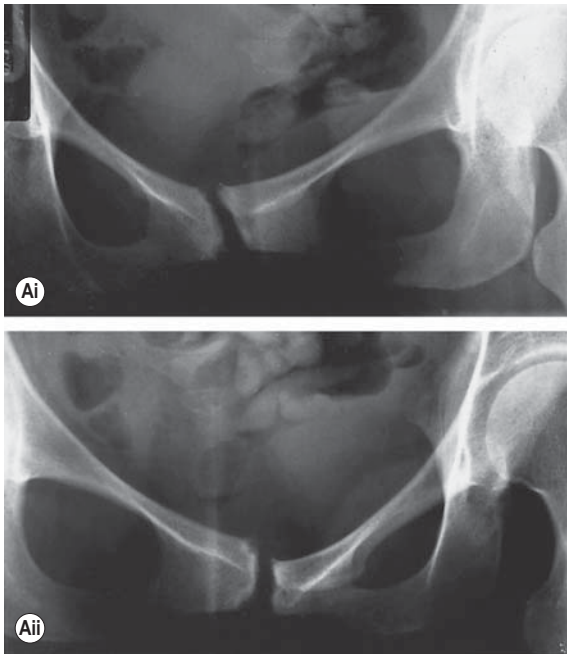

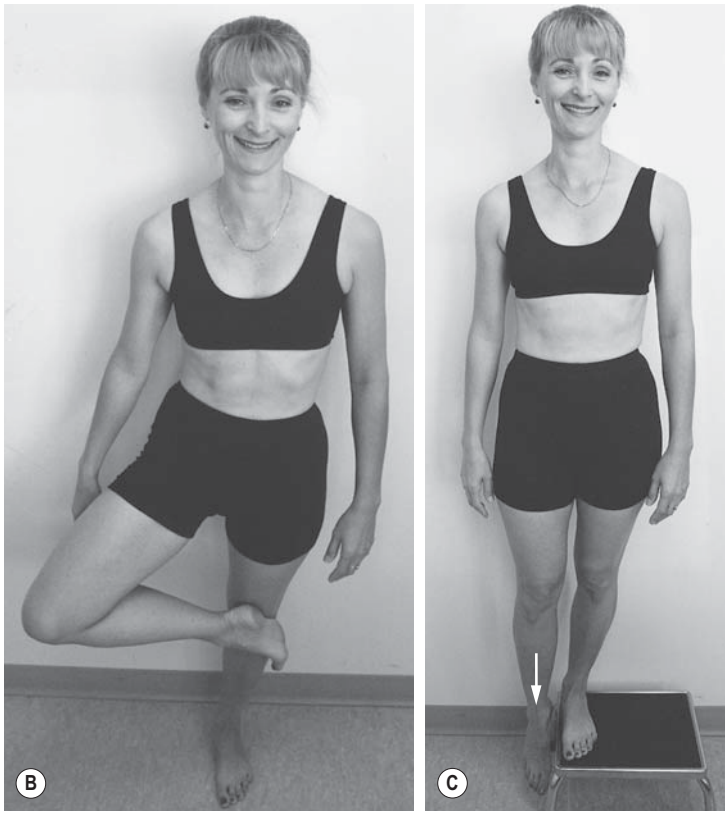

Fig. 2.102 X-ray diagnosis of symphysis pubis instability. (A) X-rays during 'active SLR' (ASLR) of a patient with a large displacement: (i) During ASLR of the right leg (reference side); (ii) During ASLR of the left (symptomatic) side. No malalignment of the pubic bones is seen during ASLR on the reference side. A step of about 5 mm is seen at the upper margins on the symptomatic side. The projection of the left pubic bone is smaller than that of the right, indicating an anterior rotation of the left pubic bone about an axis in the vicinity of the sacroiliac joint. *(Courtesy of Mens et al. 1997.)* (B) 'Flamingo' or 'figure-4' position likely to detect displacement of the left pubic bone relative to the right one when left SI joint is inadequately stabilized on left weight-bearing. (C) Left pubic bone is stressed by letting the right leg hang down freely suspended while bearing all weight on the left one.

pubic bone relative to that on the opposite side, with an obliquity inclined to the side of the 'upslip' in lying (Figs 2.73A,B, 2.82).

'Rotational malalignment'

With 'right anterior, left posterior' innominate rotation, the right pubic bone is shifted posteriorly and down, the left anteriorly and up. In addition to the contrary rotation of the pubic bones around the coronal axis, there is an actual downward displacement of the right pubic bone relative to the left evident at the symphysis (Figs 2.42, 2.73C,D, 2.75, 2.76C, 3.86D). 'Left anterior, right posterior' innominate rotation results in the opposite findings (Fig. 2.73D).

'Outflare/inflare'

The pubic bones are level but are subjected to compression/distraction stresses and may be tender/symptomatic.

HIP JOINT RANGES OF MOTION

As discussed in detail in Chapter 3, the hip ranges of motion are:

1. symmetrical in the person presenting in alignment or with an anatomical (true) LLD
2. asymmetrical in the presence of 'rotational malalignment', 'outflare/inflare' and an 'upslip' or 'downslip'.

Asymmetry of hip range of motion in the absence of pelvic malalignment, or in a pattern inconsistent with that typically associated with malalignment, should trigger a search for pathology involving the hip joint itself and/or specific soft tissues structures (see Appendix 3). Tightness of the acetabular anterior or Y ligaments, for example, will limit ipsilateral hip extension; a 'capsular pattern', with restriction of all joint ranges of motion, can result with generalized contracture of soft tissues and may be indicative of underlying hip joint osteoarthritis or of previous severe trauma with scarring.

ASSESSMENT OF LIGAMENTS AND MUSCLES

The examination for asymmetry and malalignment must include an assessment of tension and tenderness in the ligaments and muscles of the pelvic region and along the spine (Figs 2.4-2.6, 3.68). The sacrotuberous and sacrospinous ligaments, for example, are subjected to increased tension by sacral nutation and often prove tender to palpation (Figs 2.19A, 2.21). A spring test to briefly augment the nutation, and hence the tension, may provoke pain from these ligaments (Fig. 2.103A). Similarly, augmenting counternutation with anterior pressure on the apex of the sacrum may provoke pain from an already tense and often tender long dorsal sacroiliac ligament (Figs 2.5, 2.19B, 2.103B). There are patterns of muscles typically affected in terms of being tense

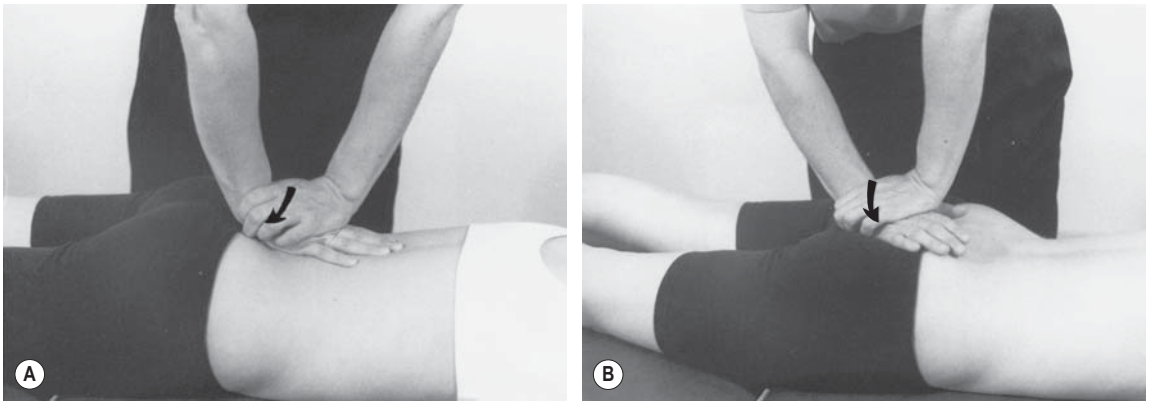

Fig. 2.103 Pain provocation tests for posterior pelvic ligaments, the hands applying an anterior force for 20 seconds. (A) Hands overlying the sacral base to enforce nutation and, thereby, increase tension in the sacrotuberous, sacrospinous and interosseous ligaments. (B) Hands overlying the sacral apex to enforce counternutation and, thereby, increase tension in the long dorsal sacroiliac ligament. *(Courtesy of Lee & Walsh 1996; see also Figs 2.5A, 2.19B.)*

and tender depending on the presentation at hand and, in the case of an 'upslip' or 'rotational malalignment', also a characteristic asymmetrical functional weakness distinct from a nerve root or peripheral nerve problem. The importance of these findings, both as a source of localized and referred pain and as a cause of recurrence of malalignment, is discussed in Chapter 3.

TESTS USED FOR THE EXAMINATION OF THE PELVIC GIRDLE

The assessment for malalignment requires an in-depth examination of the individual components – spine, pelvis and hip joints – and of the pelvic girdle as a unit. This section will concentrate on:

1. tests for mobility and stability
2. tests for ability of the unit to transfer load, remain stable and maintain balance when subjected to functional or dynamic stresses.

As Lee already pointed out so succinctly in 1992:

> *primary pathology of the lumbar spine can lead to secondary symptoms from the pelvic girdle. Alternately, primary pathology of the sacroiliac joint can lead to secondary symptoms from the lumbar spine*

The importance of the hip joints as part of this 'triage' has now been accepted. Because some of the tests for the pelvis also exert forces on the lumbosacral spine and hips, tests as selective as possible for these three individual segments must always be part of the examination. For example, activating external rotators of the thigh forces the femoral head forward, selectively increasing stress on the anterior hip capsule and compressing the structures lying immediately anterior: iliopsoas, pectineus, femoral nerve/artery/vein and others (Figs 2.104A,B, 4.14).

Over the past decade, the 'active straight leg raising' (ASLR) test has gained acceptance as being one of the more reliable ones for establishing whether there is indeed a problem with a pelvic joint, muscle or ligament and to help localize the site of pain origin. However, discussion will focus initially on other tests that have been used over the years and may:

1. increase a person's ability to assess a particular problem
2. be helpful in situations where factors limit what tests can be carried out safely and without aggravation; e.g. the site of injury, location and/or severity of the pain, or any limitation of mobility.

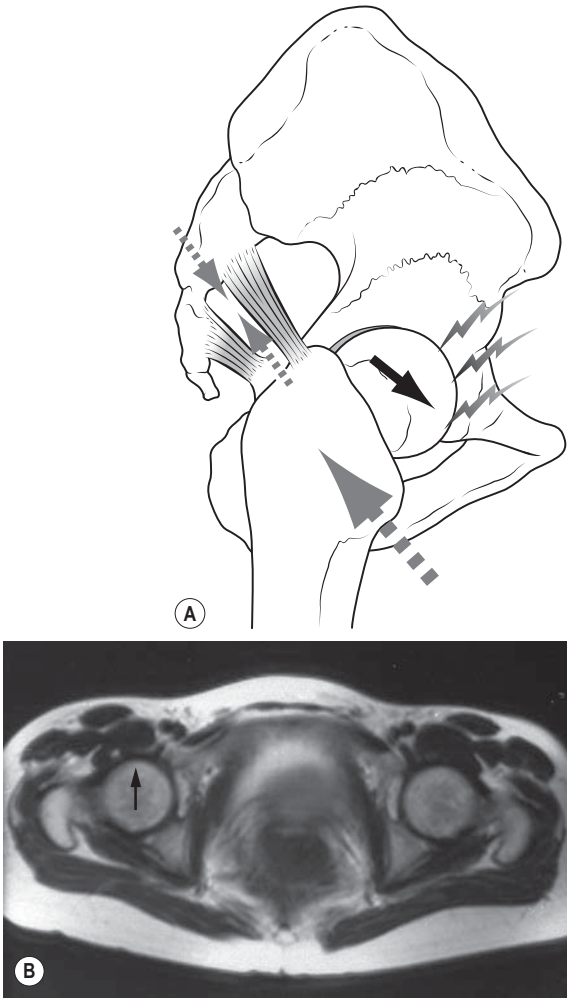

Fig. 2.104 Effects of femoral external rotation on hip joint and surrounding structures. (A) Overactivity of the deep external rotators of the hip pulls the greater trochanter posterior (large arrow) and forces the femoral head anterior. This position compresses the structures of the anterior hip and the subinguinal region. *(Courtesy of Lee 2007b; reproduced from Lee 2004a.)* (B) This is an MRI through both hips and the pelvic floor. Note the anterior position of the femoral head (arrow) and the resultant compression of the structures anterior to it. *(Courtesy of Lee 2007b.)*

The examination of gait, posture and the neurological, muscular and vascular systems is mentioned as appropriate throughout the text. For a more extensive coverage of these aspects, the reader is referred to Lee & Walsh (1996), Vleeming et al. 2007, Lee 2004a,b (e.g. 'Diagnosing the lumbosacral-hip dysfunction'),

Lee 2011 and authors concentrating specifically on neurovascular problems (e.g. Willard 2007).

TESTS FOR MOBILITY AND STABILITY

The following are tests commonly used to localize pain and to determine dysfunction of SI joint movement (e.g. hyper- or hypomobility, 'locking', or excessive rotation). Again, a caution is in order.

First, some of these tests are not specific for the SI joint itself because they also stress the hip joint, lumbosacral region or all three sites simultaneously. In order to better localize the pain, the examination should include tests that are more specific for stressing these sites individually.

Second, tests do not differentiate between pain arising from the joint itself, the supporting soft tissues or both. Compression tests are, generally, more likely to precipitate pain from the joint, distraction tests pain from the ligaments and capsule. The selective injection of local anaesthetic into the joint space or the ligaments may also be helpful in localizing the site of origin (see Ch. 7).

There may still be some value doing several stress tests in combination, especially if SI joint blocks under fluoroscopy are not available. Van der Wurff et al. (2006: 10) reported that, on comparison to fluoroscopically-controlled double SI joint blocks, a test regiment in which 3 or more of 5 non-invasive pain provocative tests proved positive was indicative that the pain was from the SI joint and could be 'used in early clinical decision making to reduce the number of unnecessary minimal invasive diagnostic SIJ procedures'.

Leverage tests

The following manoeuvres all depend on stressing the SI joint by using the femur like a lever to effect movement of the innominate bone. The femur can be used to rotate the innominate around the coronal axis, to move it in an anterior or posterior direction in the sagittal plane, or to adduct or abduct it relative to the sacrum. With the exception of Yeoman's test, all are carried out with the person lying supine. While leverage is here being discussed as a means of testing joints and soft tissue structures, it will be mentioned throughout the text from the viewpoint of how it can have detrimental or beneficial effects (see Ch. 7; Fig. 7.22)

First, with the hip flexed somewhere from 80 to 110-120 degrees to put the thigh at different angles relative to the innominate, push downward on the knee in order to move the femur, and hence the hip joint and innominate, in an anteroposterior direction (Fig. 2.105). There will be a simultaneous anterior rotational force of varying degree applied to the innominate, given that the acetabulum lies below the inferior transverse axis around which the wings of the ilia turn relative to the sacrum (Fig. 2.50)

Next, with the hip joint flexed to 90 degrees, the femur is passively adducted to stress the SI joint by forcing the anterior joint margins together and, at the same time, separating or 'gapping' the posterior joint margins to stress the posterior capsule and ligaments. The adduction force is applied with one hand on the outside of the knee while the other hand palpates the SI joint posteriorly to determine the amount of gapping (Fig. 2.106).

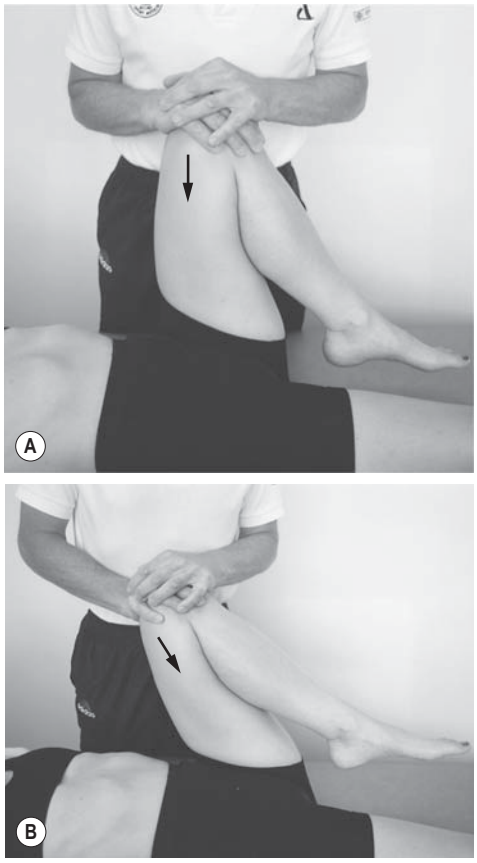

Fig. 2.105 Passive displacement of the innominate relative to the sacrum by a force applied through the femur. (A) Hip flexed to 90 degrees results in a more direct anteroposterior force. (B) Hip flexed to 110 degrees results in a relatively more anterior rotational force.

Fig. 2.106 Passive adduction of the right femur to 'gap' the posterior and compress the anterior aspect of the right sacroiliac joint.

Whereas gapping may be quite obviously increased or decreased from normal, always make a side-to-side comparison in order to determine any actual differences, in contrast to a generalized bilateral joint laxity or tightness that may be normal for that person. This test may not be tolerated when there is tenderness or spasm in muscles such as the iliopsoas and pectineus that are literally 'compressed' by the manoeuvre because it narrows the inguinal space. Alternately, posterior 'gapping' or distraction can be achieved by using a medial force applied to the ASIS of both innominates in supine lying (Fig. 2.99), or to the upper innominate in side-lying (Fig. 2.100).

Passive abduction of the flexed hip will gap the anterior part of the SI joint and stress the anterior capsule and ligaments; whereas the posterior aspect of the joint will be compressed.

Other stress tests, most of which also have a leverage component, can then be carried out.

Shear stress tests

1. ***anterior shear***

   This can be achieved with the FABER test (simultaneous hip Flexion, Abduction and External Rotation), also known as Patrick's or the 'figure-4' test. It has been commonly used to test for hip joint pathology and for restriction of range of motion, in particular external rotation (Figs 2.102B, 2.107A, 3.80). However, given that the hip joint lies caudad to the SI joint, this manoeuvre also turns the femur into a lever capable of:

   a. rotating the innominate posteriorly and externally (outward) relative to the sacrum,

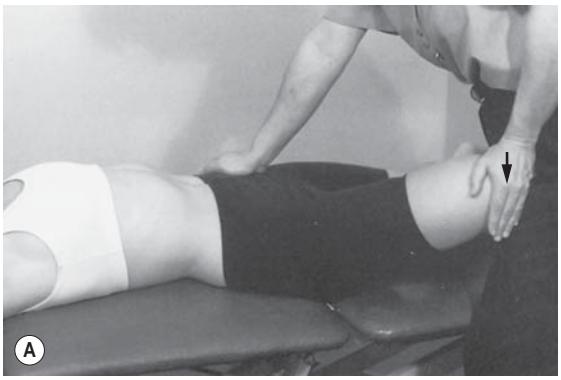

Fig. 2.107 Shear tests for the sacroiliac joint. (A) **FABER** manoeuvre (**F**lexion, **AB**duction and **E**xternal **R**otation). After finding the physiological limit of simultaneous movement in these directions, the femur is gently moved into further abduction and external rotation; at the same time, the contralateral innominate is fixed so that the flexed right femur becomes a lever capable of rotating the innominate externally and posteriorly through the hip joint. *(Courtesy of Lee & Walsh 1996; see also Fig. 3.80.)* (B) **FADE** (simultaneous **F**lexion, **AD**duction and **E**xternal force) or **POSH** (**PO**sterior **SH**ear) test: the hip is flexed, the femur adducted and an axial force then exerted through the femur to push the ilium posteriorly relative to the sacrum.

and stretching the TFL/ITB complex and muscles in the anterior groin region (e.g. iliopsoas, pectineus, adductor origins)

b. effecting nutation and thereby stressing the sacrotuberous, sacrospinous and interosseous ligaments

c. compressing the SI joint posteriorly and opening it anteriorly, with stretching of the anterior SI joint capsule and ligaments

d. moving the ilium so it translates anteriorly relative to the sacrum while the pelvis is stabilized, with resultant shear stress on the anterior part of the SI joint.

2. ***posterior shear***

This can be effected with the FADE (simultaneous Flexion, Adduction, External force) or POSH (POsterior SHear) tests (Fig. 2.107B).

Hip extension tests

These are commonly used to stress the hip joint but progressive movement of the femur will eventually also stress the SI joint by rotating the innominate anteriorly in the sagittal plane.

1. *Yeoman's test*: passive unilateral hip extension, with the person prone (Figs 2.47B, 2.108A, 7.16)
2. *Gaenslen's test*: passive unilateral hip extension, with the person supine and the leg hanging over the side of the plinth (Fig. 2.108B).

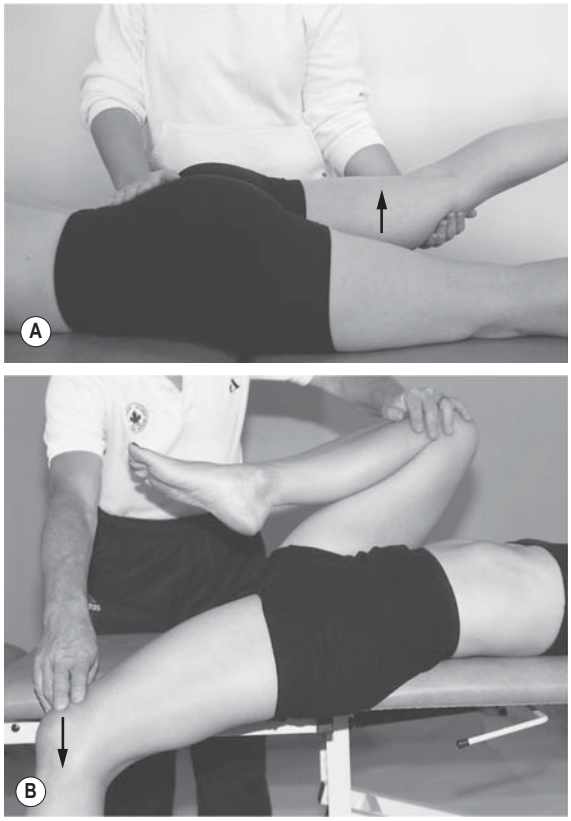

Fig. 2.108 Hip extension to effect anterior innominate rotation and stress the sacroiliac joint. (A) Right Yeoman's test (passive hip extension, prone-lying). (B) Left Gaenslen's test (passive hip extension, supine-lying).

Hip flexion tests

Passive straight leg raising, also hip flexion with the knee bent (Fig. 2.109), can both turn the femur into a lever arm. For example, on passive hip flexion of greater than 110-120 degrees, the femoral head engages the anterior acetabular rim and causes the innominate to rotate posteriorly in the sagittal plane (see Ch. 7). Any pain thus provoked, by stressing the SI joint itself and/or putting tender posterior pelvic ligaments under increased tension, may be confused with pain elicited by putting the sciatic nerve and nerve roots under stretch or by mechanically stressing the lumbar spine as it is forced into increasing flexion.

Wells back in 1986 suggested that some differentiation between a lumbar as opposed to an SI joint dysfunction should be possible. He felt that the SI joint is more likely to be the problem if the pain produced by a unilateral hip flexion test does not occur on carrying out the test on both sides simultaneously because the latter does

Fig. 2.109 Passive hip flexion, using the right femur to effect posterior rotation of the right innominate relative to the sacrum. *(Courtesy of Lee & Walsh 1996.)*

not produce the torsional stress on the SI joint that results with the unilateral test. Pain that persists on the bilateral test argues for a lumbar cause because the stresses on the nerves and lumbar spine are the same in both tests.

Spring tests

Pain originating from the hip joint proper may interfere with the interpretation of leverage-type tests and may even make it impossible to use them. One may be able to bypass this problem using passive mobility tests that attempt to shift either the innominate or the sacrum relative to the other, the aim being to assess the degree and quality of motion and to see whether the test provokes any symptoms.

Once the end of the passive range has been reached (= degree or quantity), the application of a gentle springing force provides further information regarding end-feel and symptom provocation (=quality). As Hesch et al. stressed (1992: 445), 'the spring test is . . . applied as a gentle force within the physiological range'. Findings run from excessive movement to varying degrees of impaired movement or absolutely no joint play or spring detectable. On all these tests, side-to-side comparison is imperative in order to detect a relative increase or decrease in mobility. The current teaching is that:

1. symmetry of findings is the norm
2. asymmetry is indicative of dysfunction

In other words, asymmetry - be it of joint stiffness, laxity or other 'abnormality' of motion - is more likely to present a clinical problem than if this stiffness, laxity or other change were found to be of the same degree (symmetrical) on side-to-side comparison (Buyruk et al. 1995b, 1999; Damen et al. 2002b; Buyruk 1997). The reader is referred to Lee & Walsh (1996) and Lee (1999; 2004a,b; 2011) for a more extensive description of the following spring tests.

Spring tests carried out with the person prone

Springing of the innominate in a posteroanterior direction creates a shear stress on the SI joint and allows for the localization of pain and the assessment of the amount of movement possible in the anterior direction.

The heel of one hand is placed on the innominate, directly on or alongside the PSIS; the heel of the other hand rests along the opposite border of the sacrum in order to stabilize the sacrum relative to the innominate (Fig. 2.110). After locking the elbow, bend forward with the trunk and apply a gradually increasing downward pressure on the innominate until all the slack in the soft tissues surrounding the SI joint has been taken up and the initial movement of the innominate stops. At this point, apply a quick, low-amplitude force directly through the outstretched arm to the hand and the underlying innominate.

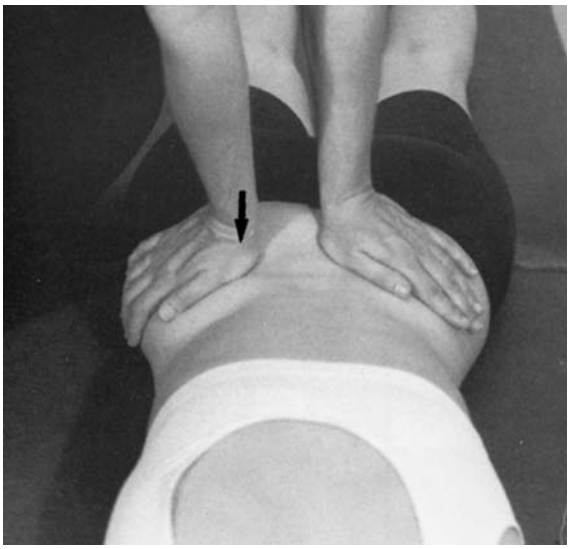

Fig. 2.110 Posterior-anterior shear stress on innominate relative to the sacrum: with the left hand on the far side of the sacrum for counterbalance, the right hand applies a quick downward force on the right innominate. *(Courtesy of Lee & Walsh 1996.)*

The above manoeuvre can be modified by placing the heel of the hand that rests on the innominate either just above or below the PSIS in order to produce an anterior or posterior rotational stress, respectively, on the innominate relative to the sacrum. The sacrum is stabilized by placing the heel of the other hand on the apex.

The SI joint and specific ligaments can be stressed selectively using a quick springing action to force the sacrum into increased nutation or counternutation, similar to the pain provocative tests using a prolonged force (see above and Fig. 2.103).

Pain may be provoked by stressing the SI joint in a longitudinal direction. The heel of one hand pushes on the apex of the sacrum in a cephalad (upward) direction as the heel of the other hand pushes caudad (downward) on the posterior iliac crest (Fig. 2.111A). Conversely, the heel of one hand exerts pressure in a caudad direction on the base of the sacrum as the heel of the other hand applies pressure against the ischial tuberosity to force the

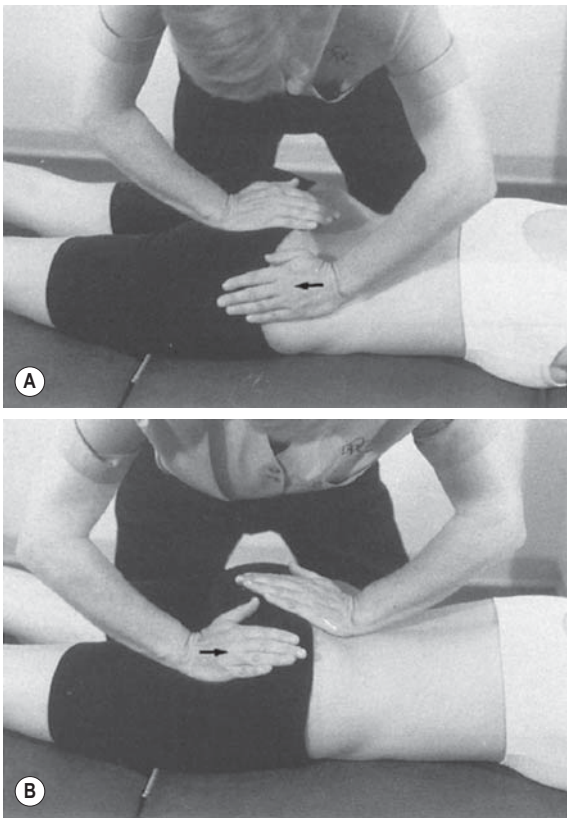

Fig. 2.111 Translation of the right innominate relative to the sacrum. (A) Inferosuperior: sacrum cephalad, innominate caudad. (B) Superoinferior: sacrum caudad, innominate cephalad. *(Courtesy of Lee & Walsh 1996.)*

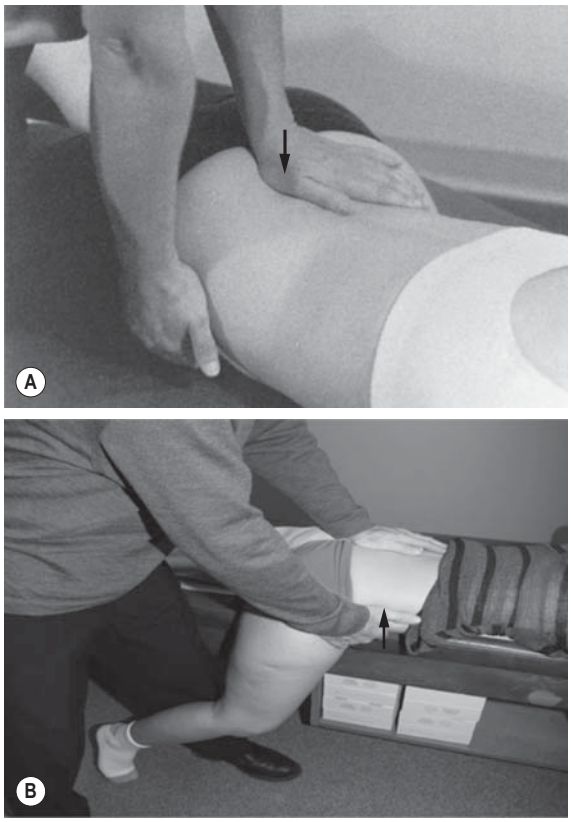

Fig. 2.112 (A) Posterior translation (innominate on the sacrum) - prone. Comparison of right to left side for detection of asymmetries is indicated. Here the right hand applied to the right anterior superior iliac spine and iliac crest fixes the innominate while a posteroanterior force is applied with the heel of the left hand to the ipsilateral side of the sacrum. Quantity and end feel of motion and the reproduction of symptoms are observed. *(Courtesy of Lee & Walsh 1996.)* (B) Lying prone with right leg hanging over the edge of plinth: anterior force [exerted by the left hand placed] on sacrum helps to stabilize the pelvis while sensing for movement at the SI joint when a posterior translatory force is applied [by the right hand] to the right innominate. *(Courtesy of Sweeting 2009.)*

innominate cephalad (Fig. 2.111B). If the sacrococcygeal joint or the coccyx itself is tender, it may be not be possible to perform these tests.

In another test, the fingers of one hand fix the ASIS and iliac crest while the heel of the other hand forces down on the ipsilateral side of the sacrum until end-feel is perceived (Fig. 2.112). A small amount of pain-free anteroposterior joint play in the sagittal plane can normally be detected. Alternatively, with the left hand steadying the sacrum, the right hand can apply a quick upward (posteroanterior) force on the innominate, with the person positioned either as in Fig. 2.112A or with the right hip in some flexion and the leg draped over the side (Fig. 2.112B).

Spring tests carried out with the person supine

Compression and distraction forces

These are modifications of the pain provocative tests discussed above, again with addition of a quick, low-amplitude stress on some of these tests once end-feel has been perceived on stretching the surrounding soft tissues (Figs. 2.98, 2.99, 2.101).

Glide of the innominate relative to the sacrum

For the next three tests, the long and ring fingers are hooked around the medial edge of the posterior pelvic ring and come to lie in the sacral sulcus, where they can sense movement between the innominate and the sacrum. The index finger lies on the spinous process of L5 in order to sense the end of motion between the sacrum and the innominate.

Fig. 2.113 Placement of the long and ring fingers in the sacral sulcus, and the index finger on L5 for sensing innominate movement relative to the sacrum. *(Courtesy of Lee & Walsh 1996.)*

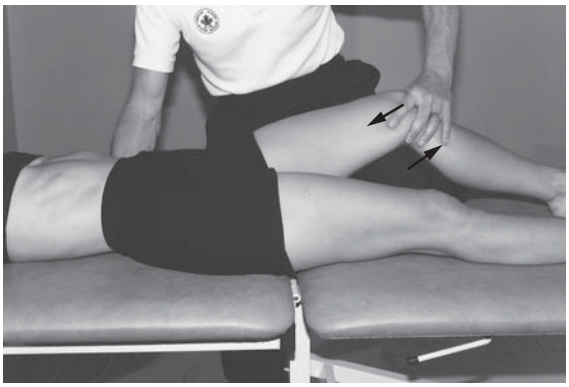

Fig. 2.114 Testing for left innominate movement relative to the sacrum in the craniocaudal or superoinferior plane, using pushing/pulling forces on the femur.

1. Anteroposterior plane

Increasing anteroposterior pressure is then applied to the anterior pelvic rim until end-feel is achieved, at which point the pelvic girdle as a unit starts to move laterally relative to L5 (Fig. 2.113). A note is made of:

a. the actual end-feel itself (well-defined, sloppy, etc.)
b. the amount of movement between the sacrum and innominate
c. whether there is any further displacement - and how much - of the innominate relative to the sacrum when a quick thrust is applied to the anterior iliac crest
d. whether these manoeuvres elicit any symptoms, and
e. how all the findings compare with doing the test on the opposite side.

2. Craniocaudal or superoinferior plane

For a test of the left SI joint (Fig. 2.114), the knee is about 20-30 degrees flexed, resting across a pillow or, if possible, across the examiner's knee (proped up on the plinth). With the right hand positioned to sense glide between the innominate and the sacrum, the examiner's left hand holds onto the distal end of the femur or patellofemoral region in order to apply a force, alternately:

a. pushing upward (cephalad)
b. pulling downward (caudad), an action that can be augmented by pressing his or her left knee against the posterior aspect of the proximal tibia.

3. Anterioposterior and rotational planes combined

The heel of the free hand applies pressure on the ipsilateral ASIS to create a translatory force in an anteroposterior direction until an end-feel is perceived, followed by a quick thrust to detect and evaluate any further displacement (Fig. 2.115A). The manoeuvre is then altered to assess the glide between the SI joint surfaces with rotation of the innominate in the sagittal plane:

a. by applying the force just above the ASIS (Fig. 2.115B) to effect anterior innominate rotation and relative sacral counternutation, which would decrease SI joint stability (Fig. 2.15)
b. by applying a force just below the ASIS (Fig. 2.115C) to effect posterior innominate rotation and relative sacral nutation, which should increase SI joint stability (Fig. 2.16)

If a leverage or spring test fails to provoke pain, that does not mean that the joint is functioning normally. The joint may, for example, be hypomobile or even immobile and yet be asymptomatic. It is now well recognized that it is often the joint that is still mobile that proves to be painful and may also be hypermobile, all this possibly because of the increased stress it is now subjected to as a result of the loss of mobility in the opposite joint. Always keep in mind that:

> *Mobility restrictions of the lumbar spine, pelvic girdle and/or hip joint will influence the function and motion of the adjacent regions. Often, all three areas require treatment and it is not rare for the most hypomobile area to be the least symptomatic.*
>
> (Lee 1992b; 475)

FUNCTIONAL OR DYNAMIC TESTS

The leverage and spring tests are passive tests for SI joint mobility and stability. The following tests try to assess, in particular, the ability to transfer load

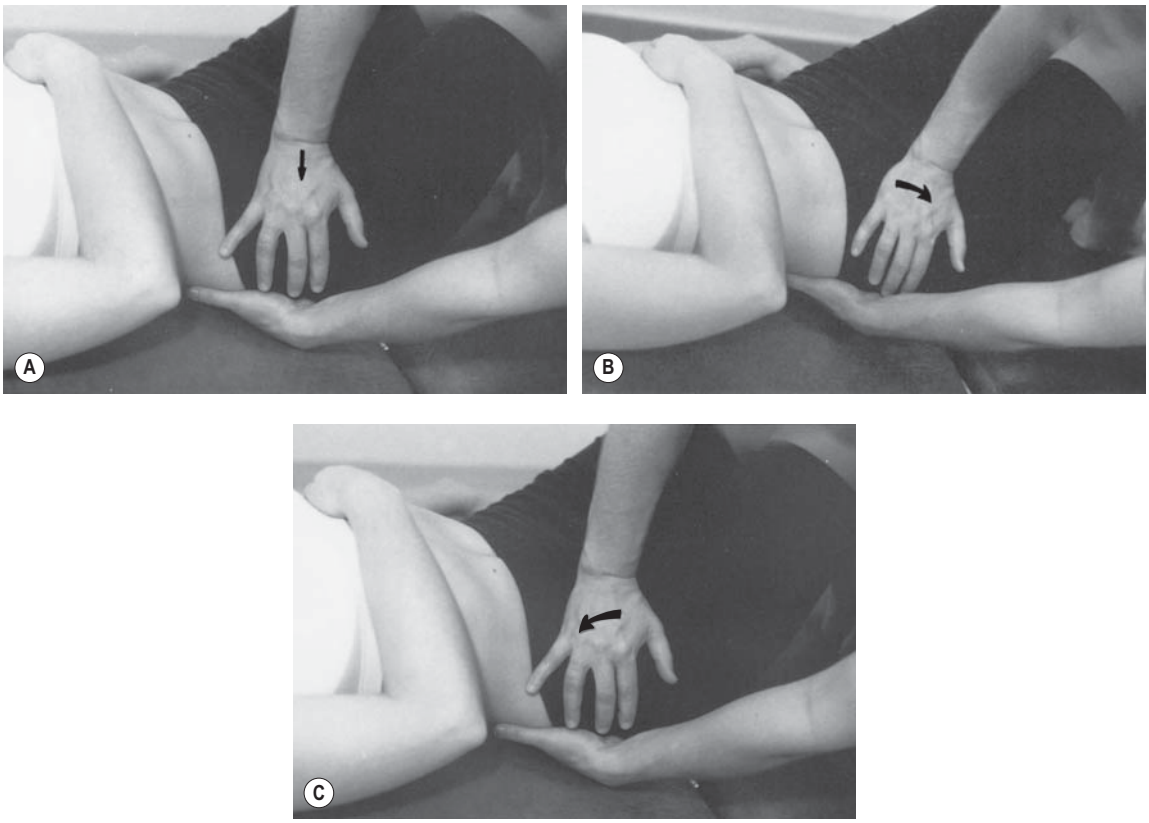

Fig. 2.115 Innominate movement relative to the sacrum. (A) Anteroposterior translation or glide: a posterior translation force is applied to the innominate and the motion is noted posteriorly. (B) Anterior rotation of the innominate requires an inferoposterior glide of the sacroiliac (SI) joint (a caudad force applied above the anterior superior iliac spine). (C) Posterior rotation of the innominate requires a superoanterior glide at the SI joint (a cephalad force applied below the anterior superior iliac spine). *(Courtesy of Lee 2004a.)*

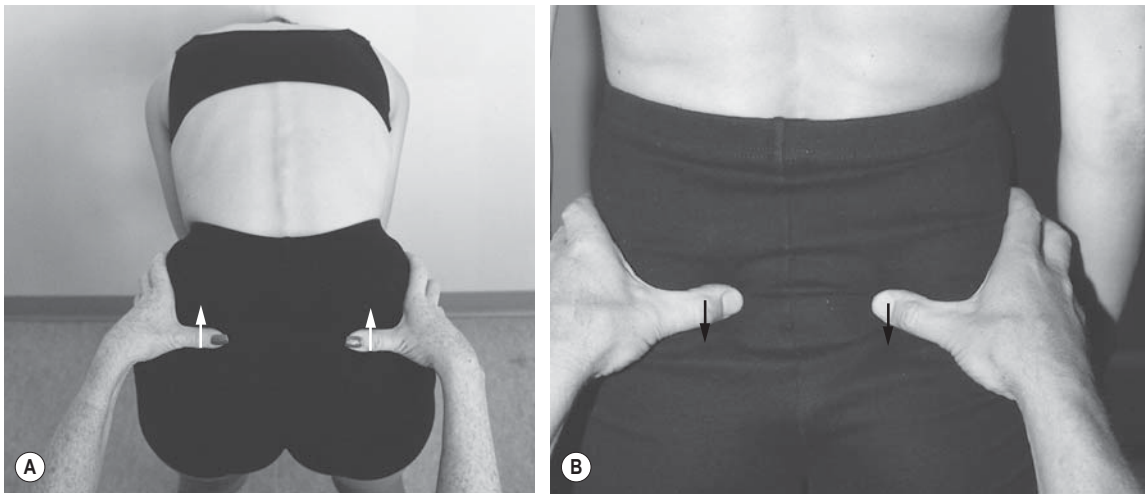

Fig. 2.116 Normal pelvic flexion/extension test. In standing (neutral position), the thumbs are on matching points - resting against the inferior aspect of the posterior superior iliac spines (PSIS; see also Fig. 2.71B). (A) On trunk flexion: the thumbs (= PSIS) move up an equal extent. (B) On trunk extension: the thumbs (= PSIS) move down an equal extent.

BOX 2.5	Functional or dynamic testing of the pelvic girdle

1. Gait analysis (see 'SI joint function during the gait cycle', above)
2. Lumbosacral tests in standing – bending forward and backward
3. Tests carried out weight-bearing on one leg, e.g. the Gillet (kinetic rotational); stork test
4. Active straight leg raising (ASLR) tests augmented by 'form' and 'force' closure

through the SI joints, such as occurs with day-to-day activities. These tests need to evaluate specifically:

1. the passive or 'form' closure system - articular and ligamentous
2. the active or 'force' closure system - myofascial
3. the control system - neural coordination.

Examples of the functional or dynamic tests commonly used are shown in Box 2.5.

Flexion and extension tests

These tests for movement of the lumbo-pelvic-hip complex and transfer of weight-bearing through the complex can be carried out with the person standing or sitting. If the person is seated, have him or her plant the feet on the ground or use a stool for support to improve stability and allow for maximum forward flexion of the trunk. When both SI joints function normally, and barring other influencing factors (e.g. a functional LLD or asymmetry of muscle tension), the movement of the L5 vertebral complex and movement of the sacrum and the ilia (= PSIS) on trunk flexion and extension is as one symmetrical unit rotating on the femoral heads (Figs 2.116, 2.117). A unilateral test will see a thumb placed on the sacrum rotate upward relative to that placed on the PSIS as the sacrum nutates on initial trunk flexion (Figs 2.17, 2.18, 2.118). The tests are carried out as described in Box 2.6.

One can encounter an abnormal sacral flexion/extension test for reasons other than dysfunction of movement of one or other SI joint. As Lee & Walsh already emphasized in 1996, these tests examine lower quadrant function in forward flexion and extension rather than being specific for SI joint mobility. For example, a positive forward-flexion test can result from unilateral restriction of flexion of the hip joint, piriformis muscle spasm or hypertonicity of the hamstrings (Lee 1992b, 2004a). The presence or absence of

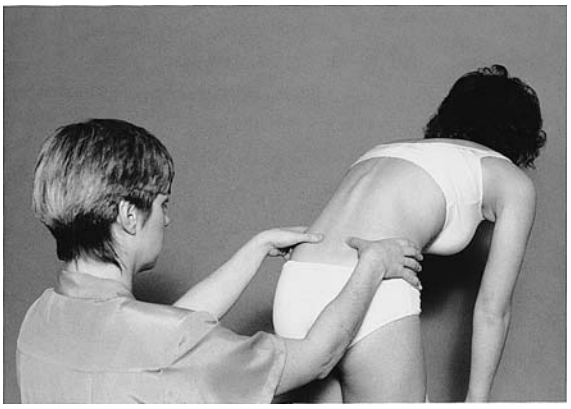

Fig. 2.117 Normal lumbosacral flexion/extension test. Thumbs on the transverse processes of the L5 vertebra travel an equal distance, upward on flexion and downward on extension. *(Courtesy of Lee 1999.)*

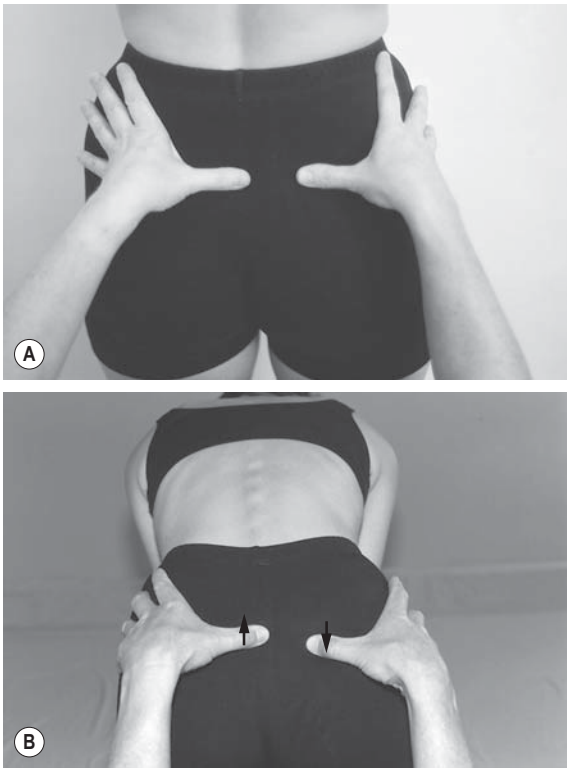

Fig. 2.118 Normal sacroiliac flexion/extension test. (A) Right thumb on the posterior superior iliac spine, left on the adjoining sacral base. (B) On the initial 45 degrees of flexion, the thumb on the sacrum has moved upward slightly relative to that on the ilium with movement of the sacral base into nutation and relative right innominate posterior rotation (see also Figs 2.17, 2.18).

BOX 2.6 Flexion and extension tests

1. A thumb is placed on the identical points on the ilium on each side (e.g. just inferior to the PSIS). The thumbs will move in unison to an equal extent once the sacrum and the innominates start to move together: upward on trunk flexion (Fig. 2.116A), downward on trunk extension (Fig. 2.116B).
2. L5 should also move symmetrically on these tests (Fig. 2.117): fingers placed on the transverse processes move forward and back together to equal extent in the sagittal plane and there is no evidence of any:
   a. rotation around the vertical axis (moving forward on one side and backward on the other in the transverse plane)
   b. side-flexion (moving up on one side and down on the other in the coronal plane).
3. One thumb is then placed on the ilium, against the inferior aspect of the PSIS and the other on the adjoining part of the sacral base (Fig. 2.118A).
   a. On forward flexion, the sacral base will normally move forward into nutation for approximately the first 45 degrees, with some approximation of the thumbs as the innominates flare out (Fig. 2.17A). Sacral nutation may eventually stop but the innominates continue to rotate anteriorly, with relative sacral counternutation (Fig. 2.18A). The stability of the sacroiliac joints is directly related to the range through which nutation can occur (Lee 1999, 2004a).
   b. On back extension, the sacrum normally stays in nutation relative to the innominates (Fig. 2.18C), with some separation of the thumbs.

such conditions will dictate the appropriate treatment. Carrying the test out in a sitting position will decrease, or even eliminate, some of the factors that affect lower quadrant function in standing.

Clinical correlation: flexion/extension tests

Sacroiliac joint 'upslip' and anatomical leg length difference

Neither an 'upslip' in isolation nor an anatomical (true) LLD is associated with evidence of movement dysfunction on the flexion/extension tests. With a 'right upslip', for example, the right PSIS remains higher than the left to an equal extent throughout the full range of flexion and extension carried out in either standing or sitting (Fig. 2.119B). Findings are similar when testing someone with an anatomical (true) long right leg but only in standing; whereas the PSIS and other pelvic landmarks will be level in sitting.

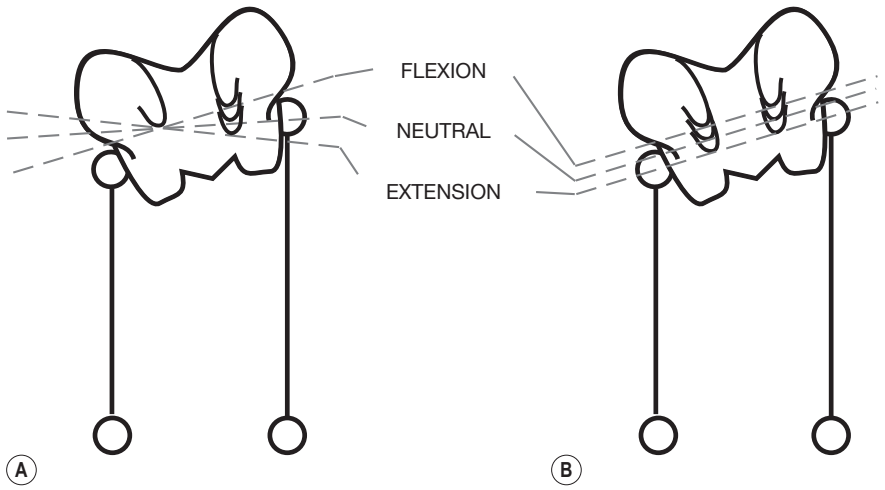

Fig. 2.119 Normal and abnormal changes in the position of the right relative to the left posterior superior iliac spine (PSIS) with trunk flexion and extension in standing. (A) With 'locking' of the right sacroiliac joint: excessive movement of the right PSIS upward with flexion, downward with extension relative to the left. (B) With an anatomical (true) leg length difference (right leg long) or a 'right upslip': the right and left PSIS will move upward and downward in unison and to an equal extent.

'Rotational malalignment'

Assuming an otherwise normal lower quadrant function, these tests will be abnormal when the excessive 'anterior' or 'posterior' rotation of an innominate bone has resulted in:

1. asymmetric movement of the pelvic ring on the femoral heads
2. a decrease of the amount of movement possible at one SI joint relative to the other, or even
3. a complete loss of movement, or 'locking', of one SI joint.

With 'locking' of the right SI joint, for example, the sacrum and the right innominate now move as one unit on trunk flexion and extension. Therefore, the right thumb will move relatively further than the left, upward on flexion and downward on extension (Figs 2.119A, 2.120). Remember that, with 'rotational malalignment', the right and left PSIS are usually no longer level in the neutral position, standing or sitting. To start with, the right may be noticeably higher or lower than the left. Therefore, with 'right anterior' rotation, and especially with a coexistent 'locking' of the right SI joint,

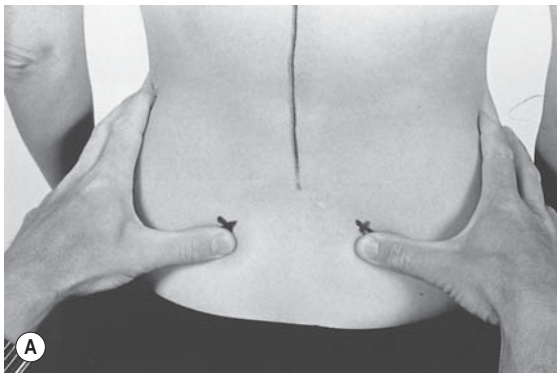

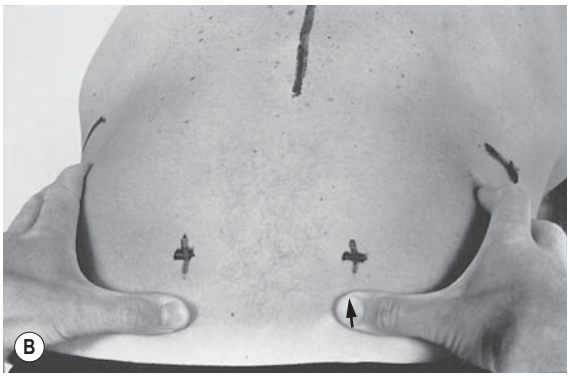

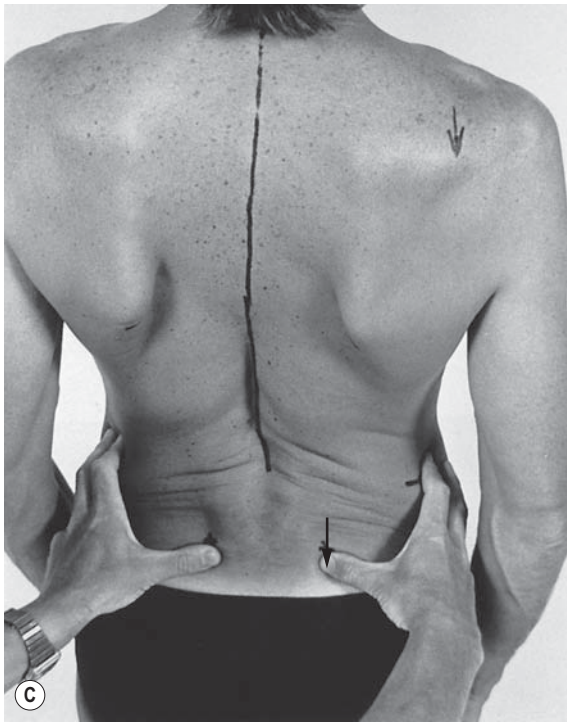

Fig. 2.120 Abnormal sacroiliac flexion/extension tests with 'rotational malalignment': right anterior and 'locked', left posterior. (A) In standing upright, the level of right posterior superior iliac spine (PSIS) is just above that of the left. (B) On trunk flexion: the right PSIS has moved even further upward. (C) On trunk extension: the right PSIS has moved below the left. Note: extension has accentuated the scoliotic curves, making the lumbar segment especially easier to discern.

comparison of the right and left thumb placed on the respective PSIS would show:

1. on forward flexion:
   a. a right PSIS that was lower than the left one to start with in the neutral standing position could end up level with or higher than the left
   b. if the right PSIS was already higher than the left one to start (Fig. 2.120A), the difference between them would increase (Fig. 2.120B)
2. on trunk extension:
   a. a right PSIS that was higher in the neutral position might become level with or end up lower than the left one (Figs 2.119A, 2.120C)
   b. if it was lower than the left to start with, the difference between them would increase.

Similar changes would occur on the flexion-extension test on comparing movement of a thumb placed on the PSIS to that of the other one placed at the same level on the sacrum (approximately at S2). In the person presenting with the 'left anterior and locked' pattern, the changes in relative PSIS movement would be the opposite to those discussed above for 'right anterior and locked'.

As with the 'sitting-lying' test, it is the relative change in position on these flexion-extension tests that is of prime importance to help diagnose the presence of a 'locking' of a joint and 'rotational malalignment' versus an 'upslip' (where the landmarks, though asymmetric, still move in unison and to an equal extent, as with a true LLD; Fig. 2.119B).

Ipsilateral kinetic rotational test (Gillet test, stork test)

The Gillet test is a test for:
1. the ability to balance while weight-bearing on one leg
2. the ability for parts of the pelvic girdle on the non-weight-bearing side to continue to undergo some rotation while those on the weight-bearing side become 'fixed' or stabilized as load is transferred through the pelvic girdle onto that leg.

The 'kinetic' tests can assess dynamic function of the pelvis with the person in the:

1. standing flexion phase
   a. ability to flex the hip on the non-weight-bearing side, to test ease of movement and mobility in the lumbo-pelvic-hip complex and, in particular, the SI joint
2. standing support phase
   a. ability to transfer a load through the low back, pelvis and hip onto the weight-bearing side
   b. ability of the pelvis 'to allow some intrapelvic rotation' (Hungerford 2002) while remaining stable in its starting position in both the coronal and sagittal plane (Hungerford et al. 2004)

Single-support 'kinetic' test

The full test entails assessing comparitive movement of the sacrum/innominates in the non-weight-bearing and support phase on active flexion and extension of the hip joint. For a test of the right side, the examiner initially places the right thumb against the inferior aspect of the right PSIS and the left thumb on the midline of the sacrum at the S2 level (Fig. 2.121A). The test is carried out as follows:

Right single non-weight-bearing phase

1. ***'posterior rotational' or 'flexion' tests*** (Fig. 2.121B)
   a. Right hip flexion to 90 degrees will normally cause the right innominate to rotate posteriorly relative to the sacrum. Therefore, the thumb on the right innominate will move downward relative to the left thumb resting on the sacrum (Fig. 2.121C). Flexion of the right hip higher than horizontal should result in further posterior rotation of the right innominate and downward displacement of the right thumb (i.e., right PSIS).
   b. With the right innominate posterior rotation, there will also be some simultaneous:
      i. left rotation of the sacrum around the vertical axis and torquing around the left oblique axis, as well as
      ii. left axial rotation of L5 coupled with side-flexion of the vertebral complex (Figs 2.21, 2.41).

The same test is then carried out on the left side for comparison to the movement seen on right hip flexion (Fig. 2.122). Comparative decrease of ease of

Fig. 2.121 Normal posterior kinetic rotational (Gillet) tests: hip flexion. (A) Starting position for the test on the right (the reverse of that seen in Fig. 2.122A). (B) Set-up for testing, with a side table to provide support should balance become a problem. (C) Right hip flexion: posterior rotation of the right innominate displaces the right thumb downward relative to that on the sacrum by an amount equal to that observed on carrying out the test on the left side (see Fig. 2.122B).

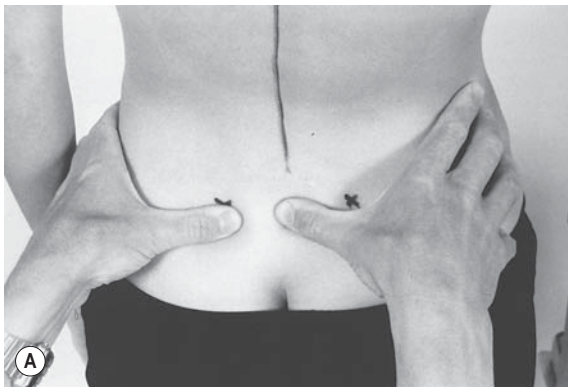

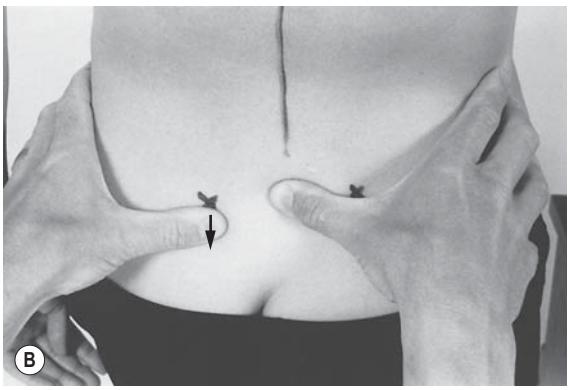

Fig. 2.122 Normal left Gillet test. (A) Starting position for the test: the left thumb placed against the inferior aspect of the left posterior superior iliac spine (PSIS), the right on the sacral base just lateral to the median sacral crest and level with the left thumb. (B) Left hip flexion: posterior rotation of left innominate displaces the left thumb (= PSIS) downward relative to that on the sacrum.

movement and/or abnormal movement may suggest impaired function involving the lumbo-pelvic-hip complex on one side.

2. ***'anterior rotational' or 'extension' tests***

   To test the right side, the person weight-bears on the left and increasingly extends the right hip joint (Fig. 2.123). Normally, this results in findings opposite to those seen on right hip flexion, namely: anterior rotation of the right innominate relative to the sacrum, with right axial rotation of the sacrum and right axial rotation and side-flexion of L5. The right thumb will move upward relative to the left one placed on the sacrum. Again, the left side is also tested to allow for comparison of range and ease of movement and mobility.

Right single-support phase

The stability required to turn the sacrum and an adjoining innominate into one unit capable of transfering weight through the ipsilateral SI joint depends in large part on:

1. alignment of the sacrum and ilium
2. intact, strong supportive ligaments
3. contraction of the muscles that stabilize that SI joint (e.g. iliopsoas, piriformis and gluteus maximus),

Fig. 2.123 Normal anterior kinetic rotational (Gillet) test: hip extension. Starting position for the test on the right side as in Fig. 2.121A (for the left: as in Fig. 2.122A). On right hip extension: anterior rotation of the right innominate displaces the right thumb (=PSIS) upward relative to the left one (resting on the sacrum).

4. the pelvis itself being properly aligned with the spine and femur

To test the single-support phase on the right side, place the right thumb below the PSIS and the left on the sacral midline at S2 level to start (Figs 2.121A, 2.124A). The pelvis functions best when in a vertical position relative to the femur, for weight transfer both through the pelvis and the hip joint. As the person raises the left leg and transfers weight entirely onto the right, 'the innominate should either move toward the vertical position (extend) or remain vertical relative to the femur' to maintain the stability of the unit (Fig. 2.124B). Therefore, when observing for any movement between the thumbs:

1. ***on a normal single-support test***

   There may be no movement at all or some downward movement of the right thumb, indicative of posterior rotation of the innominate relative to the sacrum (i.e., extension relative to the femur; Fig. 2.124B).

2. ***on an abnormal test***

   Changes indicative of 'failed load transfer through the pelvic girdle' (Hungerford et al. 2001, 2004; Hungerford 2002) include:

   a. the right thumb may move upward or outward, indicative of innominate rotation anteriorly or internally relative to the sacrum, respectively
   b. conversely, flexion of the innominate relative to the femur would signify failed load transfer through the hip joint and is recognized as 'a less stable position for load transfer through both the pelvis and the hip joint.' (Lee 2004a).

Comparitive kinetic tests: right versus left side

A normal posterior or anterior rotational test will show the amount of movement of the thumb on the right innominate to be equal to that detected on the left side. A positive (abnormal) kinetic rotational test can occur with movement dysfunction of the SI joint and may be partial or complete. There are, therefore, two possible findings when the dysfunction involves the right SI joint.

1. ***a completely abnormal test***

   'Locking' of the right SI joint is present and does not allow for any posterior rotation of the right innominate relative to the sacrum. For example, in the right 'posterior rotational' or 'flexion' test

Fig. 2.124 Testing for ability to transfer weight through the hip and SI joint. In the one-leg standing test (single-support phase), the innominate should: (A) remain posteriorly rotated relative to the sacrum; (B) extend relative to the femur (arrow) or remain vertical. This is a stable position for load transfer through the hip joint. *(Courtesy of © Diane G. Lee Physiotherapist Corp.)*

shown in Fig. 2.125, the right thumb (PSIS) fails to move relative to the left (sacrum) on initial right hip flexion (Fig. 2.125A). On attempting to flex the right hip more than 90 degrees, the right thumb will actually begin to move upward (Fig. 2.125B). This finding is in keeping with the fact that further right hip flexion is accomplished by having the 'locked' sacrum and right innominate rotate as one unit, counterclockwise around the sacral axis in the coronal plane. The test will be normal on the left side.

2. ***a partially abnormal test***
   Limited movement between the right sacrum and innominate is possible, allowing some separation of the two thumbs, but perceptibly less on the right side compared to the freely-moving 'unlocked' left side.

A positive kinetic rotational test may also occur with intrinsic hip joint abnormality, lumbar spine scoliosis or leg length inequality (Bernard & Cassidy 1991) as well as with various lesions of the ipsilateral 'ilio-sacral' joint or the lumbar spine (Fowler 1986). Therefore, one should never rely on just one of the above test in isolation when attempting to establish the diagnosis of malalignment and SI joint dysfunction.

Clinical correlation: kinetic tests

1. Anatomical LLD, SI joint 'upslip' and 'outflare/inflare' The test is negative.
2. 'Rotational malalignment'

The test may be positive, with evidence of a partial or complete loss of SI joint mobility or 'locking' on one side. This 'locking' may resolve completely or

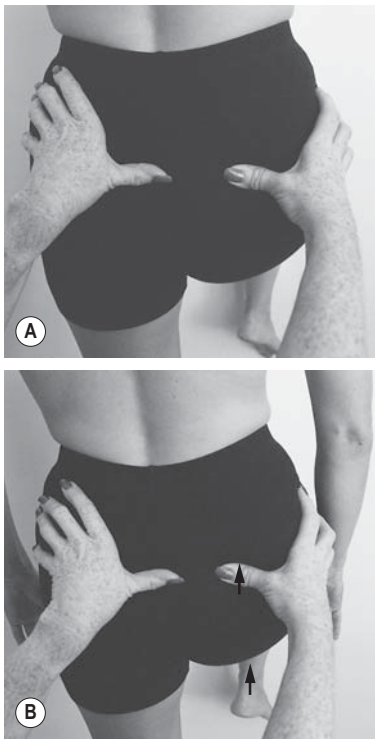

Fig. 2.125 Abnormal right kinetic rotational test (right sacroiliac joint 'locked'). (A) Right hip flexion: the right posterior superior iliac spine (PSIS) fails to drop down relative to the sacral base (relatively unchanged from Fig. 2.121A, view of person standing on both feet). (B) On increasing right hip flexion: the right PSIS actually moves upward – the sacrum and right innominate are moving together as one 'locked' unit, counterclockwise in the coronal (frontal) plane.

come back only rarely in the early course of treatment, even though malalignment of the pelvis is still recurring and any realignment achieved at any time during this stage is more likely to be maintained for only short periods of time.

EVALUATION OF LOAD TRANSFER ABILITY: ACTIVE STRAIGHT LEG RAISING

Active straight leg raising (ASLR), with or without reinforcement to engage the 'form' and 'force' closure mechanisms, can be used to:

1. evaluate the person's ability to transfer load from the trunk through the lumbosacral junction, pelvic girdle and hip joint to the lower extremity, either in prone or supine-lying
2. help localize pain originating from these regions

Right ASLR in supine-lying normally results in changes similar to those that occur during the gait cycle as the right leg swings forward, in preparation for heel-strike and weight transfer, namely:

1. posterior rotation of the right innominate and relative anterior rotation of the sacral base on the right, with sacral nutation, tightening of the sacrotuberous, sacrospinous and posterior SI joint ligaments (Figs 2.19A, 2.21), and stabilization of the right SI joint (DonTigny 1985)
2. a tendency of the whole pelvis to rotate around the vertical axis toward the raised right leg (Jull et al. 1993, 2000)
3. a simultaneous rotation at the lumbosacral junction in the opposite direction, with tightening of the right iliolumbar ligaments and a further decrease in movement of the right SI joint

Provided the local and global systems are functioning normally, the overall effect on carrying out a right ASLR is a stabilization of both the lumbosacral junction and the right SI joint, which in turn allows for a more effective load transfer from the spine to the leg on that side (Snijders et al. 1993a). In a stable pelvis, any adjustments are minimal; movement is limited to the hip joint (Fig. 2.126A). Increasingly strained movement of the lower extremity, pelvis or thorax suggests that there is a problem (Fig. 2.126B). Mens et al. in 1997 described how a decreased ability to actively straight leg raise while lying supine seemed to correlate with an abnormally increased mobility of the pelvic girdle, as evaluated by movement at the symphysis pubis on X-ray (Fig. 2.102A). In the attempt to improve pelvic stability, typical compensatory measures include:

1. activation of muscles in the local and global systems to stabilize the trunk, lumbosacral and pelvic regions (Fig. 2.126B)
2. initial internal rotation of the left leg, then rotation of the pelvis and finally thorax toward the side on which the ASLR is being carried out
3. Valsalva (breath holding) manoeuvre with abdominal distension (Fig. 2.127A), and sometimes obvious diastasis of the linea alba (Fig. 2.127B)
4. overactivity of external and internal obliques, with indrawing of chest cage and outflare of lower ribs, respectively, and overall limitation of lateral costal expansion on inspiration
5. overactivity of erector spinae, with thoracic spine extension

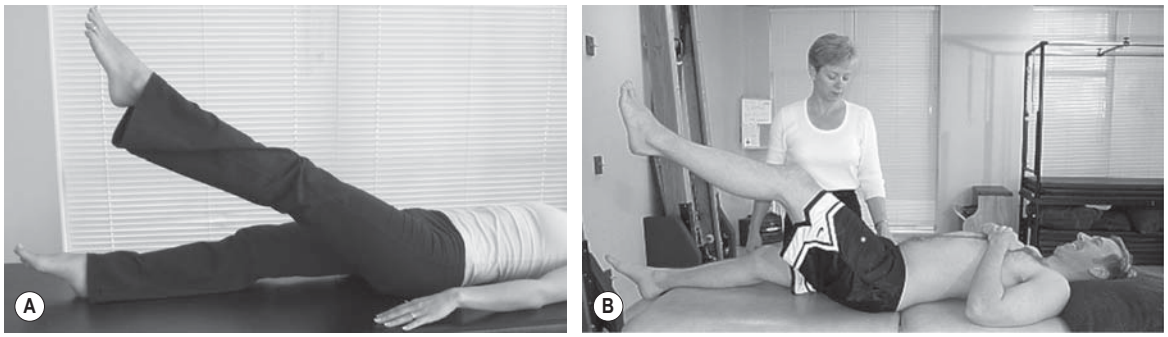

Fig. 2.126 Active straight leg raising (ASLR) used as a 'clinical test for measuring effective load transfer between the trunk and lower limbs' (p106). (A) An optimal ASLR. The only joint moving is the hip joint. The thorax, lumbar spine and pelvic girdle remain stable due to the co-activation of the local and global systems. (B) ASLR with loss of lumbopelvic stability - note the abdominal bulging, anterior pelvic tilt, and thoracic extension as well as the extreme effort required to lift the left leg. *(Courtesy of © Diane G. Lee Physiotherapist Corp.)*

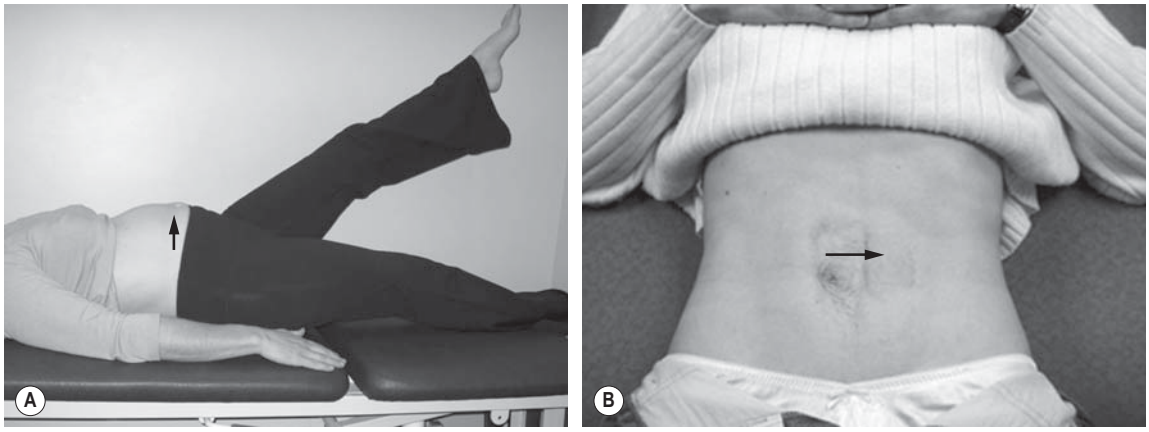

Fig. 2.127 Weakness of abdominal wall fascia and muscles. (A) ASLR with excessive abdominal bulging (arrow) on active straight leg raising and breath-holding: a Valsalva manoeuvre. (B) A large three-finger width diastasis of the linea alba. *(Courtesy of Lee 2004a.)*

Note is made of the following:
1. the degree of active straight leg raising (ASLR) possible on each side
2. the ease with which the ASLR is carried out (both as observed and as reported by the person)
3. any compensatory movements of the pelvis or trunk; these usually involve rotation of the pelvis and opposite leg toward the side of the leg being raised

The ASLR test is carried out both in supine and prone-lying. The person is initially observed performing a functional test, namely comparative unassisted straight leg raising, one leg at a time (Figs 2.128A, 2.129A). In the past, emphasis was on first observing the maximum hip flexion that could be achieved actively on each side and any obvious compensatory measures used in an attempt to improve that range of motion. ASLR was then repeated with addition of measures known to selectively reinforce 'form' and 'force' closure, noting particularly any uni- or bilateral increase in the maximum ROM achieved. Basing the test on evaluation of maximum hip flexion range, unfortunately, could be limited by problems other than SI joint instability, such as:

1. hip joint degeneration, contracture of surrounding structures (ligaments, capsule, muscles such as the hip extensors)

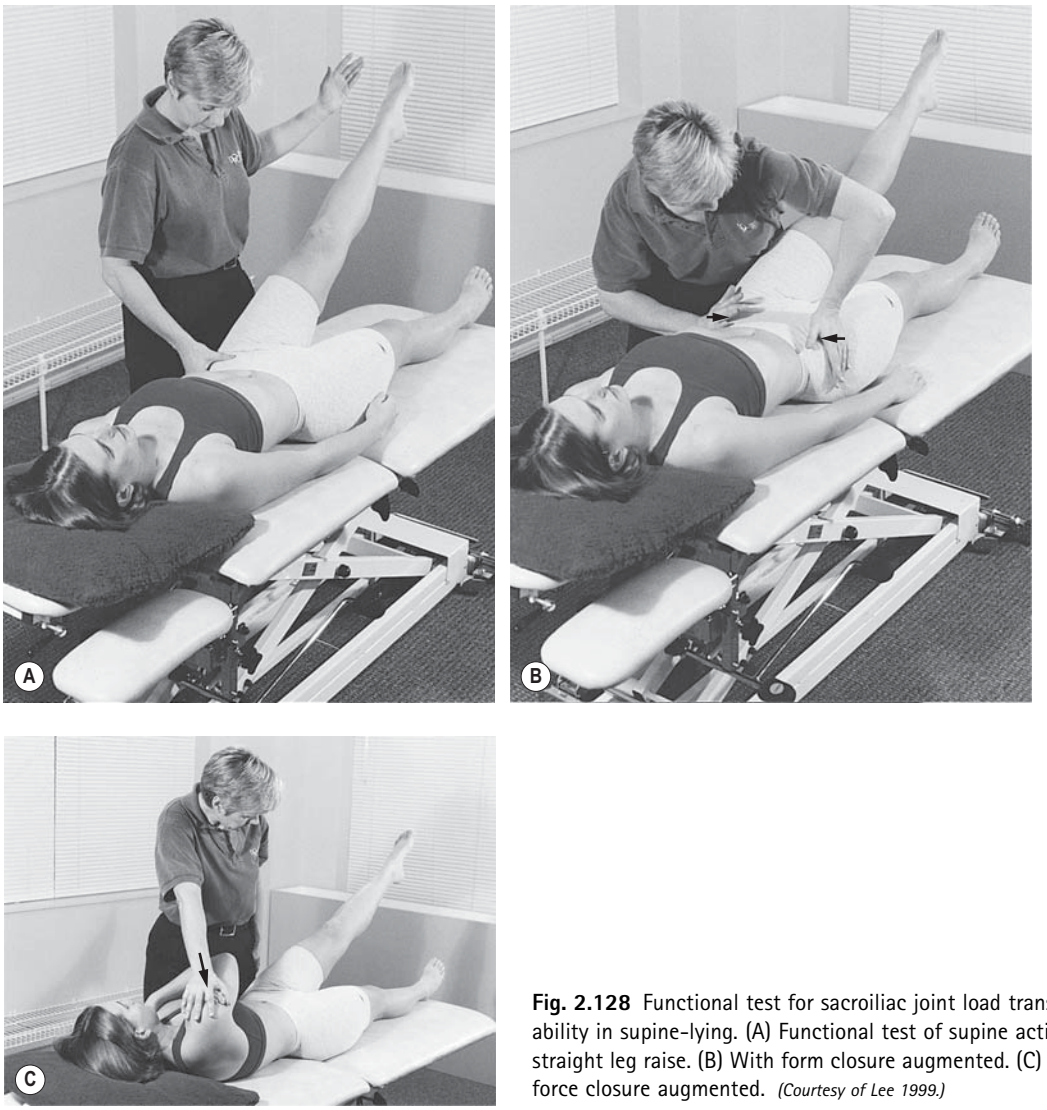

Fig. 2.128 Functional test for sacroiliac joint load transfer ability in supine-lying. (A) Functional test of supine active straight leg raise. (B) With form closure augmented. (C) With force closure augmented. *(Courtesy of Lee 1999.)*

2. pain elicited with pressure on a tender point as weight-bearing shifted across the sacrum/posterior innominate on doing the test
3. increasing tension in the posterior structures with posterior innominate rotation

More recently, stress has been on comparing the ease with which the ASLR test is carried out over a limited range (20-30 cm appears to be the norm) with and without re-enforcement measures (Mens 1999, 2001, 2002; Lee 2004a, 2007b; Richardson et al. 1999; Figs 2.128, 2.129). If dysfunction of load transfer through the pelvis is suspected, supplemental tests are indicated to define whether there is a problem attributable to the passive and/or active system ('form' and 'force' closure, respectively). Any improvement with addition of these measures would be suggested by:

1. an increase in the ease with which this manoeuvre is now carried out over the same range
2. a decrease in pain
3. a decreased need to rely on compensatory measures

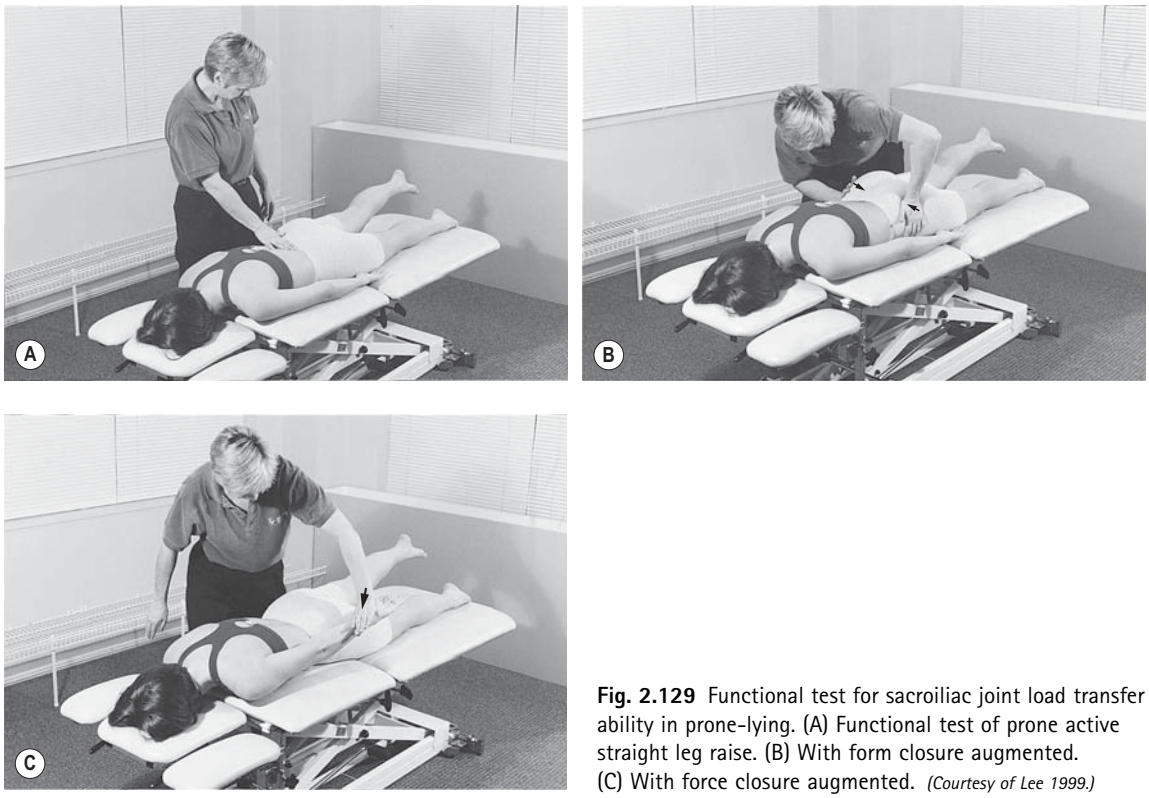

Fig. 2.129 Functional test for sacroiliac joint load transfer ability in prone-lying. (A) Functional test of prone active straight leg raise. (B) With form closure augmented. (C) With force closure augmented. *(Courtesy of Lee 1999.)*

Form closure (passive system) to supplement ASLR

An augmentation of 'form' closure which affects either the symphysis pubis or SI joint or both may be achieved with a medially directed compression force applied at different levels to the lateral aspect of the innominates. The repeat ASLR is carried out simultaneous with or immediately after application of the force (Figs 2.128B, 2.129B). Any improvement achieved suggests that the reinforcement has been able to partially or completely:

1. compensate for loss of the passive supporting system (e.g. joint laxity attributable to osteoarthritic degeneration and/or ligament lengthening or tear)
2. simulate the force produced by 'inner' and/or 'outer' core muscles; as documented by Lee (2004a, 2007b), some of the correlates of which sites were compressed and the muscles affected include:
   a. compression of anterior pelvis at level of ASIS bilaterally, simulating action of transversus abdominis (Fig. 2.128B)
   b. compression of posterior pelvis at level of PSIS bilaterally, simulating action of the sacral multifidi (Fig. 2.129B)

Effects evoked by compression at the pubic level (Fig. 130A), across the pelvis (Fig. 2.130B) and also by a decompression manoeuvre (Fig. 2.130C), are as illustrated.

The aim is to find 'the location where more (or less) compression reduces the effort necessary to lift the leg - the place where the patient noted: 'that feels marvelous!' (Lee 2004a: 107). This information can be useful in designing a sacral belt, compression shorts or combination (see Ch. 7) that:

1. actually applies pressure to a specific point or points in muscle, ligament or overlying bone that gives the most relief on the test, rather than applying uniform pressure at one level in the transverse plane (usually lying just below the ASIS), as has been the custom in the past (Figs. 7.34, 7.35).
2. applies selective medial pressure to the pelvic ring for effect; for example:

Fig. 2.130 (A) Compression of the right anterior pelvis and left posterior pelvis stimulates the action of the right transversus abdominis and the sacral multifidus.
(B) Compression of the anterior pelvis at the level of the pubic symphysis stimulates the action of the pelvic floor muscles.
(C) Decompression (lengthening) applied obliquely between the thorax and pelvis stimulates releasing the oblique sling system. The arrow indicates the direction of force applied by the therapist's hands. (See also Ch. 7 and Figs 7.34–7.36).
(Courtesy of © Diane G. Lee Physiotherapy Corp.)

a. to the innominates at a level above, at, or below the level of the ASIS to compress the anterior, decompress the posterior SI joint at that level bilaterally
b. to the lower innominate to put pressure on the pubic joint
c. to the innominates at points known to improve action in certain core muscles, if that has been helpful on the ASLR test; e.g. right ASIS and left PSIS, to stimulate the action of right transversus abdominis and left sacral multifidus (Fig. 2.130A)

'Force' closure (active, motor control system) to supplement ASLR

Improvement achieved by an augmentation of force closure suggests that the problem is primarily the result of a loss of strength in the supporting muscles, failure to coordinate muscle activation, or a combination of these.

Activating the 'inner core' system

ASLR is attempted while contracting transversus abdomini, multifidi, thoracic diaphragm and/or the pelvic floor muscles (Figs 2.28, 2.29, 2.53).

Activating the 'outer core' or global system

ALSR is repeated bilaterally to evaluate whether improvement has been achieved by activating parts of the global system on either side. For example, when testing the anterior oblique system, if the right side appears normal and only the left side shows improvement on reinforcement, it would suggest that there is a problem involving the left system that will hopefully respond to selective treatment.

1. ***Anterior oblique system***
   After first carrying out left active straight leg raising in supine lying, the person is asked to repeat the manoeuvre immediately after having activated the anterior oblique system, or sling (Fig. 2.39). Activation is accomplished by fully flexing the right elbow, then reaching with that elbow over toward the left knee,

effectively flexing and rotating the trunk toward the left (Fig. 2.128C). Activation can be further augmented by resisting trunk rotation with pressure against the right anterior shoulder.

2. ***Posterior oblique system***
   After first carrying out the right ASLR in prone-lying, the person would then be asked to repeat hip extension immediately after having first extended and medially rotated the left arm against a steady resistance offered by the examiner (Fig. 2.129C). During this test, note is also made of the sequence of muscle activation: increasing resistance should first activate left latissimus dorsi, then augment tension in the thoracodorsal fascia to prime the rest of the posterior oblique system prior to actively extending the right leg starting with gluteus maximus and followed by the hamstrings, in particular biceps femoris (Fig. 2.35, 2.37).

SIMULTANEOUS BILATERAL SI JOINT MALALIGNEMNT

Discussion has been restricted primarily to the two major presentations, namely 'rotational malalignment' and SI joint 'upslip', both of which result in an asymmetric distortion of the pelvic ring and are associated with the 'malalignment syndrome' (Ch. 3). 'Outflare/inflare' lacks the features of the 'malalignment syndrome' but also causes a specific distortion, perhaps less dramatic, with some asymmetry and other biomechanical changes. For the sake of completion, brief mention must be made of some problems that relate to alignment but present with a symmetrical pelvic ring and also lack the features typical of the 'malalignment syndrome'. The diagnosis is often delayed or missed altogether because of a paucity of physical findings or difficulty in interpreting the signs and symptoms.

SYMMETRICAL MOVEMENT OF THE INNOMINATES RELATIVE TO THE SACRUM

Excessive simultaneous bilateral rotation of the innominates, either 'anteriorly' or 'posteriorly', and bilateral 'upslips' or 'downslips' can occur (DonTigny 1985, Richard 1986). These present primarily with signs of movement restriction in one direction, along with a displacement of the landmarks that, however, remains symmetrical and may, therefore, make any abnormality difficult to diagnose. Presentations to consider include:

Excessive 'bilateral anterior' innominate rotation

This presentation can occur if someone:

1. sustains an upward force through both lower extremities simultaneously when they are

Case History 2.1

A woman suffered a shear injury of her right sacroiliac joint when her right leg shot out in front of her on a wet floor and she landed primarily on her right buttock. The right sacroiliac joint was unstable in both the anteroposterior and craniocaudal planes, making it impossible to maintain any correction of the malalignment even for short periods of time. The results of active straight leg raising (ASLR) tests were as follows:

1. Right ASLR raising was to 40 degrees flexion in supine, 10 degrees extension in prone-lying, with pain felt in both positions; the values for the left were 70 and 30 degrees respectively, both pain free. Lateral compression (augmented 'form' closure) improved the values for the right side to 70 degrees supine and 30 prone, with report of a decrease in the associated pain; the values on the left side remained unchanged.
2. Activation of 'inner core' and the anterior and posterior oblique systems (augmented 'force' closure) failed to improve the values on either side.

The diagnostic impression was that of a shear injury of the right sacroiliac joint and a loss of 'form' closure, the instability probably being attributable to loss of the ligamentous support. 'Force' closure, derived from core muscle strength and coordination, appeared to be intact. The initial treatment consisted of using a sacroiliac belt and undergoing a course of prolotherapy injections to strengthen and tighten up the ligaments surrounding the right sacroiliac joint. Once ligamentous support had been regained, attempts at realignment and strengthening of the back, pelvic and hip girdle muscles were successfully resumed (see Ch. 7).

positioned with the hip flexed at, or nearly, the same angle (Fig. 2.51A)
2. falls onto the buttocks while the hips and knees are drawn up, so as to land on the anterior aspect of both ischial tuberosities simultaneously

There can result a bilateral restriction of hip flexion and straight leg raising, attributable to:

1. the mechanical limitation caused by impingement of the femoral head against the anteriorly rotated superior acetabular rims (Figs 2.47A, 2.109)
2. the increased tension in gluteus maximus, hamstrings and the posterior SI joint ligaments attributable to the increase in the distance between their origins and insertions
3. bilateral increase in hip extension, with the posterior rotation of the acetabular rim and relaxation of hip flexors (e.g. iliopsoas, TFL, rectus femoris)
4. a symmetrical upward movement of the PSIS bilaterally, making these landmarks more prominent
5. symmetrical downward movement and bilateral depression of the ASIS and pubic bones
6. sacral rotation into relative counternutation, a position of SI joint instability (Fig. 2.11B)

Excessive 'bilateral posterior' innominate rotation

This presentation can occur with a force that acts simultaneously:

1. upward on both lower extremities, when they are positioned with the hip in some extension to about the same degree bilaterally, or
2. onto the posterior aspect of the ischial tuberosities

There would result changes that are the opposite to those documented for 'bilateral anterior rotation' above; namely, relative sacral nutation (= stability) and simultaneous bilateral:

1. restriction of hip extension by the posterior rotation of the inferior acetabular rim and the increased tension in the hip flexor muscles
2. upward displacement of ASIS and pubic bones while the PSIS moves downward bilaterally

SACRAL ROTATION AROUND THE CORONAL AXIS

Some of the abnormal presentations involve excessive rotation of the sacrum around the coronal axis in the sagittal plane. For example, falling and landing on the sacral apex or the coccyx can rotate the base backward, into excessive counternutation; whereas a blow to the base can rotate it forward, into excessive nutation. Although landmarks are altered, their symmetry is preserved and that may be misleading. Richard (1986, p. 26) described the following:

'Bilateral sacrum anterior'

This lesion can result with hyperextension of the pelvis and spine. The sacrum becomes fixed in counternutation, with the base actually backward and the apex forward in 'flexion angulation'. The sacrospinous ligaments, which come to play the role of a pivot, are put under increased tension and are at risk of injury, as are the long dorsal sacroiliac ligaments bilaterally (Fig. 2.19B); whereas the pelvic floor muscles become hypotonic (Fig. 4.44C). The sacral sulci diminish or disappear, and the apex becomes less prominent. The lumbar lordosis is decreased or abolished, and the lumbar segment feels 'stiff' when one applies pressure to the spinous processes. The person may complain of back pain and difficulty in stooping forward.

The lumbosacral plexus bilaterally is put under increased tension (Fig. 4.15). A separation of iliacus and rectus femoris origins and insertions increases tension in these muscles bilaterally which, in turn, limits hip extension and decreases the space available for the exiting femoral and obturator nerves (Figs 4.14 and 4.15, respectively). There may be symptoms of bilateral groin discomfort and paraesthesias, suggestive of femoral and/or obturator nerve irritation, and the femoral stretch test may be positive.

'Bilateral sacrum posterior'

Excessive backward rotation of the apex and forward rotation of the sacral base (nutation) is sometimes seen following excessive forward flexion of the trunk and pelvis. It results in a uniform deepening of the sacral sulci and a uniform increase in the prominence of the inferolateral sacral angles and the sacral apex. The lumbar lordosis is increased; the lumbar segment feels supple and elastic when pressure is applied to the spinous processes. Resting pressure on the facet joints is increased and nerve roots may be compromised by a narrowing of the intervertebral foramina.

Tension in the sacrotuberous ligaments and hamstrings is increased by a separation of their origin and insertion (Fig. 2.19A); hip flexion is reduced, and all these structures, which may be tender to

palpation, are now at an increased risk of injury. Pelvic floor dysfunction can be another complication as tension in the pelvic floor is increased with the apex rotating backward, especially if there is a coexistent excessive 'extension angulation' of the coccyx (see Fig. 4.44B). The person may complain of recurrent cramps in the hamstrings, and of pain from the lower sacral region and ischial attachments of the sacrotuberous ligaments.

These conditions are mentioned mainly to point out that there are other presentations involving rotation of pelvic structures that can be a major cause of debility. Unlike with an 'upslip' or 'rotational malalignment', however:

1. the symmetry of the landmarks is preserved
2. there is no associated 'malalignment syndrome'

THE STANDARD BACK EXAMINATION CAN BE MISLEADING

It cannot be emphasized strongly enough that the standard medical back examination is often completely normal in the person presenting with malalignment. Indeed, it may be expected to be normal depending on the scope of the examination, which usually will be limited to looking at the back and asking the patient to go through trunk flexion, extension, side-flexion and simultaneous extension with rotation to right and left, primarily to see if any of these provoke pain. There is less emphasis, if any, on whether there is a comparitive loss of range of motion, asymmetry of landmarks and/or limitation of a particular pattern of movement that would be in keeping with an underlying problem, such as malalignment (Ch. 3). The examination may include tests to stress specific joints (e.g. hips, facet joints, discs). However, if symptoms are due to an alignment problem, these manoeuvres may fail to provoke pain as these joints are not necessarily stressed:

1. by the underlying presentation of malalignment to actually becoming symptomatic, or
2. by the examiner to the point of provoking the pain

As will become increasingly evident in the following chapters, the different presentations of malalignment stress specific joints and soft tissues of the pelvis, spine and lower extremities, typically in an asymmetrical pattern. On doing the standard musculoskeletal examination, findings may be limited to noting tenderness in some ligament, tendon or muscle. Detection of such tenderness is too often misinterpreted as defining a localized problem (e.g. a 'bursitis' or a 'stretched' tendon or muscle). The examination does not necessarily stress the structures typically stressed by malalignment, or in such a way or hard enough as to actually provoke pain. Usually, in the standard examination, there is:

1. no comparison of the degree of tenderness, leave alone tension, detectable in the same structure on the opposite side
2. no search for the more global, but still specific, predictable patterns seen with involvement of the lumbo-pelvic-hip complex that define the various presentations of malalignment.

Evaluation of any abnormal patterns, if persued, is usually limited to observations that the pelvis is up on one side, one shoulder is lower than the other, the right or left leg is 'longer' (with no indication of whether this difference was seen in standing, sitting or lying) and failure to observe if a change in position altered the findings - all observations that would help establish whether malalignment is present and what particular presentation, to allow one to proceed with appropiate treatment.

Unfortunately, the fact that the limited standard examination has failed to elicit pain or establish that there are patterns of asymmetry signifying malalignment is present is often interpreted to mean that the person does not have a problem, when the real problem is that the clinician's examination skills are limited and, in fact, inadequate for establishing the diagnosis of malalignment. At the same time, it must be remembered that even if the examiner is familiar with the tests for malalignment, the diagnosis of this condition should be based on the findings on several forms of assessment, not just on the results of one or two tests alone. The examination should include an evaluation of:

1. leg length in more than one position
2. the typical patterns of asymmetry of landmarks, muscle strength and tension, weight bearing, joint ranges of motion as well as other aspects of the 'malalignment syndrome' (Ch. 3)

> Once the presence of malalignment has been established, one must avoid falling into the trap of automatically assuming that all of the person's complaints are attributable to the malalignment.

For those familiar with malalignment and the problems it presents, there is never any excuse for not

carrying out at least a basic orthopaedic, neurological and vascular examination in order to rule out other pathology. Only this will allow one to determine, with some degree of certainty whether:

1. some or all of the person's symptoms are attributable to the malalignment
2. there is possibly an underlying/associated medical problem that is being covered-up by the the malalignment and
3. there is a need to proceed with other investigations and/or treatment efforts in addition to realignment

The intent of this chapter has been to provide a sound basis for the examination techniques that will be of help in recognizing whether a biomechanical problem such as malalignment of the pelvis and spine is present and could account for a person's complaints. Chapter 3 will present the 'malalignment syndrome': the secondary effects on the soft tissues and joints caused be two of the three common presentations: namely, 'upslip' and 'rotational malalignment'. Recognizing the features of this syndrome should further aid in making the distinction between problems caused by the malalignment, an underlying medical problem, or both.