

9

Occlusion and periodontal health

J. De Boever, A. De Boever



Synopsis

Periodontal structures depend on functional occlusal forces to activate the periodontal mechanoreceptors in the neuromuscular physiology of the masticatory system. Occlusal forces stimulate the receptors in the periodontal ligament to regulate jaw movements and the occlusal forces. Without antagonists the periodontal ligament shows some non-functional atrophy. Tooth mobility is the clinical expression of the viscoelastic properties of the ligament and the functional response.

Tooth mobility can change due to general metabolic influences, a traumatic occlusion and inflammation. Premature contacts between the arches can result in trauma to the periodontal structures.

A traumatic occlusion on a healthy periodontium leads to an increased mobility but not to attachment loss. In inflamed periodontal structures traumatic occlusion contributes to a further and faster spread of the inflammation apically and to more bone loss.

A traumatic occlusion, as in a deep bite, may cause stripping of the gingival margins. It is not clear if prematurities or steep occlusal guidance contribute to the occurrence of gingival recession.

On implants, prematurities may result in breakdown of osseointegration. In some cases occlusal corrections will be necessary to eliminate the traumatic influence of a nonphysiological occlusion.



Key points

- Healthy periodontal structures and occlusal forces
- Physiology and clinical aspects of tooth mobility
- Tooth mobility
- Types of occlusal forces
- Trauma from occlusion:
 - Primary trauma in healthy non-inflamed periodontium
 - Primary trauma in healthy but reduced periodontal structures
 - Secondary trauma in the progression of periodontitis
- Implants and occlusal trauma
- Gingival recession and occlusal trauma
- Clinical consequence and procedures

HEALTHY PERIODONTAL STRUCTURES AND OCCLUSAL FORCES

The healthy periodontal structures, including root cementum, periodontal ligament and alveolar bone, form a functional unit or organ. The periodontal ligament is a very specialised interface between tooth and the alveolar bone. It serves as a structural, sensory and nutritive unit supporting the normal oral functions of chewing, swallowing, speaking, etc. It has a very dense network of interconnecting fibres attached to the bone. The supra-crestal fibres are especially important because they maintain the relative position of the teeth in the arch. The collagen fibres in the periodontal ligament are very dense and represent up to 75% of the volume. These so-called 'Sharpey fibres' are apically oriented and embedded both in the alveolar bone and the root cement. The natural dentition has been compared, because of these interconnecting supra-crestal fibres, to beads on a string. Teeth function together but have their individual mobility in the

alveolus. The entire periodontal ligament has viscoelastic characteristics. The ligament provides tooth fixation, and also force absorption. The thickness of the periodontal ligament is directly related to the forces exerted on it.

The periodontal ligament has a rich and dense vascular and nervous network. The ligament contains proprioceptors for movement and positioning and mechanoreceptors for touch, pain and pressure. They regulate muscle function and occlusal forces to avoid overload and damage of the teeth and the alveolar bone. The periodontal ligament distributes and absorbs forces. Under physiological conditions the occlusal forces are transferred to alveolar bone and further to the mandible, the maxilla and the entire skull. The alveolar process has a pronounced capacity for modelling and remodelling under functional loading. The alveolar process remodels at a rate of 20% per year. The basal bone does not have this capacity. The periodontal ligament and alveolar bone need the functional stimulus of the occlusion to maintain their physiological, healthy condition.

TOOTH MOBILITY

Physiological tooth mobility is the result of the histological characteristics of the periodontal ligament. Physiological tooth mobility, in the horizontal as well as in the vertical direction, is different between single root and multirooted teeth and is determined by the width, height and quality of the periodontal ligament (Fig. 9.1).

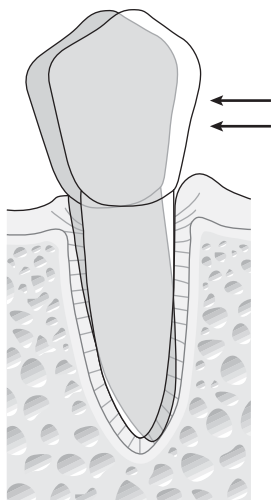


Fig. 9.1 Physiological tooth mobility in a healthy periodontium is determined by the bone height, the form of the root and the magnitude of the applied force, and the extent is limited.

In the vertical direction, the displacement is 0.02 mm by small forces up to 1 N. Under larger vertical forces, the tooth is moved in an apical direction because venous fluid and blood of the periodontal structures is pushed towards the venous lacunae and the cancellous bone. It takes 1–2 minutes before the tooth returns to its normal position after releasing an applied occlusal force. This explains the fact that tooth mobility is decreased after chewing, and the tooth is then in a more apical position.

In healthy conditions, the teeth move in a horizontal plane, under a force of 500 g, as follows (Mühlemann 1960):

- incisors: 0.1–0.12 mm
- canines: 0.05–0.09 mm
- premolars: 0.08–0.1 mm
- molars: 0.04–0.08 mm.

Tooth mobility can also be estimated using the Periotest (Siemens AG, Germany), an electronic device that measures the reaction of the periodontium to a defined percussion force.

Under higher occlusal loads, the forces are transmitted to the bone, with slight deformation of the alveolar process as a result. The force is also transmitted to neighbouring teeth through the interproximal contacts.

Evaluation of tooth mobility

The exact measurement of individual tooth mobility (periodontometry) is necessary for research purposes. Clinically, an estimation of tooth mobility is performed by loading the tooth in an anterolateral direction with two instruments.

Four possible grades of tooth mobility are considered:

- grade 0: physiological mobility
- grade 1: increased mobility but less than 1 mm in total
- grade 2: pronounced increase; more than 1 mm in total
- grade 3: more than 1 mm displacement combined with a displacement in vertical direction (tooth can be intruded).

Increased mobility can also be observed on radiographs: there is a widening of the periodontal space without vertical or angular bone resorption and without increased probing depth of the periodontal pocket (Figs 9.2 and 9.3).

Aetiological factors of hyper- and hypomobility

Excessive occlusal forces or premature contacts on teeth are the primary aetiological factors for hypermobility.

There is an increased mobility during pregnancy because of the increase in the fluid content of the periodontal structures, an increased vascularity and a proliferation of

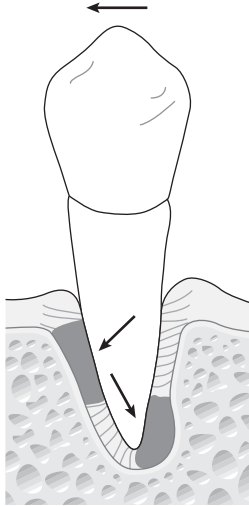


Fig. 9.2 Forces applied in one direction on the tooth give a widening of the periodontal ligament at the bone margin at the other side and in the apical area on the same side of the force.

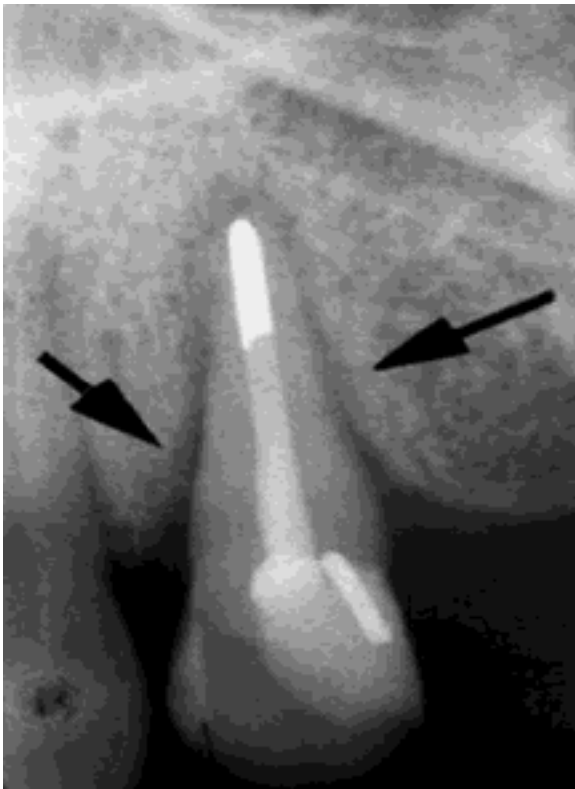

Fig. 9.3 Widening of the periodontal space as observed on radiographs.

capillaries into the periodontal tissues. Systemic diseases such as non-Hodgkin's lymphoma, scleroderma and Cushing's syndrome may lead to increased mobility. Hypermobility may be observed in cases of severe periodontal inflammation (periodontitis), teeth with a healthy but reduced periodontal support (that is, in patients after successful periodontal treatment), or in the first weeks after periodontal surgery.

Normal physiological mobility is decreased in the elderly and in the absence of antagonist teeth. In cases of severe bruxism and clenching the mobility decreases ('ankylosing effect'). Without antagonists and therefore without functional stimulation, teeth will either overerupt or become ankylosed. The periodontal ligament becomes thinner and non-functional.

Evaluation of the changes in occlusal mobility can be helpful in the diagnosis of occlusal dysfunction, parafunction and in the evaluation of occlusal treatment procedures.

TYPES OF OCCLUSAL FORCES

The reaction of the bone and ligament depends on the magnitude, duration and direction of the forces. Different types of occlusal forces can be recognised:

- *Physiologically normal occlusal forces in chewing and swallowing*: small and rarely exceeding 5 N. They provide the positive stimulus to maintaining the periodontium and the alveolar bone in a healthy and functional condition.
- *Impact forces*: mainly high but of short duration. The periodontium can sustain high forces during a short period; however, forces exceeding the viscoelastic buffer capacities of the periodontal ligament will result in fracture of tooth and bone.
- *Continuous forces*: very low forces (for example, orthodontic forces), but continuously applied in one direction are effective in displacing a tooth by remodelling the alveolus.
- *Jiggling forces*: intermittent forces in two different directions (premature contacts on, for example, crowns, fillings) result in widening of the alveolus and in increased mobility.

TRAUMA FROM OCCLUSION

Trauma from occlusion has been defined as structural and functional changes in the periodontal tissues caused by excessive occlusal forces. Some of these changes are adaptive, while others should be considered pathological. Occlusal trauma can be acute if caused by external impact

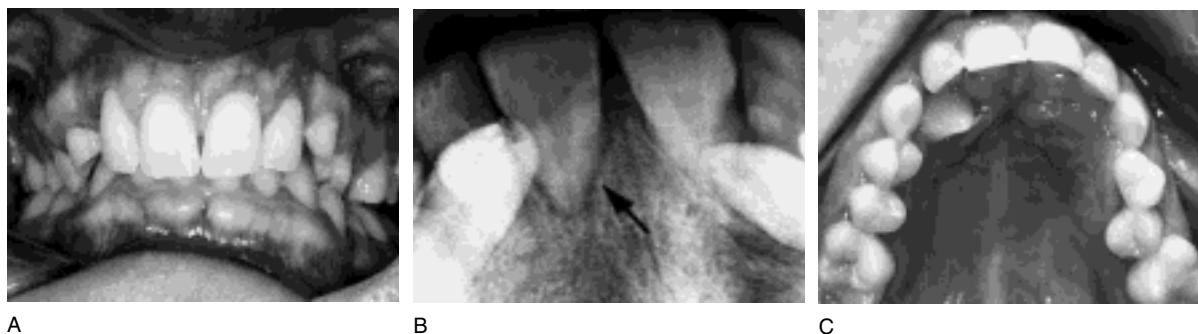

Fig. 9.4 Clinical example of a primary occlusal trauma in a young girl with a deep bite and a persistent deciduous canine. **A** Frontal view showing the deep bite. **B** Palatal view, with the primary trauma on the palatal mucosa caused by the lower canine. When the patient closes, the lower canine is forced in between the upper canine and the central and lateral incisors. **C** This traumatic occlusion causes the widening of the periodontal space, as seen on the radiograph.

forces or chronic if caused by internal occlusal factors (premature contacts, grinding). Chronic occlusal trauma can be understood as primary and secondary trauma.

Occlusal trauma is the overall process by which *traumatic occlusion* (that is, an occlusion that produces forces that cause injury) produces injury to the attachment apparatus.

Primary occlusal trauma

Primary occlusal trauma is caused by excessive and non-physiological forces exerted on teeth with a normal, healthy and non-inflamed periodontium. The forces may be exerted on the periodontal structures in one direction (orthodontic forces) or as ‘jiggling’ forces.

Forces in one direction: orthodontic forces

Forces in one direction cause tipping of the tooth in the opposite direction or tooth displacement parallel to the force resulting in a ‘bodily movement’.

In the periodontal ligament, zones of compression and zones of tension are found, inducing increased resorption. The clinical result is a (temporary) increased mobility. However, there are no changes in the supracrestal fibres, no loss of periodontal attachment, or an increased probing pocket depth. The increased tooth mobility is functional adaptation to the forces exerted on that tooth. If the forces are too high and above the adaptation level, an aseptic necrosis in the tension zone of the periodontal ligament occurs, characterised by hyalinisation. In the compression zone, pressure stimulates osteoclasts in the adjacent bone and the alveolar wall is resorbed until a new connection is formed with the hyalinised bone (‘undermining resorption’). In the tension zone, bone apposition and rupture of the collagen fibres occur. After removal of the force the periodontal ligament is reorganised and after some time

develops a normal histological appearance. If the applied forces are too high, root resorption occurs in the middle of the hyalinised tissues. This resorption continues for a variable time, resulting in shorter roots, frequently seen after orthodontic treatment.

Jiggling forces

Jiggling forces, coming from different and opposite directions, cause more complex histological changes in the ligament. Theoretically the same events (hyalinisation, resorption) occur, however, they are not clearly separated.

There are no distinct zones of pressure and tension. Histologically, there is apposition and resorption on either side of the periodontal ligament, resulting in a widening of the periodontal space (Fig. 9.4). This may be observed on radiographs. This phenomenon explains the increased mobility without pocket formation, migration and tipping.

The clinical phenomena are not only dependent on the magnitude of the forces, but also on the crown–root relationship, the position in the arch, the direction of the long axis, and the pressure of tongue and cheek musculature (Fig. 9.5). The interarch relationship (for example, deep bite) influences the extent of the trauma caused by jiggling forces. The hypermobility is found as long as the forces are exerted on the tooth: there is no adaptation. Hypermobility is therefore not a sign of an ongoing process, but may be the result of a previous jiggling force.

The long-term prognosis of teeth with increased mobility is poor, and is a complicating factor if they are used as abutment in prosthodontic reconstruction.

Successful periodontal treatment leads to healthy but reduced periodontal structures. Jiggling forces exerted on the teeth in this condition result in a pronounced increase in tooth mobility because the point of rotation (fulcrum) is closer to the apex than normal. This is uncomfortable for

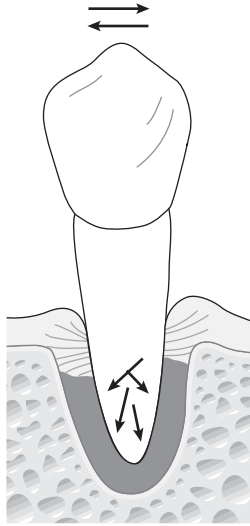


Fig. 9.5 Under jiggling forces in a healthy periodontium, the periodontal ligament space is widened, resulting in more tooth mobility but not in marginal bone resorption or attachment loss.

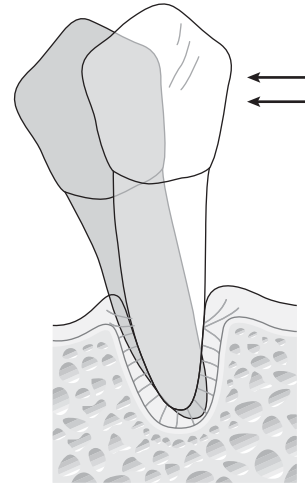


Fig. 9.6 In cases of a healthy but reduced periodontium the tooth mobility (measured at the crown level) is increased for the same force, as compared with a tooth with a complete periodontium, because of the more apical position of the fulcrum.

the patient and might be an indication for splinting of teeth (Fig. 9.6).

Secondary occlusal trauma

Secondary trauma from occlusion is defined as the trauma caused by excessive and premature occlusal forces on teeth with an inflamed periodontium. A number of animal experiments and clinical epidemiological studies investigated the role of occlusion in the pathogenesis of periodontitis. In his original studies in the 1960s, Glickman (Glickman & Smulow 1967) formulated the hypothesis that premature contacts and excessive occlusal forces could be a co-factor in the progression of periodontal disease by changing the pathway and spread of inflammation into the deeper periodontal tissues. Glickman hypothesised that the gingival zone was a 'zone for irritation' by the microbial plaque; the supracrestal fibres were then considered to be a 'zone of co-destruction' under the influence of a faulty occlusion (Fig. 9.7).

Clinically, vertical bone resorption and the formation of infrabony defects should be an indication for occlusal trauma.

Animal experiments

Animal experiments investigating the influence of a faulty occlusion on the progression of periodontal disease were published by Swedish investigators between 1970

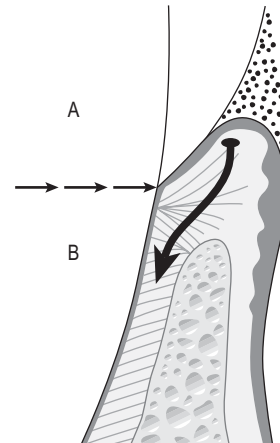


Fig. 9.7 Role of traumatic occlusion in the progression of periodontitis according to Glickman & Smulow (1967). In the presence of microbial plaque and inflammation, **A** is the 'zone of irritation' and **B** the 'zone of co-destruction' where the prematurities are co-destructive by changing the inflammatory pathway.

and 1980 using the beagle dog model, and by American investigators using the squirrel monkey model. In spite of the many remaining questions and controversies, few animal studies have been published since then.

From these studies the following conclusions may be drawn:

- In the absence of marginal inflammation, jiggling forces do not induce more bone resorption nor a shift of the epithelial attachment in an apical direction.
- In the case of marginal inflammation (gingivitis), occlusal overload has no influence.
- Jiggling forces on teeth with periodontal disease result in more bone loss and more loss of connective tissue attachment (Ericsson & Lindhe 1982).
- Jiggling forces induce a faster shift of microbial plaque in the apical direction in the pocket (Fig. 9.8).
- One single trauma does not influence the pathogenesis; the forces have to be chronic.
- Treatment of periodontal inflammation without elimination of the premature contacts results in decreased tooth mobility, an increase in bone density, but no change of bone level.
- After periodontal treatment with scaling and root-planing, the presence or absence of prematurities have no influence on the microbial repopulation of the deepened pockets.

It must be mentioned that some animal studies did not reach the same definitive conclusions, due to differences in experimental setup and different animal models. The results of experimental animal studies cannot therefore be directly extrapolated to the human situation.

Clinical epidemiological studies

Given the complexity of the occlusal and periodontal interaction and the multifactorial aspect of the pathology, very few human studies have been published. Most studies have a limited number of subjects and the results are analysed on a subject basis rather than on a tooth basis. The studies have been recently summarised by Hallmon (Hallmon 1999). A number of cross-sectional epidemiological studies found either no relationship between the presence of premature contacts and increased probing depth or bone loss, while others reported that mobility and radiographic evidence of a widened periodontal ligament were associated with increased pocket depth, attachment loss and bone loss (Jin & Cao 1992). More recent longitudinal studies (Harrel & Nunn 2001) found that teeth with premature contacts at initial examination had a deeper probing pocket depth, an increased mobility and a worse prognosis. At the 1 year examination, teeth without premature contacts originally, or teeth where premature contacts had been removed, showed a 66% reduced chance of a worsening periodontal situation. After a few months, teeth with prematurities showed an increased probing depth compared with the teeth receiving occlusal adjustment. It was concluded that premature contacts are a 'catalyst' in the progression of periodontal disease.

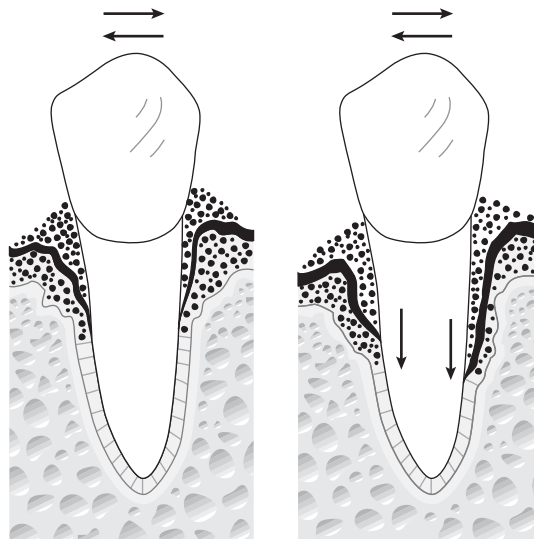


Fig. 9.8 In applying jiggling forces on an inflamed, untreated periodontium with existing infrabony pockets (A), the bone destruction is accelerated and the bacteria move more apically (B).

It has also been shown that in the same patient more periodontopathogens are found in pockets around hypermobile teeth, than in teeth with normal mobility. This can lead to the hypothesis that the increased mobility changes the ecosystem in the pocket, favouring growth of these bacteria.

TRAUMA FROM OCCLUSION AND IMPLANTS

Endosseous implants have no periodontal ligament as an intimate implant–alveolar bone contact exists ('functional ankylosis'). Implant failure can occur not only because of bacterial infection (peri-implantitis) but also because of occlusal overload (biomechanical failure) in combination with immunological host factors (Esposito et al 1998).

Occlusal overload results in 'osseodisintegration' over the complete implant surface without clinically detectable pocket formation or signs of inflammation. Often the implant has no increased mobility in spite of pronounced bone resorption along its entire surface. Clinical measurement of implant mobility is not an accurate tool for evaluating osseointegration or disintegration of an implant until late in the pathological process. If increased implant mobility occurs, osseointegration is by then usually destroyed.

GINGIVAL TRAUMA FROM OCCLUSION

Gingival recession may be provoked by direct contact of the teeth with the gingiva, as in severe overbite, where the upper incisors damage the buccal gingiva of the lower incisors. This problem is not easy to solve and may involve orthodontic treatment, orthognathic surgery or extensive prosthetic rehabilitation requiring an increase in vertical dimension.

It has been stated that gingival recession occurs with functional overload and/or premature contacts, as in the buccal surface of upper canines where there is a steep lateral canine guidance. Those cervical surfaces also show enamel abfraction. There is still controversy regarding whether or not overload is an aetiological factor in the recession, and consequently whether or not the occlusion and the lateral guidance should be changed.

PRACTICAL CLINICAL CONCLUSIONS AND GUIDELINES

- In a healthy non-inflamed dentition, traumatic occlusion leads to hypermobility of some teeth; if hypermobility, radiological widening of periodontal ligament space or pronounced cervical abfraction is found, the occlusion should be analysed and corrected. Simple uncomplicated, non-time-consuming procedures are in most cases adequate to restore a physiological situation and to reduce hypermobility.

- In cases of a healthy but reduced periodontium, increased mobility may also be reduced by occlusal adjustment; it should be recognised that tooth mobility in such cases, based on the mechanical situation, is nevertheless increased. It may be necessary to splint the teeth to increase the functional comfort and to avoid direct fracture. This may include very mobile teeth with a healthy but reduced periodontium, but complicates the clinical procedures.

- In cases of secondary occlusal trauma, treating the inflammation is of primary importance and should be the first step in treatment planning. From the literature it can be concluded that prematurities may play a role in the progression of the periodontitis.

- A simple correction of the occlusion, if necessary, should be included in the initial phase of periodontal treatment. This results in more gain in attachment level during periodontal treatment, and may contribute to better healing of periodontal tissues.

- There are some indications that removing premature tooth contacts improves the prognosis of periodontally involved tissues.

- If some teeth do not react to conventional periodontal treatment as expected, further investigation should not only include periodontal re-examination and microbiological testing, but also more extensive occlusal analysis.

- As implant overload leads to bone resorption without the warning signal of inflammation, deep peri-implantitis pockets or (in the early stage) increased mobility, evaluation of the occlusion and radiographs should be included in regular maintenance programmes.



References

- Ericsson I, Lindhe J 1982 The effect of long standing jiggling on the experimental marginal periodontitis in the beagle dog. *Journal of Clinical Periodontology* 9:495
- Esposito M, Hirsch J M, Lekholm U, Thomsen P 1998 Biological factors contributing to failures of osseointegrated implants. II. Etiopathogenesis. *European Journal of Oral Sciences* 106:721–764
- Glickman I, Smulow I B 1967 Further observation on the effects of trauma from occlusion. *Journal of Periodontology* 38:280
- Hallmon W 1999 Occlusal trauma: effect and impact on the periodontium. *Annals of Periodontology* 4:102
- Harrel S K, Nunn M E 2001 The effect of occlusal discrepancies upon periodontitis. II. Relationships of occlusal treatment to the progression of periodontal disease. *Journal of Periodontology* 72:495–505
- Jin L, Cao C 1992 Clinical diagnosis of trauma from occlusion and its relation with severity of periodontitis. *Journal of Clinical Periodontology* 19:92–97
- Mühlemann H R 1960 Ten years of tooth mobility measurements. *Journal of Periodontology* 31:110–122



Further reading

- Beertsen W, McCulloch C A G, Sodek J 1997 The periodontal ligament: a unique, multifunctional connective tissue. *Periodontology* 2000 13:20–40
- Burgett F G, Ramfjord S P, Nissle R R et al 1992 A randomized trial of occlusal adjustment in the treatment of periodontitis. *Journal of Clinical Periodontology* 19:381–387
- Gher M 1996 Non surgical pocket therapy: dental occlusion. *Annals of Periodontology* 1:567–580
- Giargia M, Lindhe J 1997 Tooth mobility and periodontal disease. *Journal of Clinical Periodontology* 24:785–791
- Grant D A, Flynn M J, Slots J 1995 Periodontal microbiota of mobile and non-mobile teeth. *Journal of Periodontology* 66:386–390
- Kaufman H, Carranza F A, Enders B, Neuman M G, Murphy N 1984 Influence of trauma from occlusion on the bacterial re-population of periodontal pockets in dogs. *Journal of Periodontology* 55:86–92
- McCulloch C A G, Kekic P, McKee M D 2000 Role of physical forces in regulating the form and function of the periodontal ligament. *Periodontology* 24:56–72
- Polson A M II 1974 Co-destructive factors of periodontitis and mechanically produced injury. *Journal of Periodontal Research* 9:108–113
- Schulte W, Hoedt B, Lukas D, Maune M, Steppeler M 1992 Periotest for measuring periodontal characteristics. Correlation with periodontal bone loss. *Journal of Periodontal Research* 27:181–190
- Wang H, Burgett F G, Shyt Y, Ramfjord S 1994 The influence of molar furcation involvement and mobility on future clinical periodontal attachment loss. *Journal of Periodontology* 65:25–29

